

# MUSCULAR SYSTEM

By Binalfew Tsehay

# Introduction

- There are more than 600 muscles in the human body. Most of these muscles are attached to the bones of the skeleton by tendons, although a few muscles are attached to the undersurface of the skin.
- The primary function of the **muscular system** is to move the skeleton.
- It can also:
  - ▣ Maintaining posture
  - ▣ Stabilizing joints
  - ▣ Generating heat

# Actions of muscles

- A muscle may work in the following four ways:
- **Prime mover:** is the chief muscle or member of a chief group of muscles responsible for a particular movement.
- **Antagonist:** Any muscle that opposes the action of the prime mover is an antagonist.
- **Fixator:** stabilize the origin of the prime mover so that it can act efficiently.
- **Synergist:** Contract and stabilize the intermediate joints to prevent unwanted movements.

# Cont.

- Muscles can even contract paradoxically, for example, when the biceps brachii, a flexor of the elbow joint, contracts and controls the rate of extension of the elbow when the triceps brachii contracts.



# Nerve Supply of Skeletal Muscle

- The nerve trunk to a muscle is a mixed nerve, about 60% is motor and 40% is sensory, and it also contains some sympathetic autonomic fibers.
- The nerve enters the muscle at about the midpoint on its deep surface, often near the margin; the place of entrance is known as the motor point.
- This arrangement allows the muscle to move with minimum interference with the nerve trunk.

# Naming of Skeletal Muscles

- **Individual muscles are named according to their**
  - **shape,**
  - **size,**
  - **number of heads or bellies,**
  - **position,**
  - **depth,**
  - **attachments, or**
  - **actions.**

# Muscle Attachments

- The importance of knowing the main attachments of all the major muscles of the body need not be emphasized.
- Only with such knowledge is it possible to understand the normal and abnormal actions of individual muscles or muscle groups.
- How can one even attempt to analyze, for example, the abnormal gait of a patient without this information?

# Muscle Shape and Form

- The general shape and form of muscles should also be noted, since a paralyzed muscle or one that is not used (such as occurs when a limb is immobilized in a cast) quickly atrophies and changes shape.
- In the case of the limbs, it is always worth remembering that a muscle on the opposite side of the body can be used for comparison.

# Smooth Muscle

- Smooth muscle consists of long, spindle-shaped cells closely arranged in bundles or sheets.
- In the tubes of the body, it provides the motive power for propelling the contents through the lumen.
- In storage organs such as the urinary bladder and the uterus, the fibers are irregularly arranged and interlaced with one another.
- Their contraction is slow and sustained and brings about expulsion of the contents of the organs.
- In the walls of the blood vessels, the smooth muscle fibers are arranged circularly and serve to modify the caliber of the lumen.

# Cont.

- Depending on the organ, smooth muscle fibers may be made to contract by:
  - ▣ local stretching of the fibers,
  - ▣ nerve impulses from autonomic nerves, or
  - ▣ hormonal stimulation.

# Cardiac Muscle

- Cardiac muscle consists of striated muscle fibers that branch and unite with each other.
- It forms the myocardium of the heart.
- Its fibers tend to be arranged in whorls and spirals, and they have the property of **spontaneous and rhythmic contraction.**
- Specialized cardiac muscle fibers form the **conducting system of the heart.**

# Cont.

- Cardiac muscle is supplied by autonomic nerve fibers that terminate in the nodes of the conducting system and in the myocardium.



# Muscles of the Axial Skeleton

- **Muscles of the axial skeleton include those responsible for**
  - **facial expression,**
  - **mastication,**
  - **eye movement,**
  - **tongue movement,**
  - **neck movement, and respiration,**
- **And those of the abdominal wall, the pelvic outlet, and the vertebral column.**

# Muscles of Face and Scalp

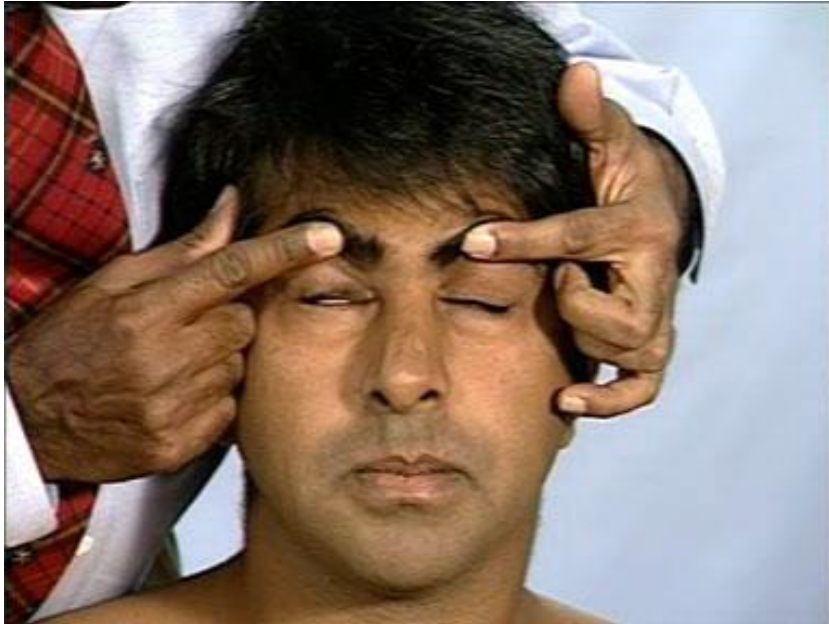- The skin of the face possesses **numerous sweat and sebaceous glands.**
- It is connected to the underlying bones by **loose connective tissue,** in which are embedded the muscles of facial expression.
- *No deep fascia is present in the face.*



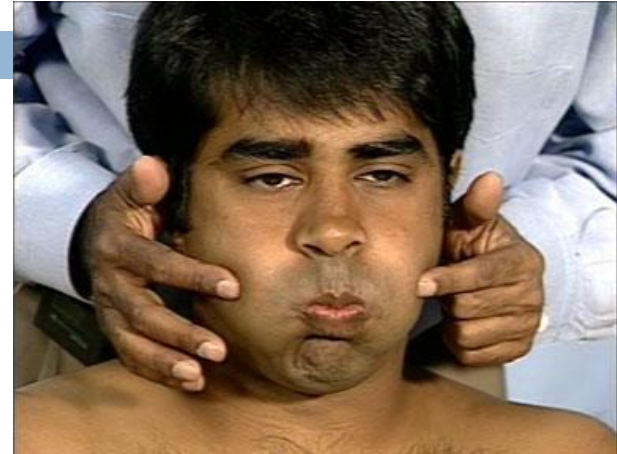# Cont.

- The muscles of the face are **embedded in the superficial fascia**, and most arise from the bones of the skull and are inserted into the skin.
- The openings in the face, namely, the orbit, nose, and mouth, **are guarded** by the eyelids, nostrils, and lips, respectively.
- The facial muscles serve
  - ▣ As **sphincters** or **dilators** of these structures.
  - ▣ As to **modify the expression of the face**

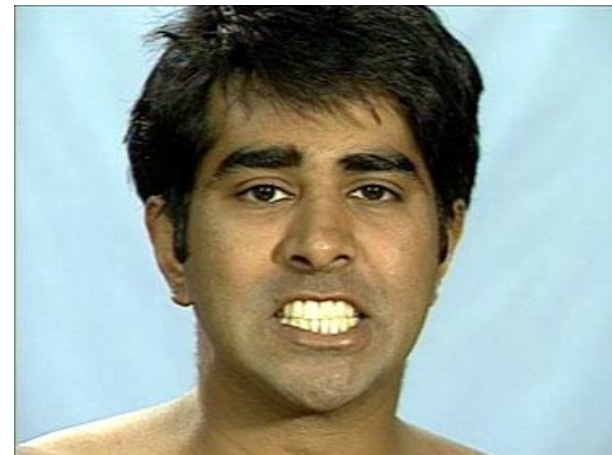
# Cont.



- The orifices of the face, namely, the orbit, nose, and mouth, **are guarded** by the eyelids, nostrils, and lips, respectively.

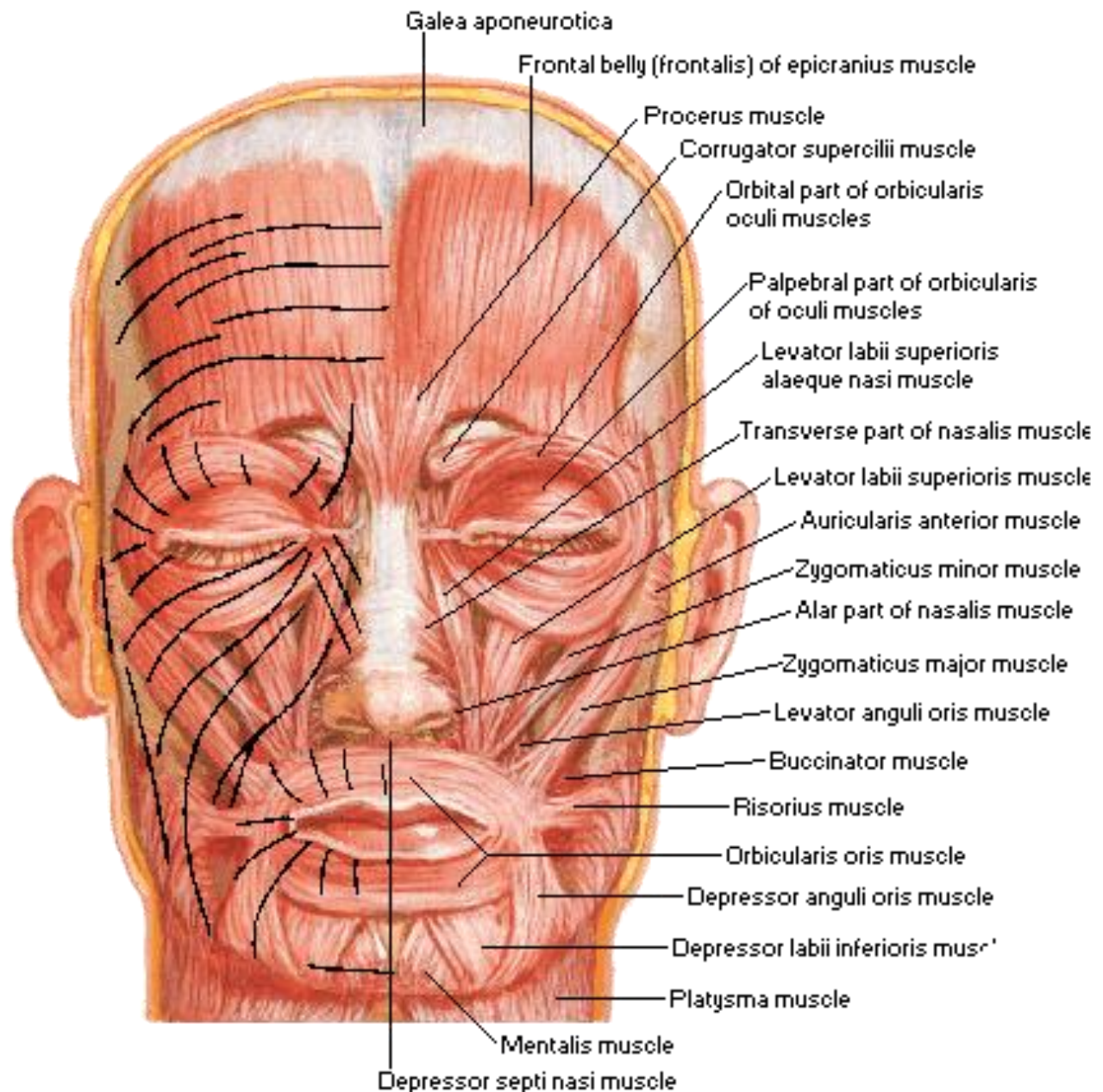


- The facial muscles serve as **sphincters**
- or **dilators** of these structures.



# Muscles of Facial Expression

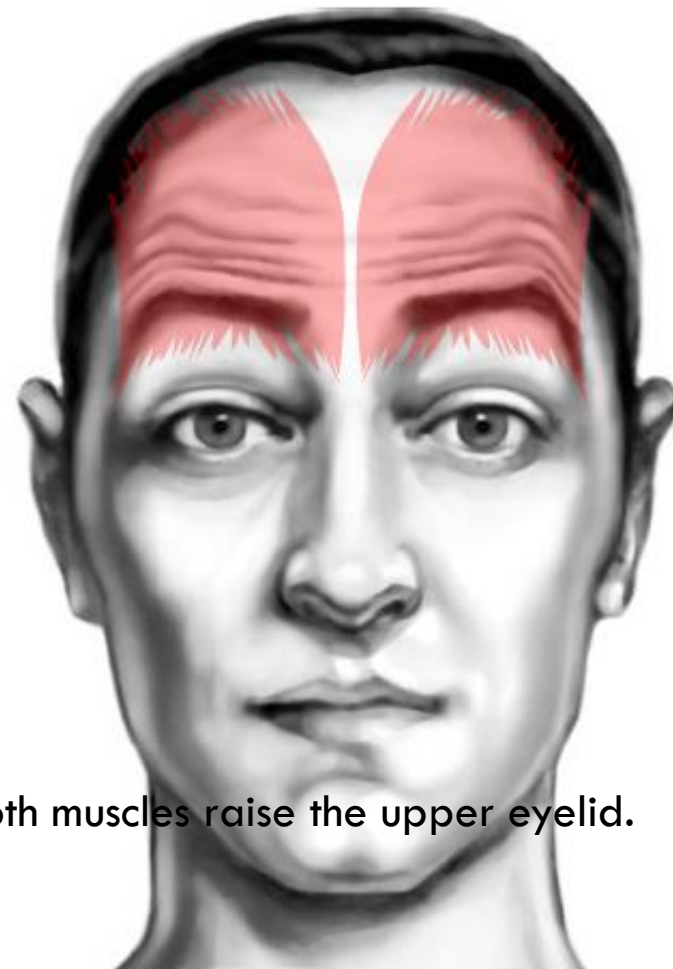
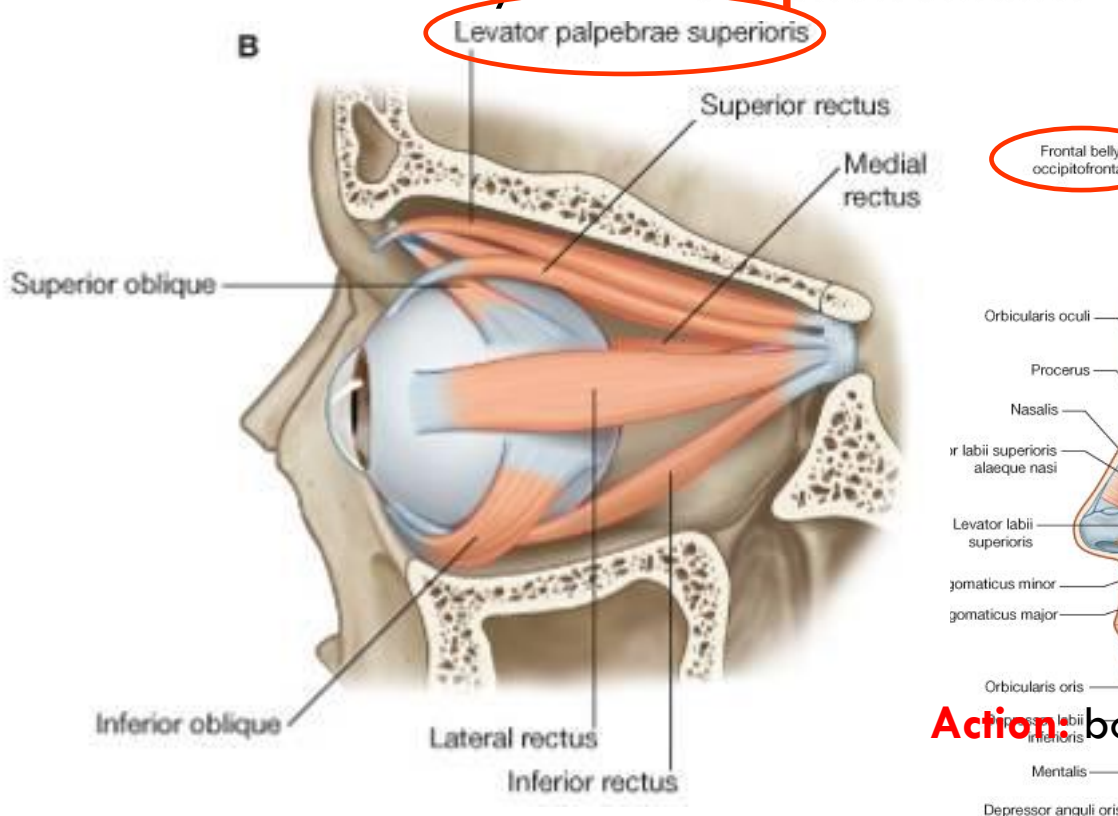
## Anterior View



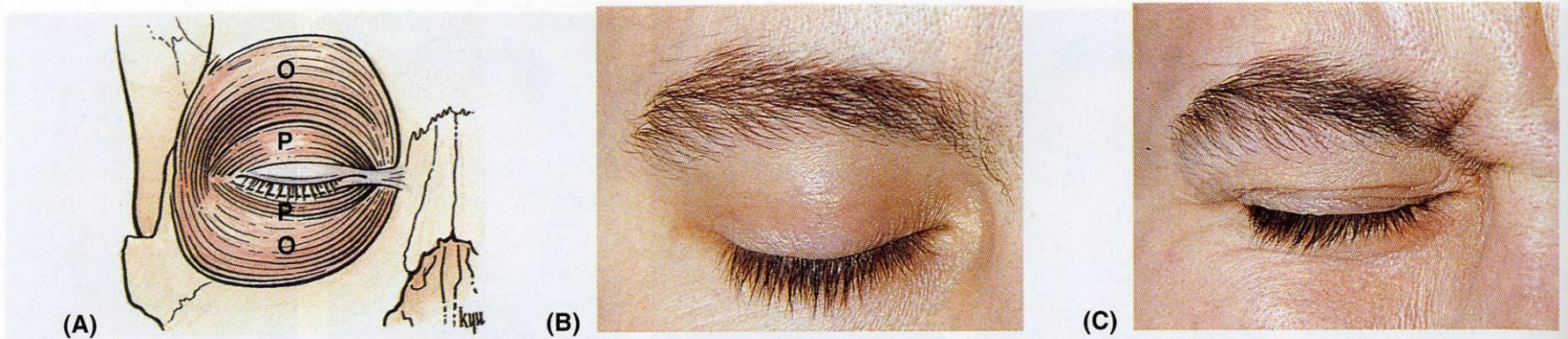


# Muscles Of The Eyelids

- The dilator muscles are:
  - The **levator palpebrae superioris** and
  - The frontal belly of the **occipitofrontalis**.



# Sphincter Of The Eyelids: Orbicularis Oculi



**Figure 7.23. Disposition and actions of orbicularis oculi muscle.** A. The orbital (O) and palpebral (P) parts of the orbicularis oculi are demonstrated. B. The palpebral part gently closes the eyelids. C. The orbital part tightly closes the eyelids.

## □ **Palpebral part:**

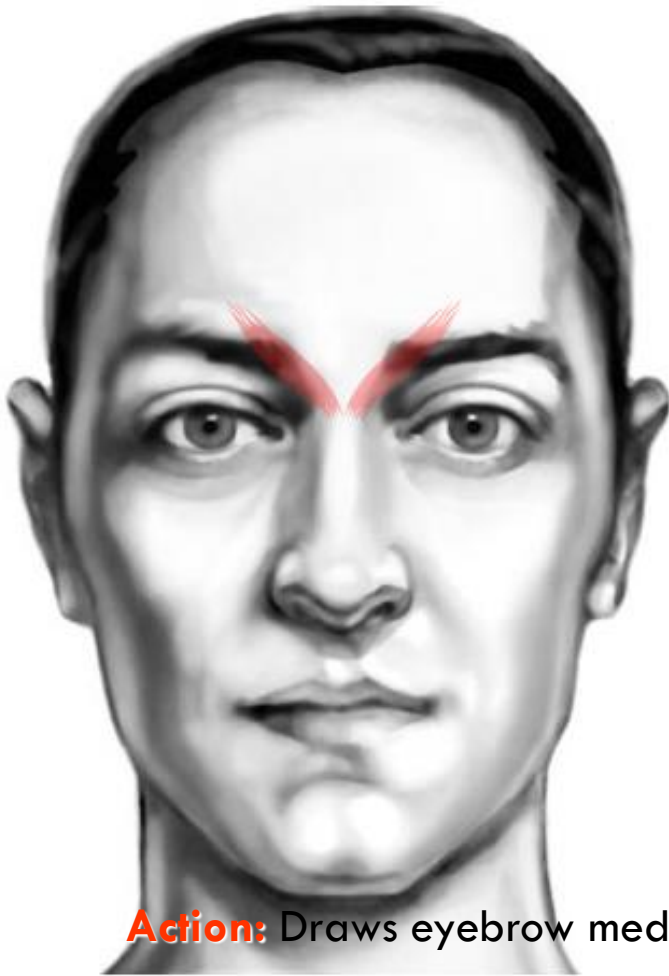
- **Origin:** medial palpebral ligament
- **Insertion:** lateral palpebral raphe
- **Innervation:** facial nerve
- **Function:** closes eyelids and dilates lacrimal sac

## □ **Orbital part:**

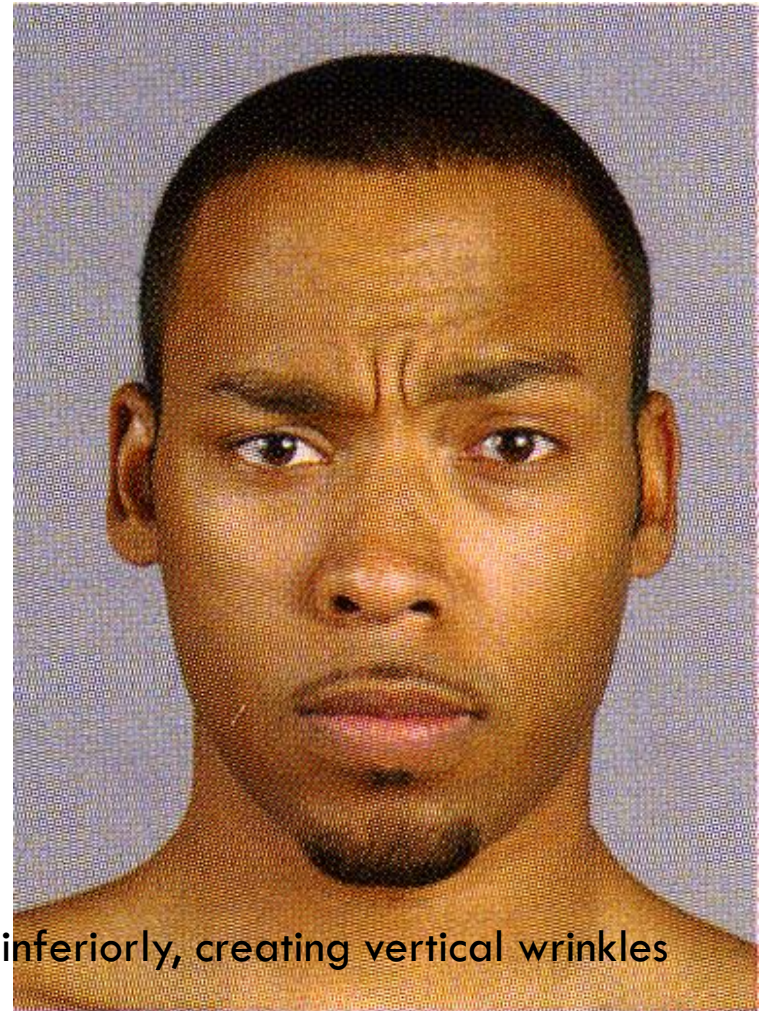
- **Origin:** medial palpebral ligament and adjoining bone
- **Insertion:** loops return to origin
- **Innervation:** facial nerve
- **Function:** throws skin around orbit into folds to protect eyeball



# Corrugator Supercilii

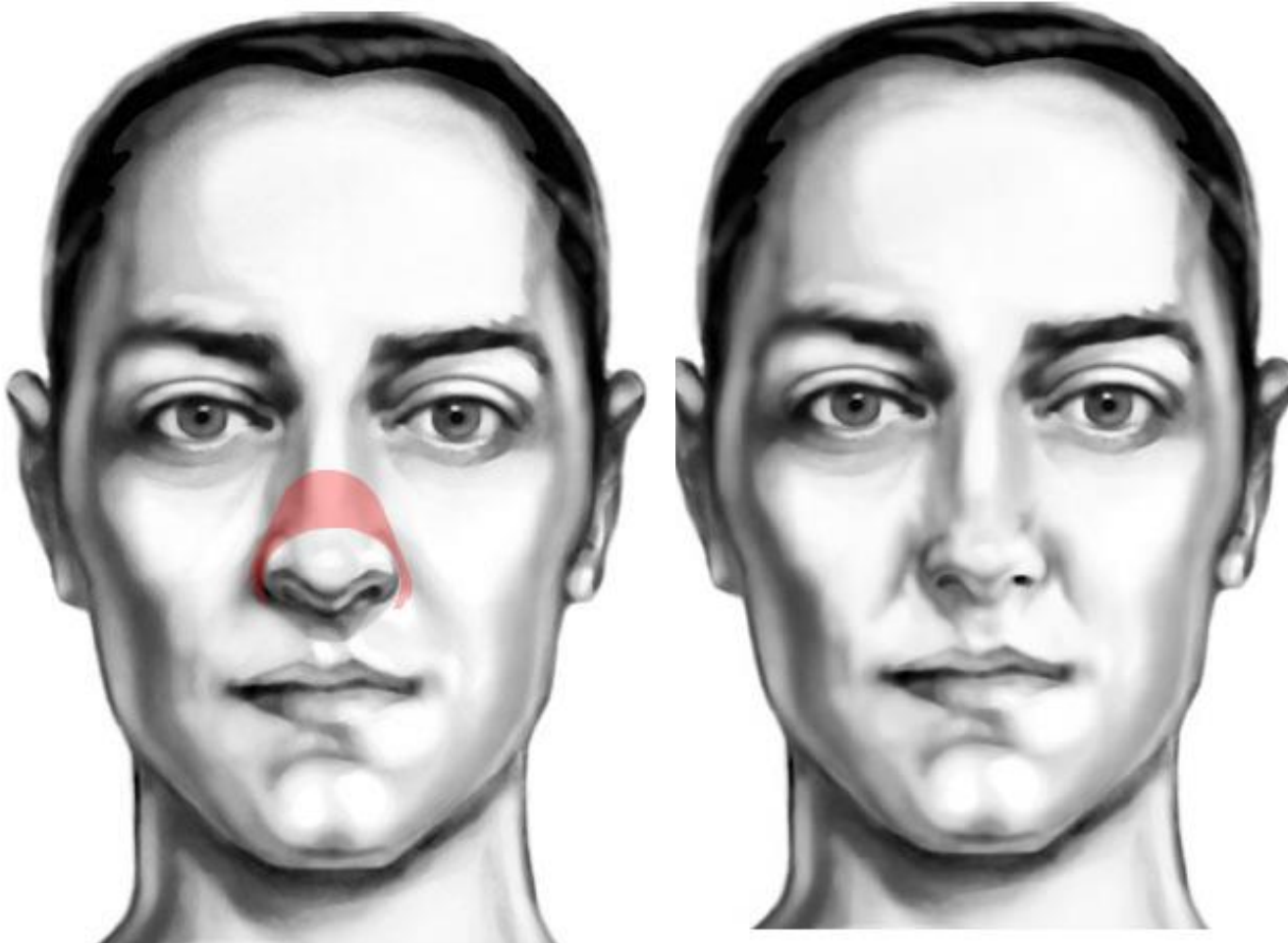


**Action:** Draws eyebrow medially and inferiorly, creating vertical wrinkles above nose





# Muscles of the Nostrils

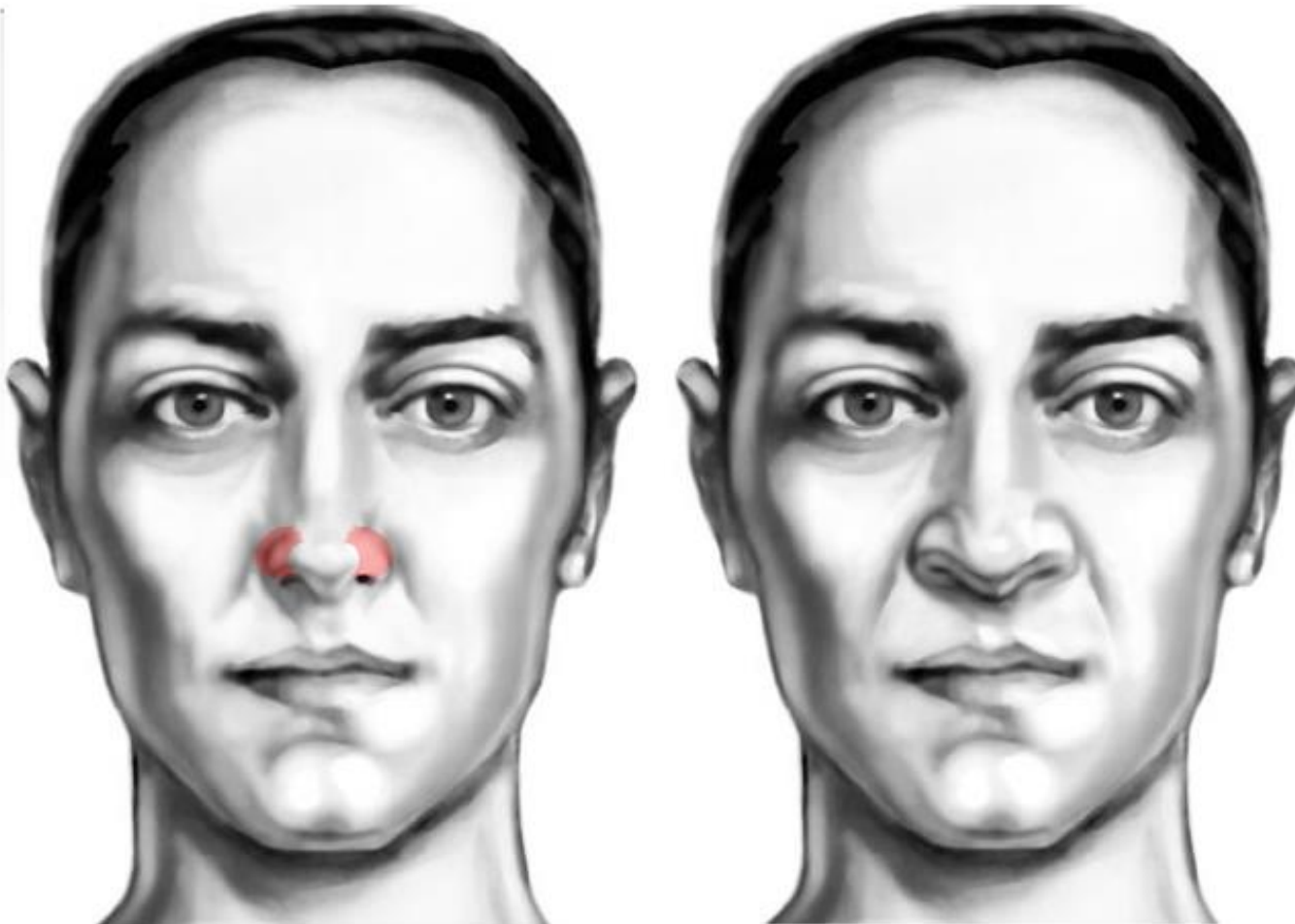


Depressor septi

The sphincter muscle is the **compressor naris**.

- ▣ **Origin:** frontal process of maxilla
- ▣ **Insertion:** aponeurosis of bridge of nose
- ▣ **Innervation:** facial nerve
- ▣ **Action:** compresses the mobile nasal cartilages.

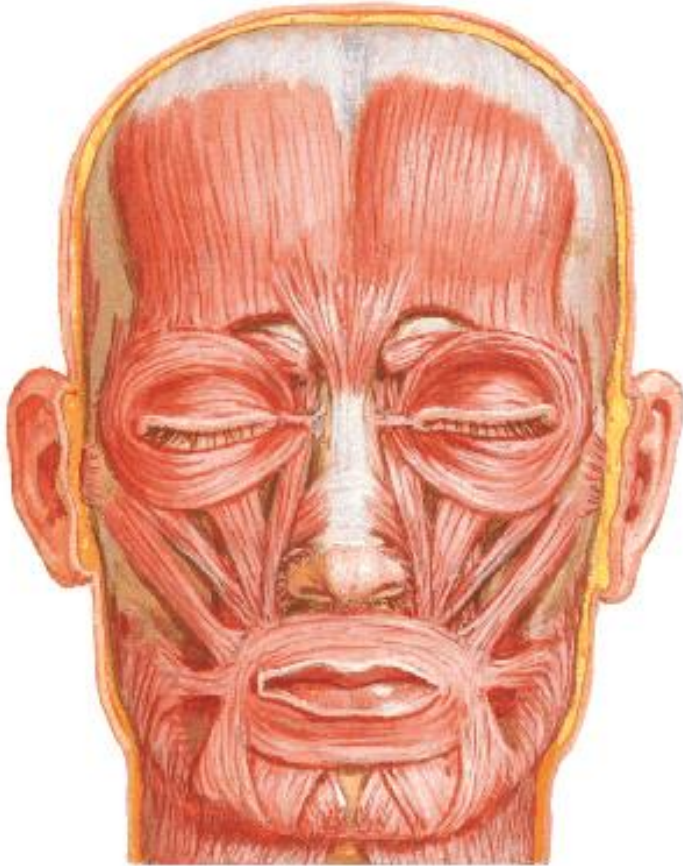
# Cont.



Depressor septi

muscle is the  
lateral  
part of nose  
innervated by  
facial nerve  
branch is nasal

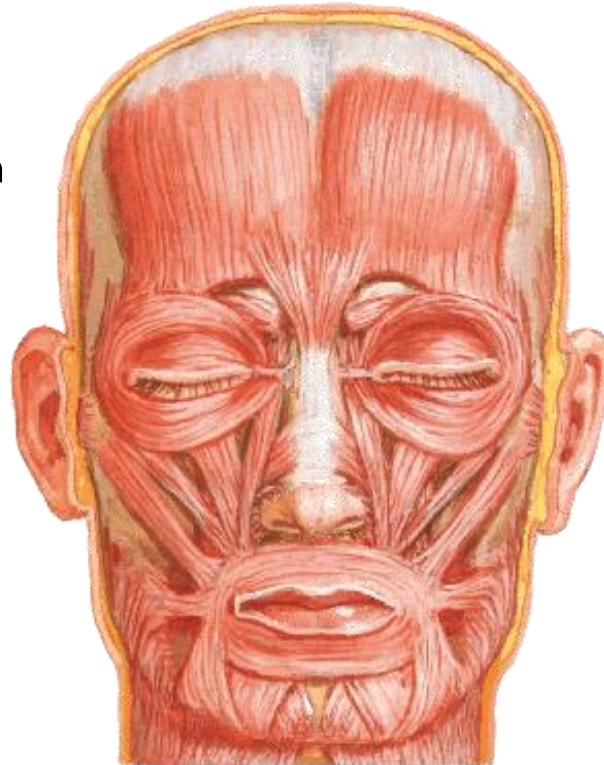
# Muscles of the Lips and Cheeks

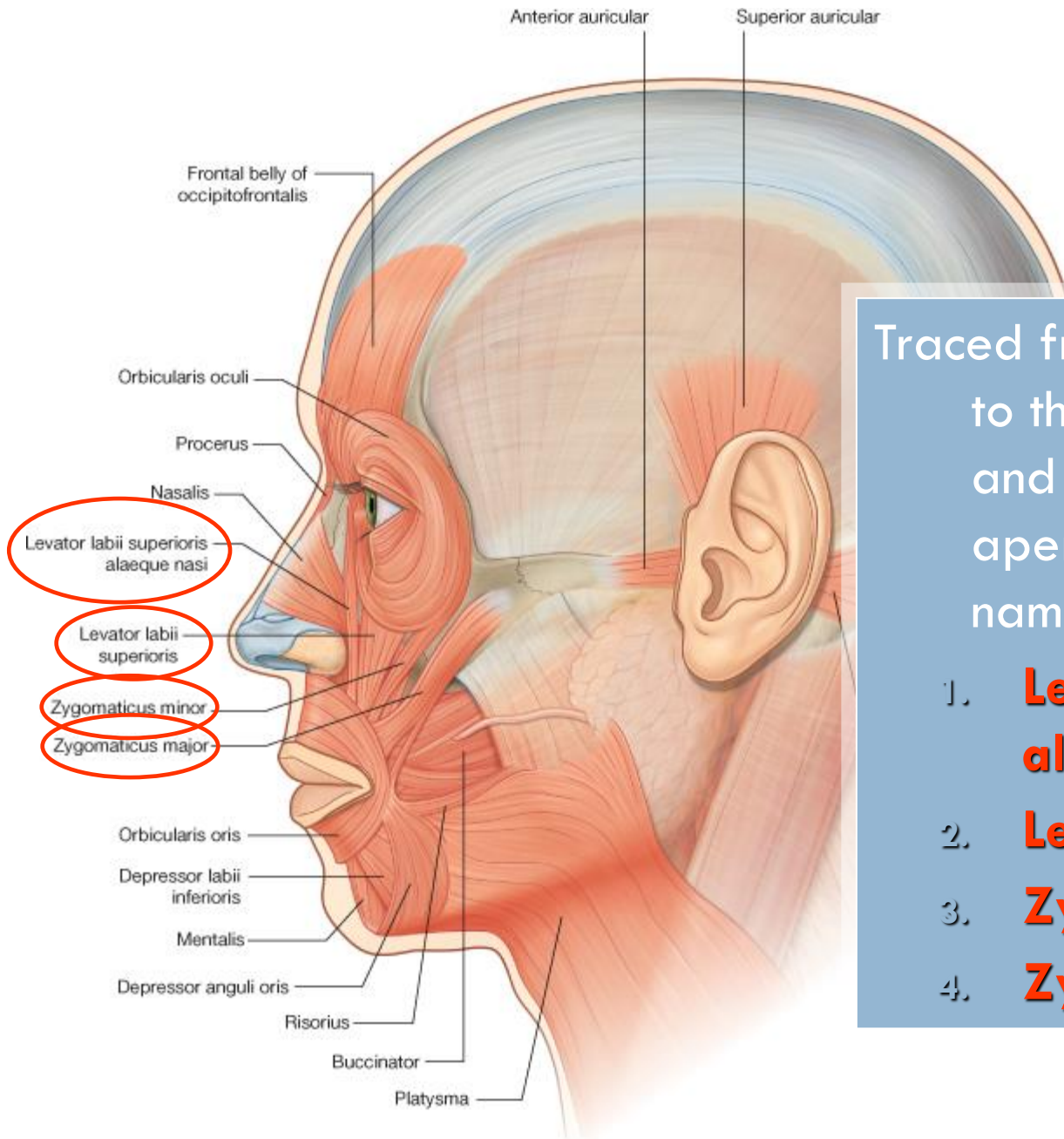


- The **sphincter** muscle is the orbicularis oris.
- The **dilator** muscles consist of a series of small muscles that radiate out from the lips.

# DILATOR MUSCLES OF THE LIPS

- The **dilator muscles** radiate out from the lips.
- The muscles **arise** from the bones and fascia around the oral aperture and **converge** to be inserted into the substance of the lips.
- Their action is to separate the lips; this movement is usually accompanied by separation of the jaws.

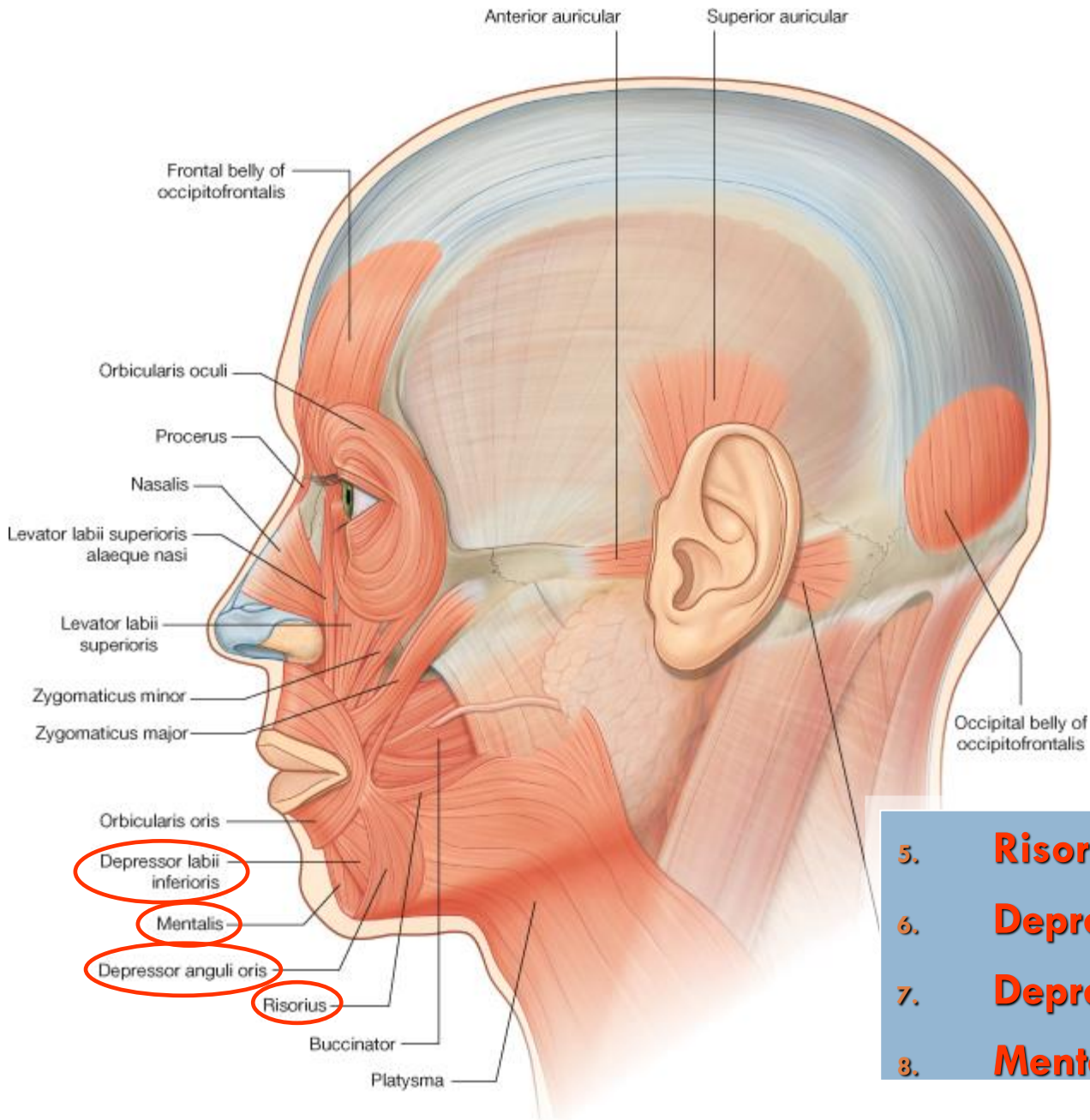




Traced from the side of the nose to the angle of the mouth and then below the oral aperture, the muscles are named as follows:

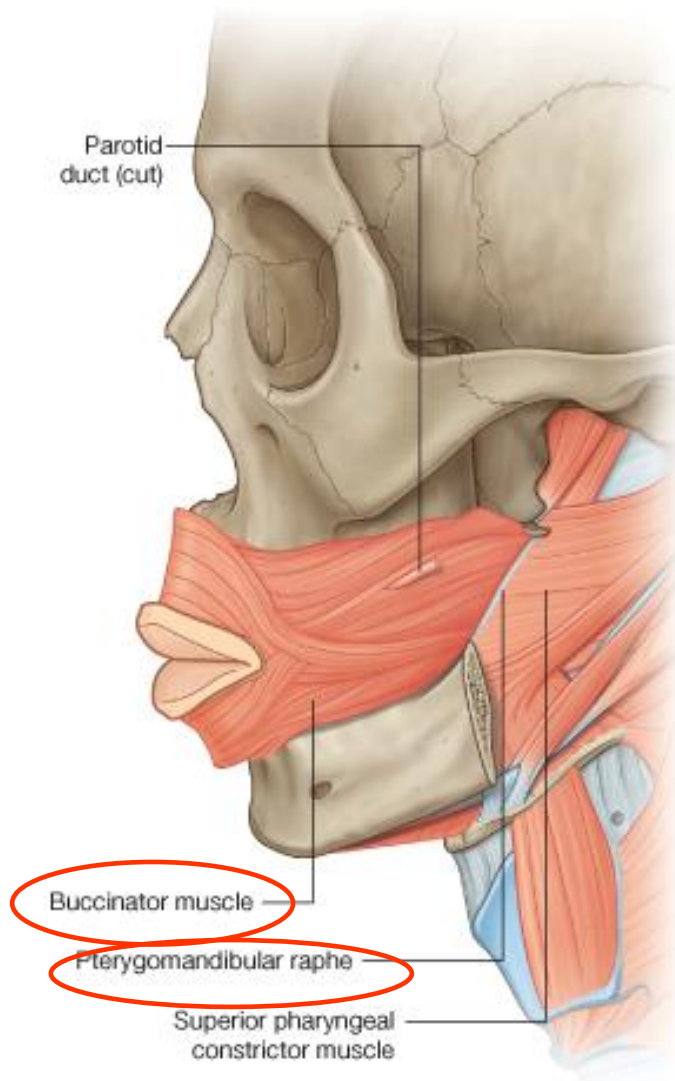
1. **Levator labii superioris alaeque nasi**
2. **Levator labii superioris**
3. **Zygomaticus minor**
4. **Zygomaticus major**





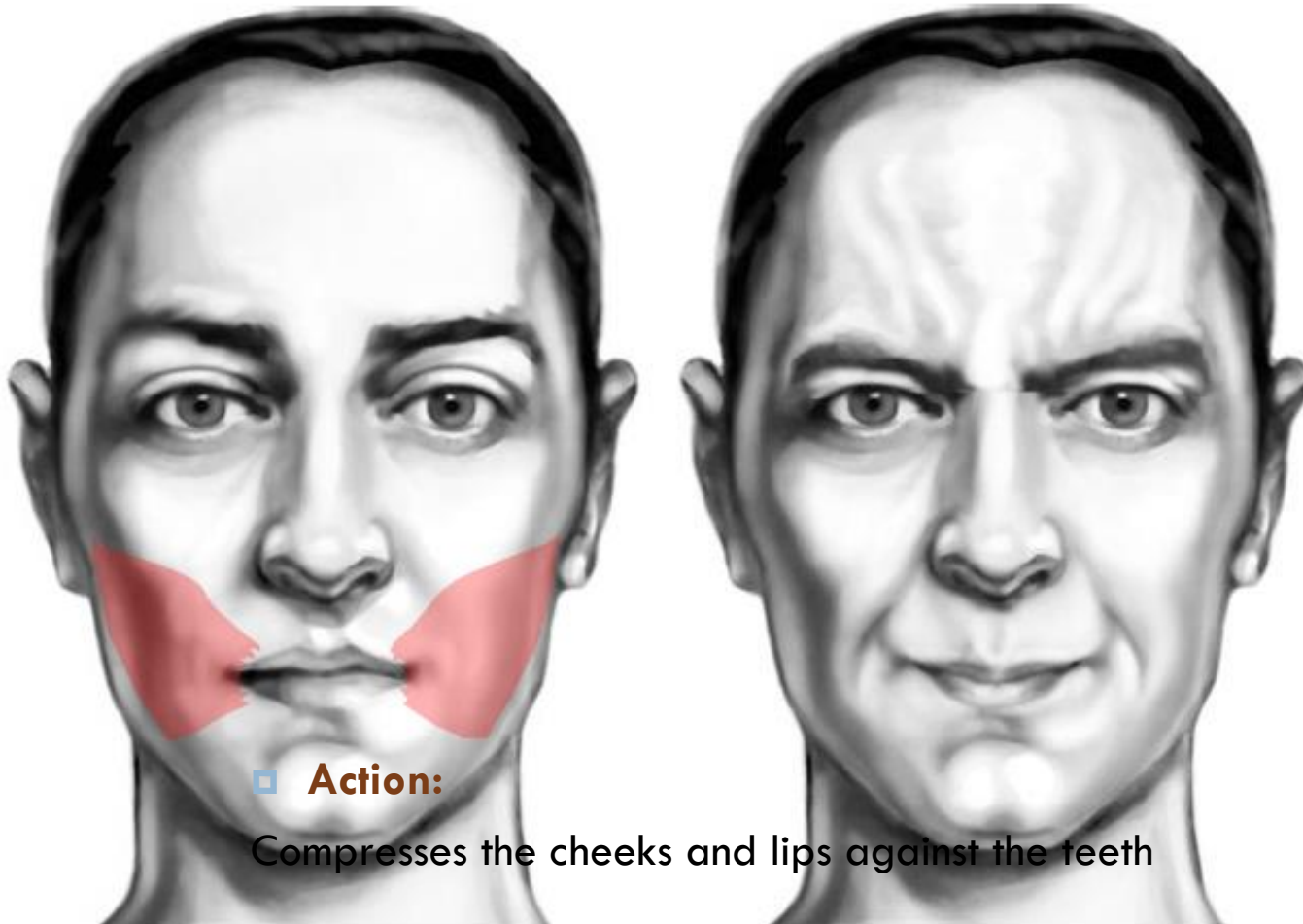
5. **Risorius**
6. **Depressor anguli oris**
7. **Depressor labii inferioris**
8. **Mentalis**

# Muscle of the Cheek



- **Buccinator**
  - **Origin:** From the outer surface of the alveolar margins of the maxilla and mandible opposite the molar teeth and from the pterygomandibular ligament.
  - **Insertion:**
  - The muscle fibers pass forward, forming the muscle layer of the cheek.
  - The muscle is pierced by the **parotid duct**.
  - At the angle of the mouth the central fibers **decussate**, those from below entering the upper lip and those from above entering the lower lip.
  - The highest and lowest fibers continue into the upper and lower lips, respectively, without intersecting.
  - The buccinator muscle thus blends and forms part of the orbicularis oris muscle.
  - **Action:**
    - Compresses the cheeks and lips against the teeth

# Cont.





# Muscles of Nose and Ears

- although muscles of nose are functionally important in certain mammals (elephants, tapirs, rabbits, and some diving mammals), they are relatively unimportant in humans, except in terms of **facial expression and in the specialized field of aesthetic plastic surgery.**
- The muscles of the ears, important in animals capable of cocking or directing the ears toward the sources of sounds, are even less critical in humans.

# "REJECTION"



List the muscles of facial expression which are activated.

1. ....
2. ....
3. ....
4. ....
5. ....

# "SURPRISE"



List the muscles of facial expression which are activated.

1. ....
2. ....
3. ....
4. ....
5. ....

# "FEAR"



List the muscles of facial expression which are activated.

1. ....
2. ....
3. ....
4. ....
5. ....

# "DETERMINATION"



List the muscle(s) of facial expression which are activated.

1. ....
2. ....
3. ....
4. ....
5. ....

# "IRONY"



List the muscles of facial expression which are activated.

1. ....
2. ....
3. ....
4. ....
5. ....

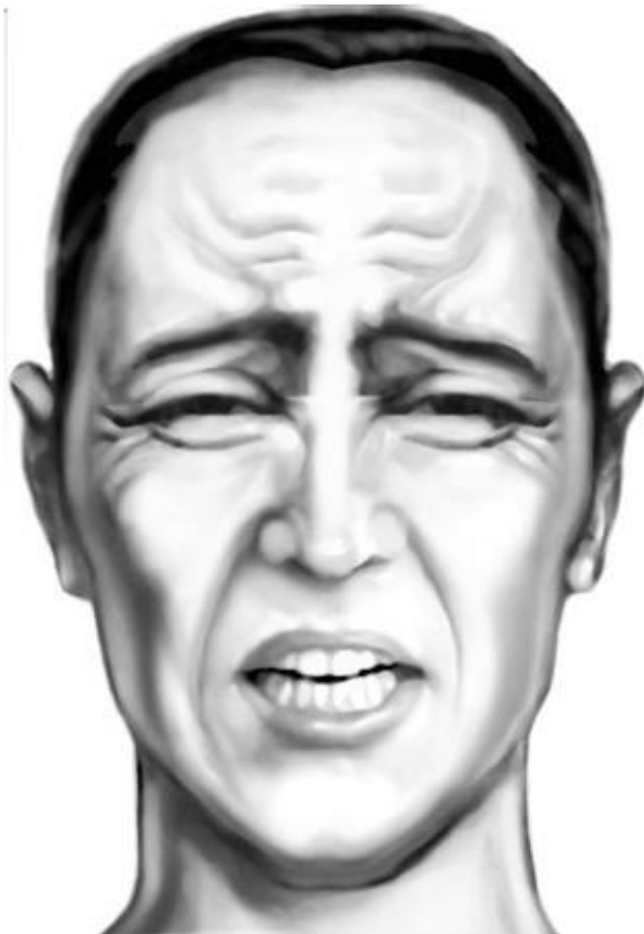# “LAUGHTER”



List the muscles of facial expression which are activated.

1. ....
2. ....
3. ....
4. ....
5. ....

# “CRYING”



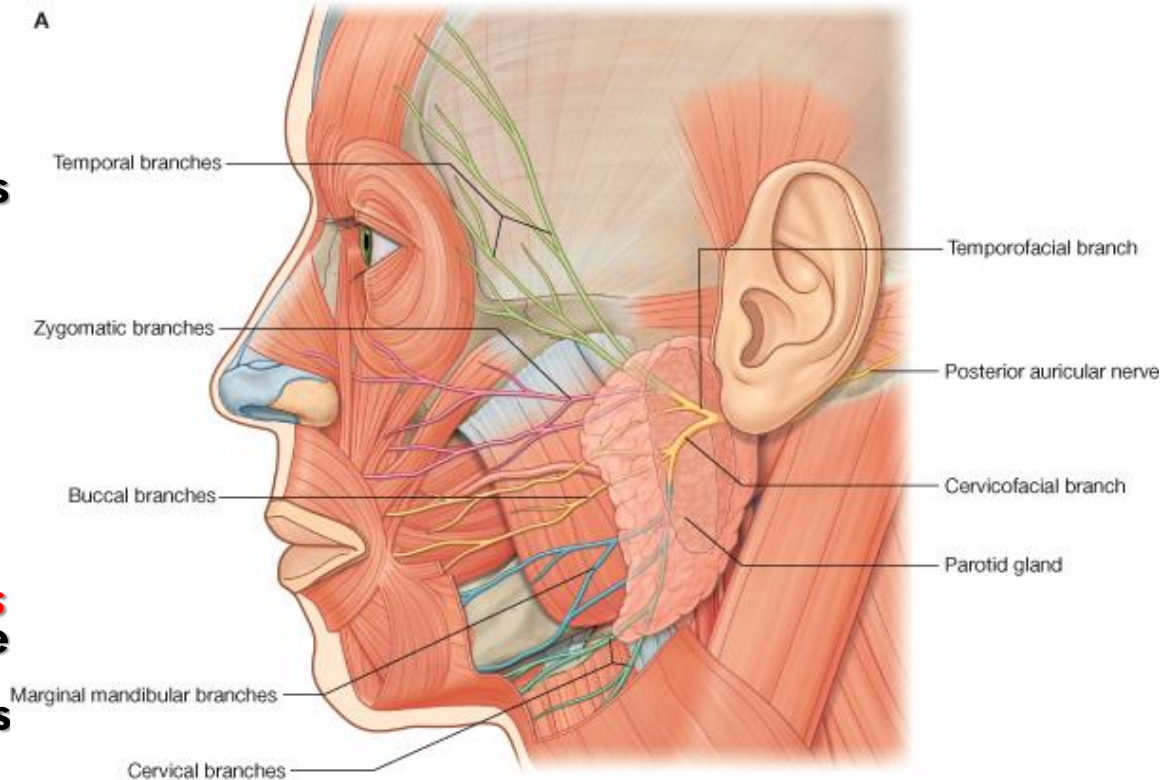
List the muscles of facial expression which are activated.

1. ....
2. ....
3. ....
4. ....
5. ....



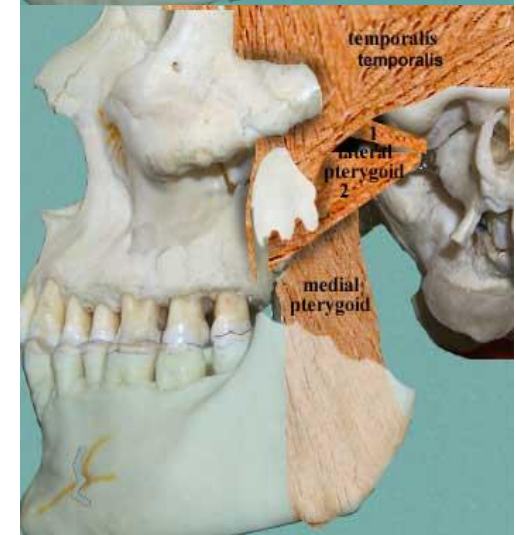
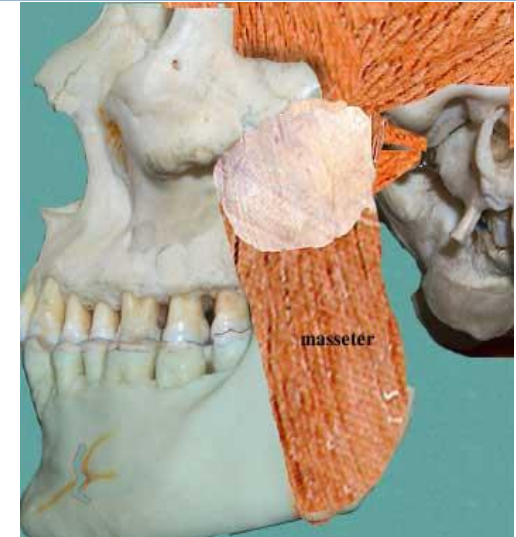
# Facial Nerve

- As the facial nerve runs forward within the substance of the parotid salivary gland, it divides into its **five** terminal branches.
- **The facial nerve does not supply the skin, but its branches communicate with branches of the trigeminal nerve.**
- It is believed that **the proprioceptive nerve fibers of the facial muscles leave the facial nerve in these communicating branches and pass to the central nervous system via the trigeminal nerve.**



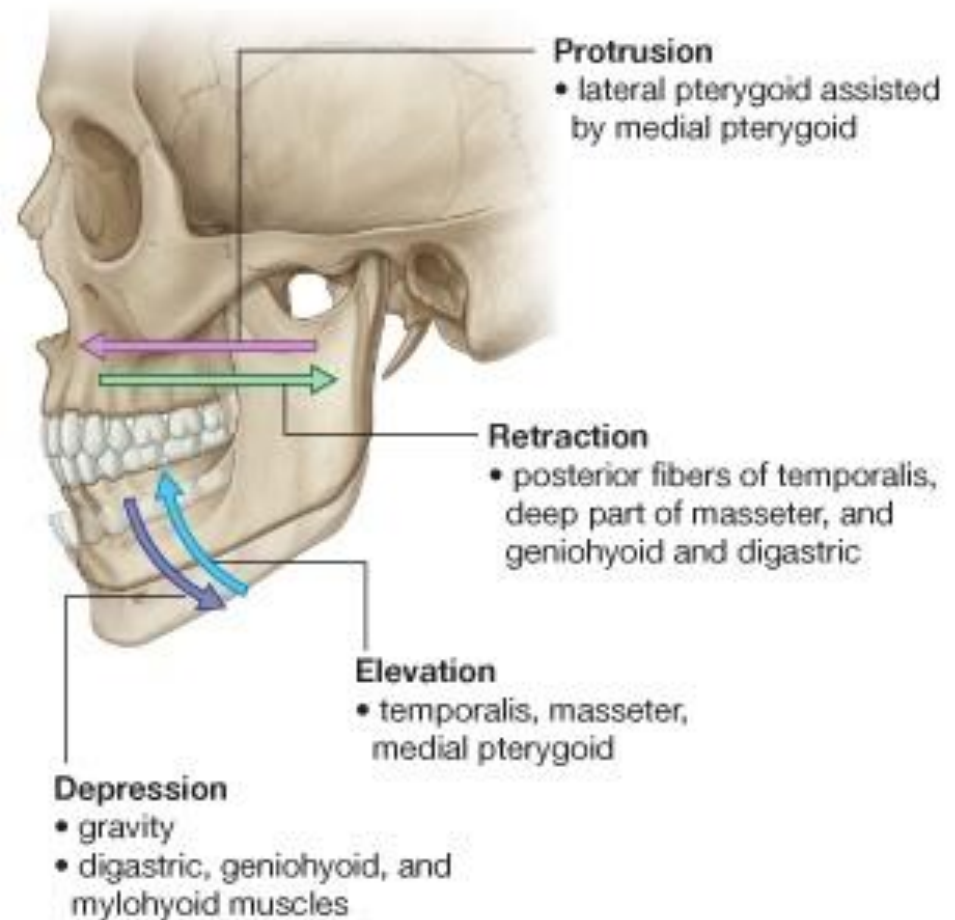
# Muscles of mastication

- They are **derived from mesoderm of 1<sup>st</sup> branchial arch**
- They **originate from temporal or infratemporal fossa**
- They are **inserted into ramus of mandible**
- They are **supplied, through their deep surfaces by branches of mandibular nerve**
- They **act on temporomandibular joint**



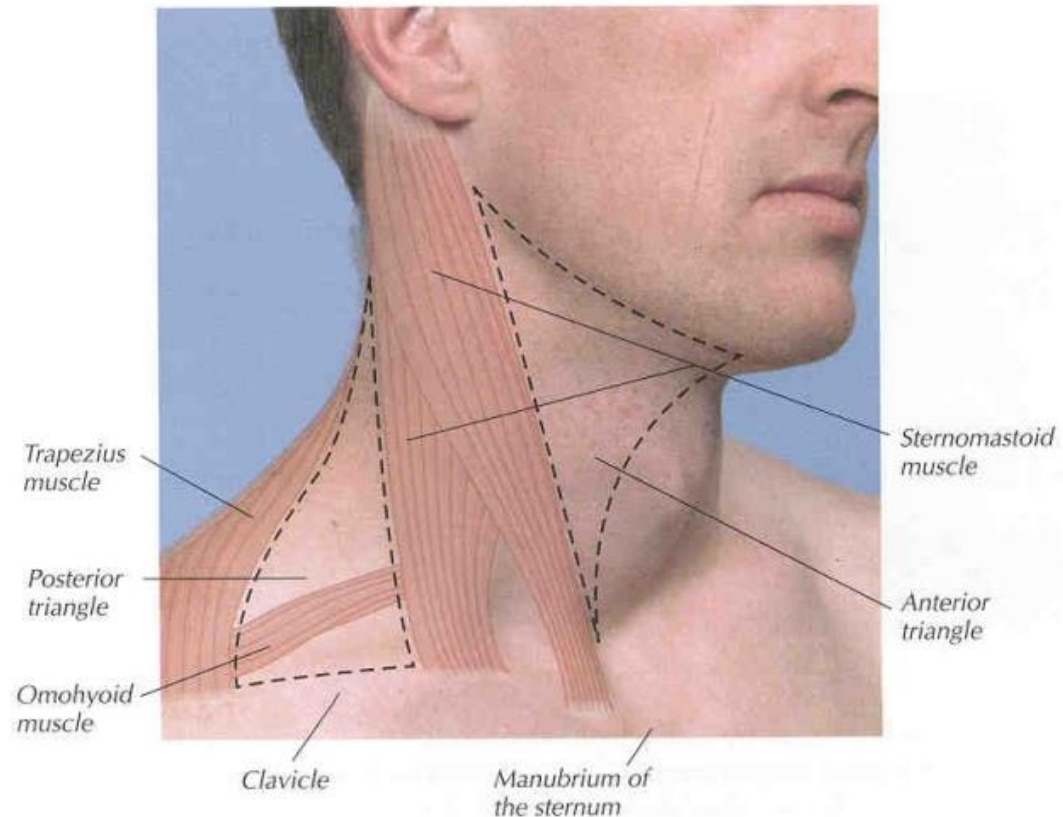
# Cont.

- **ALL MUSCLES OF MASTICATION**
  - **Elevate mandible EXCEPT**
    - **Lateral pterygoid**
  - **Protrude mandible EXCEPT**
    - **Temporalis**
  - **Are supplied by anterior division of mandibular nerve EXCEPT**
    - **Medial pterygoid**



# Muscles of the Neck

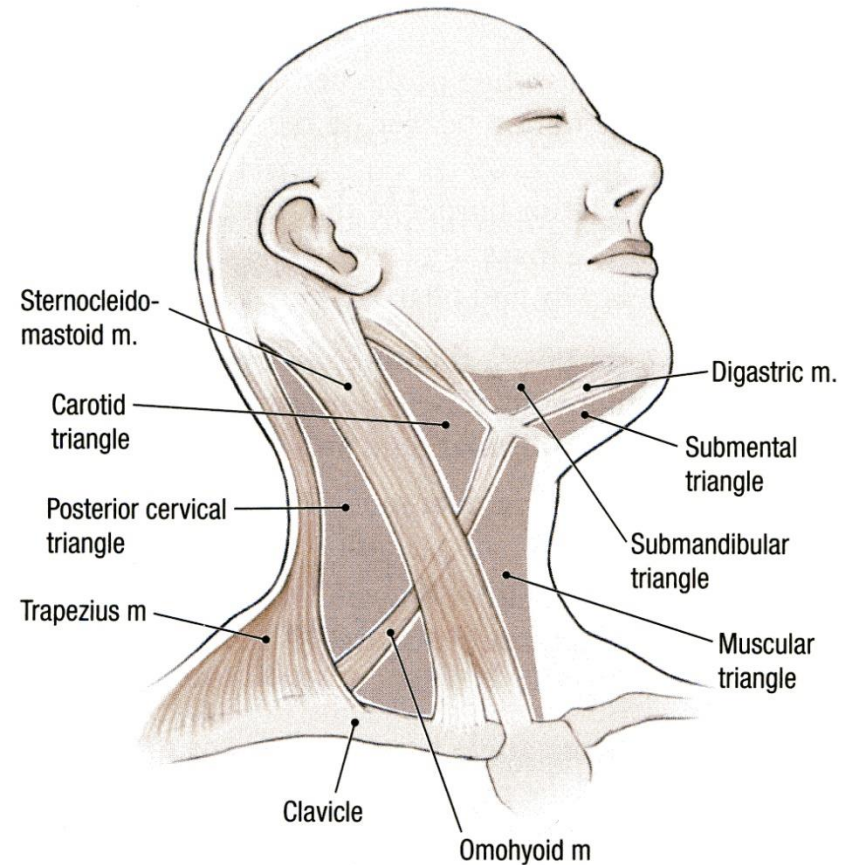
- **Muscles of the neck either support and move the head or are attached to structures within the neck region, such as the hyoid bone and larynx.**





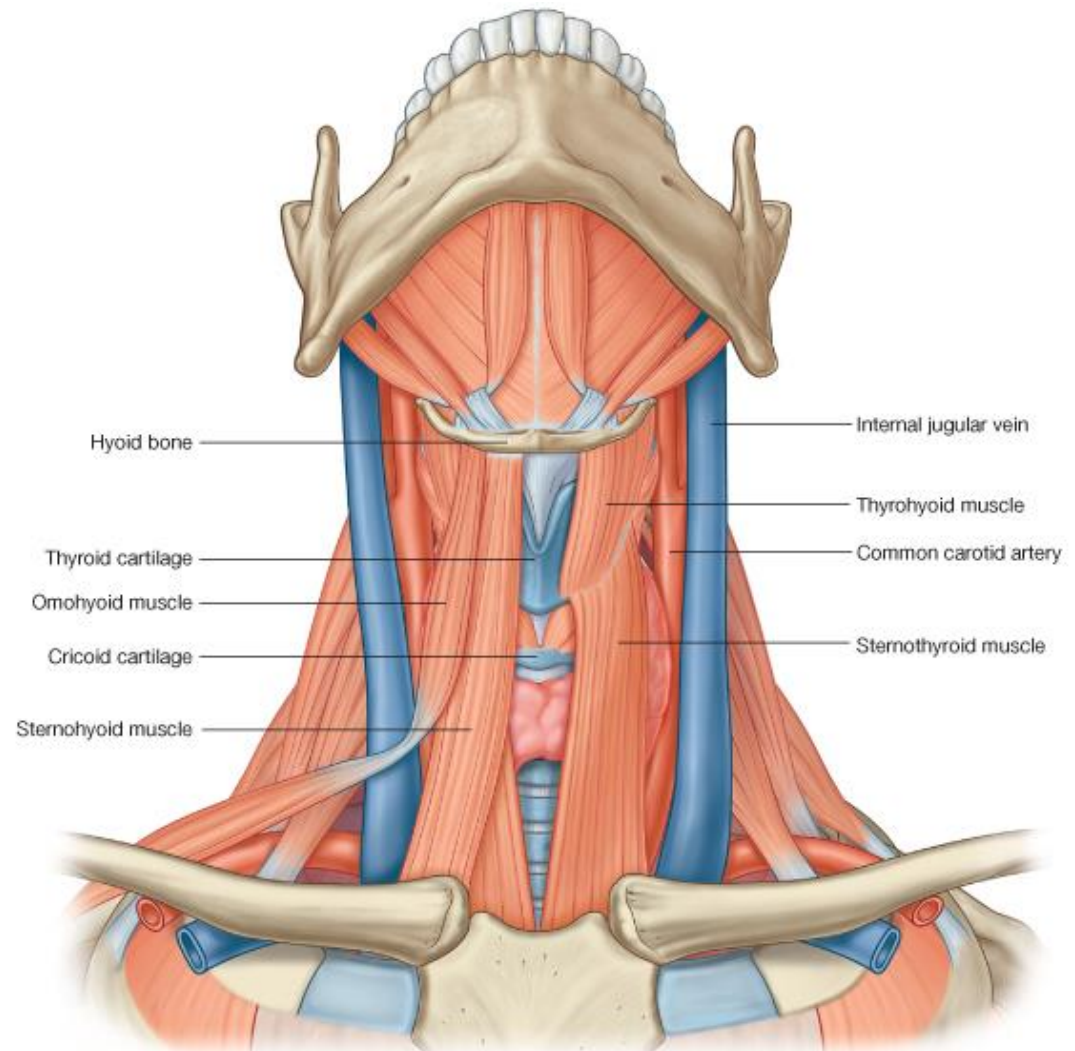
# Sternocleidomastoid

- ❑ **Origin:** Upper part of manubrium & medial third of clavicle
- ❑ **Insertion:** Mastoid process & lateral part of superior nuchal line
- ❑ **Nerve supply:** Spinal part of accessory nerve (motor) & ventral rami of C2-3 (proprioceptive)
- ❑ **Action:**
  - ❑ Both muscles acting together extend head at atlanto-occipital joint, and flex cervical part of vertebral column
  - ❑ Contraction of one muscle moves the face to the opposite side



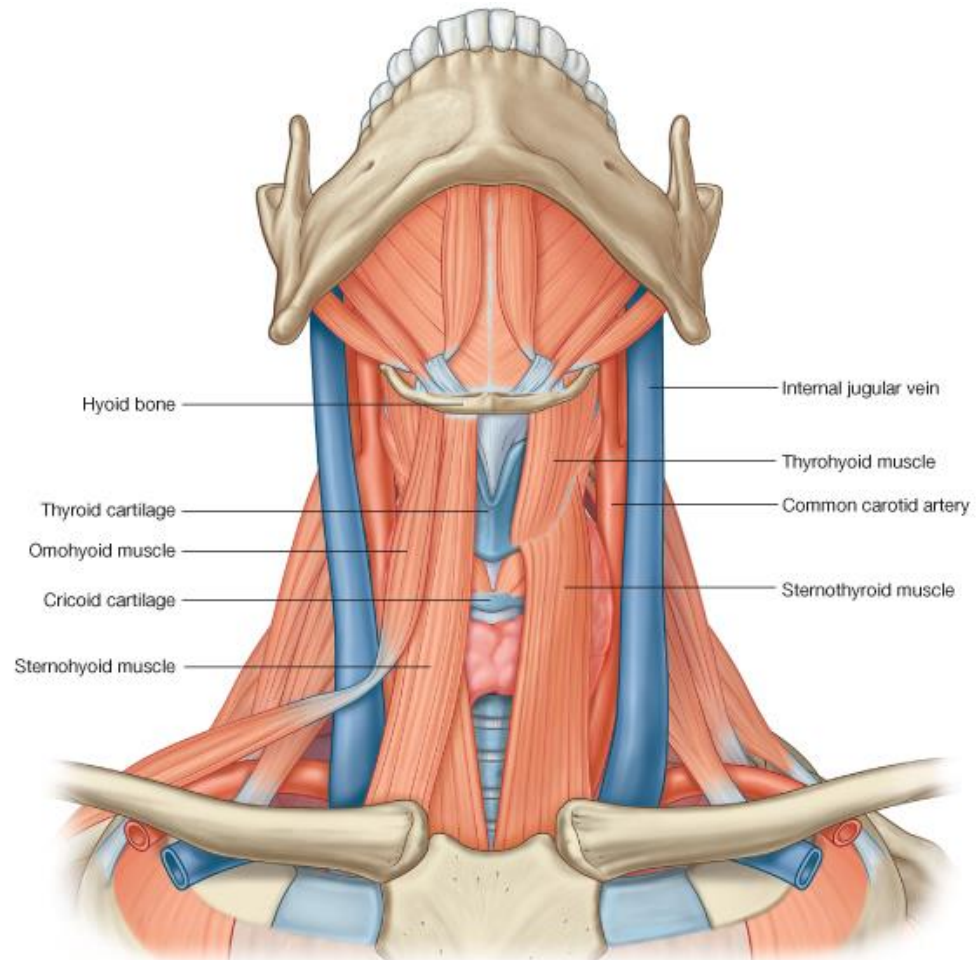
# Muscles of anterior triangle

- **The muscles in the anterior triangle of the neck can be grouped according to their location relative to the hyoid bone:**
  - **Muscles superior to the hyoid are classified as suprahyoid muscles and include the stylohyoid, digastric, mylohyoid, and geniohyoid;**
  - **Muscles inferior to the hyoid are infrahyoid muscles and include the omohyoid, sternohyoid, thyrohyoid, and sternothyroid.**



# The Infrahyoid Muscles

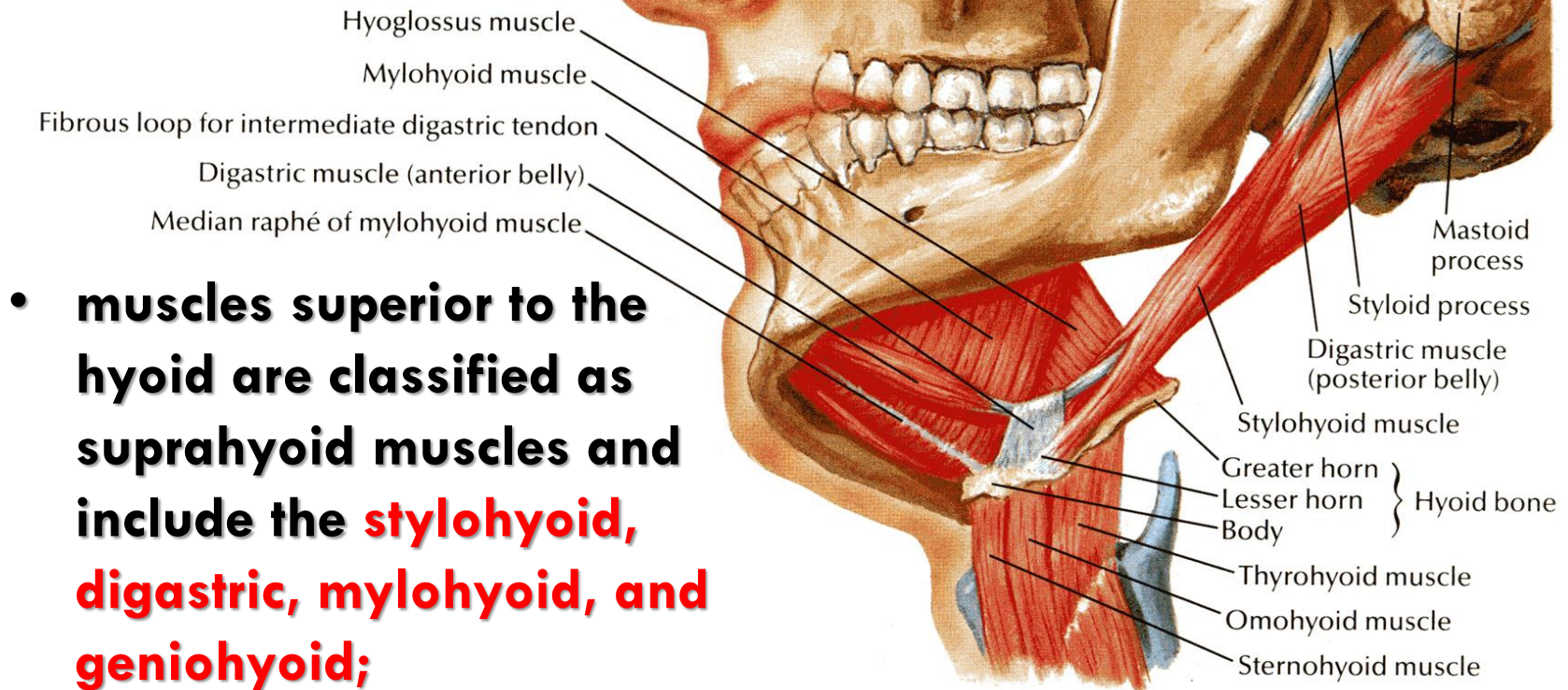
- **Superficial layer:**
  - **Sternohyoid:** medially
  - **Omohyoid:** laterally
- **Deep layer:**
  - **Thyrohyoid:** above
  - **Sternothyroid:** below
- **All muscles are supplied by **ansa cervicalis** (anterior rami of C1,2,3) EXCEPT: thyrohyoid (by anterior ramus of C1)**
- **Anchor the hyoid, sternum, clavicle, and scapula and depress the hyoid and larynx during swallowing and speaking.**





# Suprahyoid Muscles

Lateral, slightly inferior view



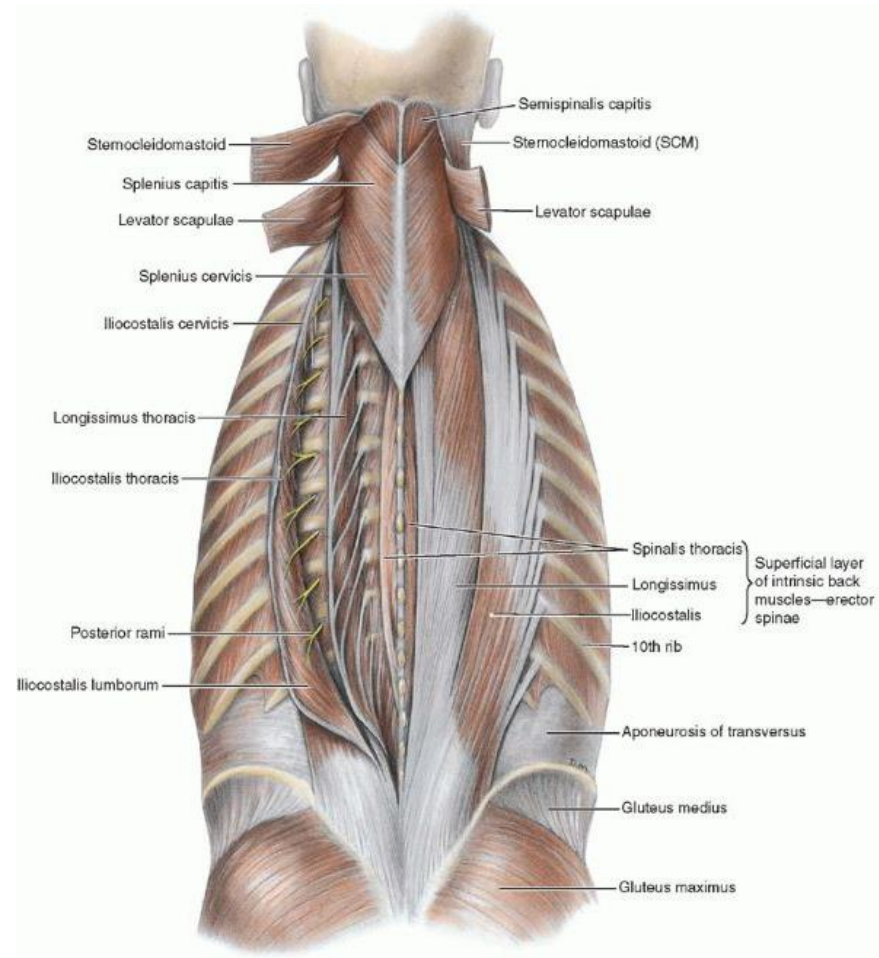


# Muscles of back

- **Most body weight lies anterior to the vertebral column, especially in obese people; consequently, the many strong muscles attached to the spinous and transverse processes of the vertebrae are necessary to support and move the column.**
- **They are organized into 3 groups:**
  - **Deep group (intrinsic muscles): develop in the back, supplied by posterior rami of spinal nerves, attached to & move vertebral column & head.**
  - **Intermediate group: attached to ribs, may serve respiratory functions.**
  - **Superficial group: attached to & involved in movements of upper limb.**
- ***N.B.: Both intermediate & superficial groups are called “extrinsic muscles” : not develop in the back, supplied by anterior rami of spinal nerves.***

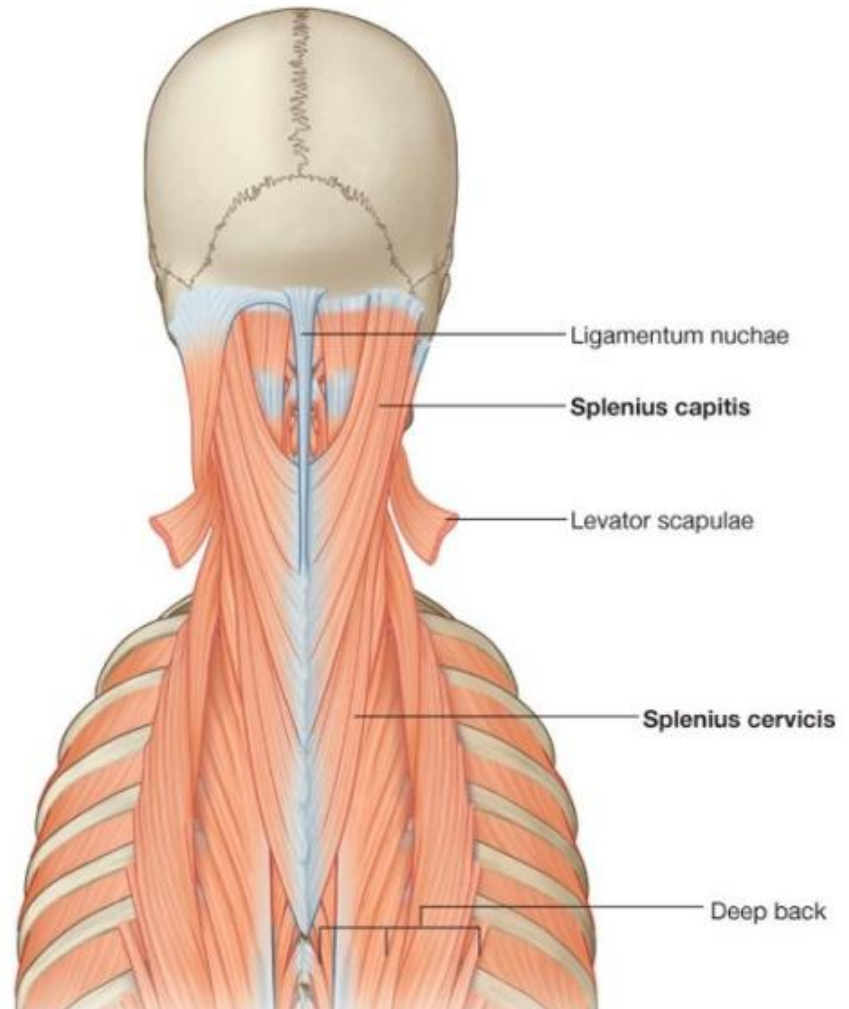
# Deep Group of Back Muscles/Intrinsic

- They extend from sacrum to skull.
- They include extensors and rotators of head & vertebral column.
- Their tone is responsible for maintenance of normal curve of vertebral column.
- The largest muscle of this group is “erector spinae” which is formed of 3 vertical columns (from lateral to medial: iliocostalis, **longissimus** & **spinalis**).



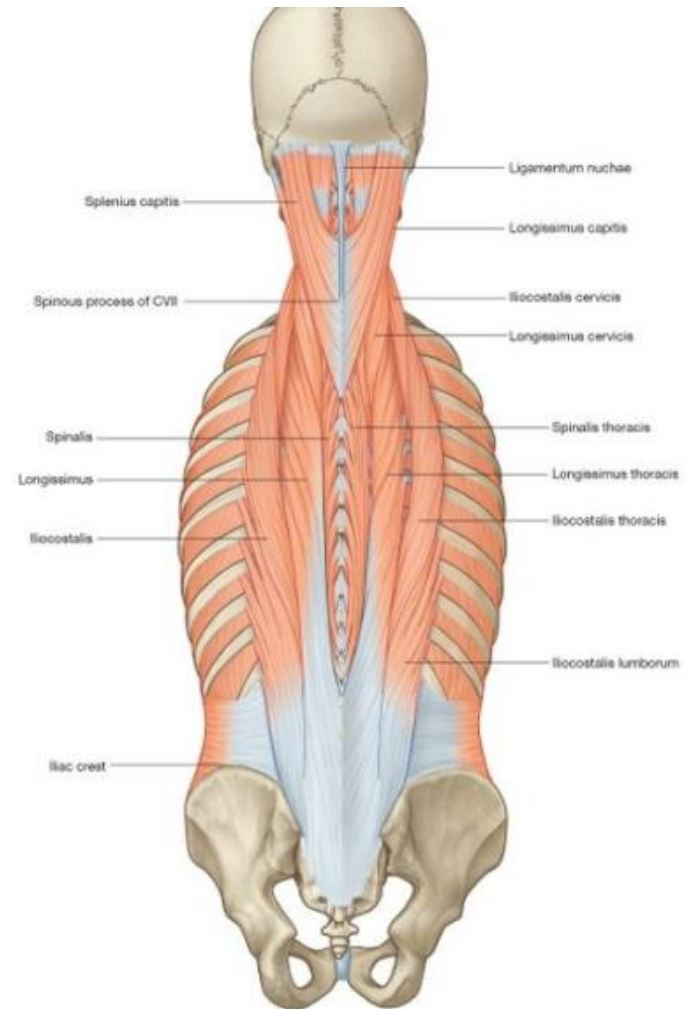
# 1. Superficial Layer Of Intrinsic Back Muscles

- The splenius muscles are thick and flat and lie on the lateral and posterior aspects of the neck, covering the vertical muscles somewhat like a bandage.
- **Action :**
  - Acting alone: laterally flex neck and rotate head to side of active muscles
  - Acting together: extend head and neck
- **Innervation :**
  - Posterior rami of spinal nerves



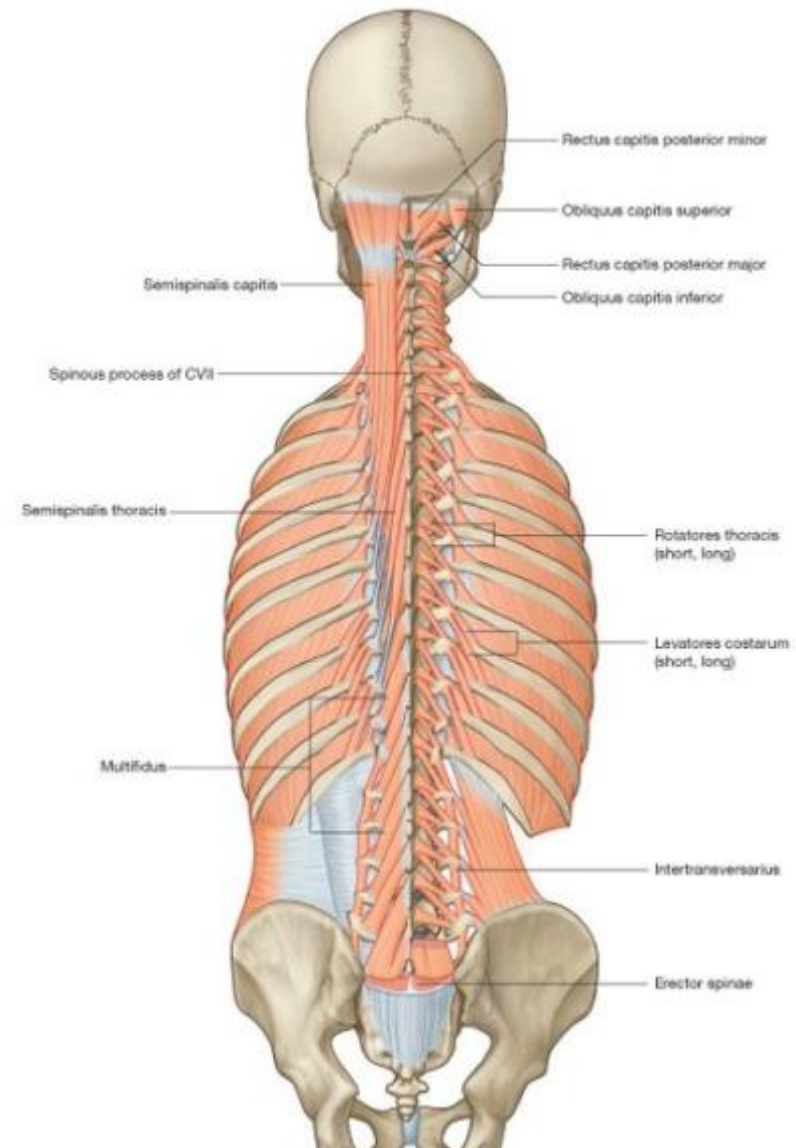
## 2. Intermediate Layer

- The massive **erector spinae** muscles lie in a “groove” on each side of the vertebral column between the spinous processes centrally and the angles of the ribs laterally.
- The erector spinae are the chief extensors of the vertebral column and are divided into three columns:
  - the iliocostalis forms the lateral column,
  - the longissimus forms the intermediate column, and
  - the spinalis forms the medial column.
- **Acting bilaterally: extend vertebral column and head; Acting unilaterally: laterally flex vertebral column**



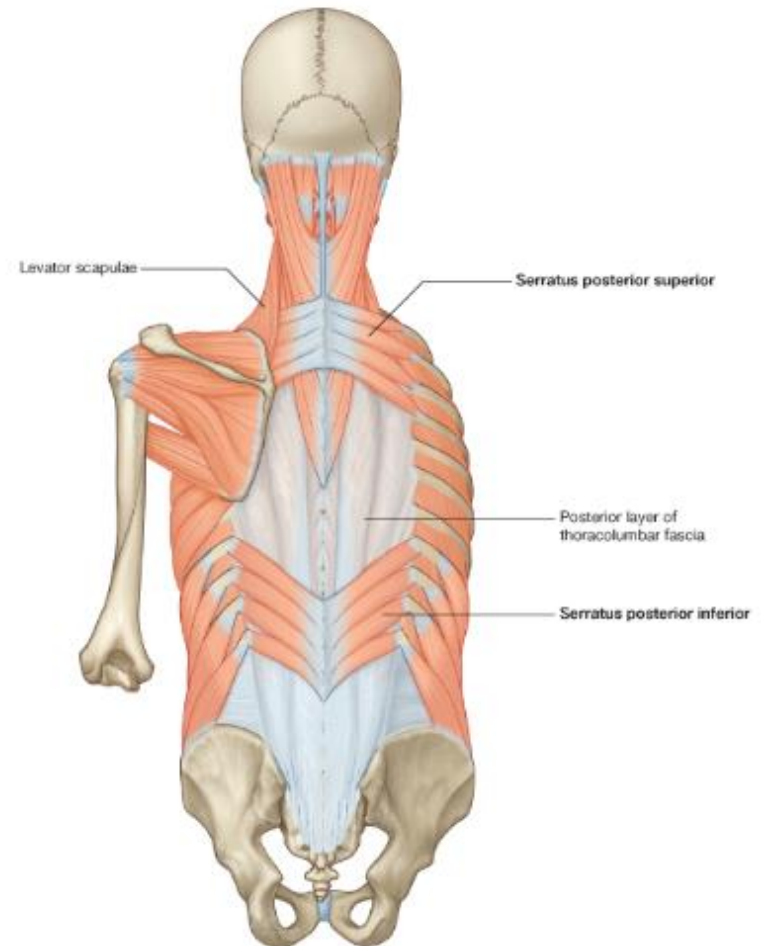
# 3. Deep Layer

- Deep to the erector spinae is an obliquely disposed group of much shorter muscles, **the transversospinales muscle group** consisting of the:
  - **Semispinalis:** extends head and thoracic and cervical regions of vertebral column and rotates them contralaterally
  - **Multifidus:** stabilizes vertebrae during local movements of vertebral column
  - **Rotatores:** stabilize vertebrae and assist with local extension and rotatory movements of vertebral column; may function as organs of proprioception
  - **They occupy the “gutter” between the transverse and the spinous processes**



# Intermediate Group Of Back Muscles

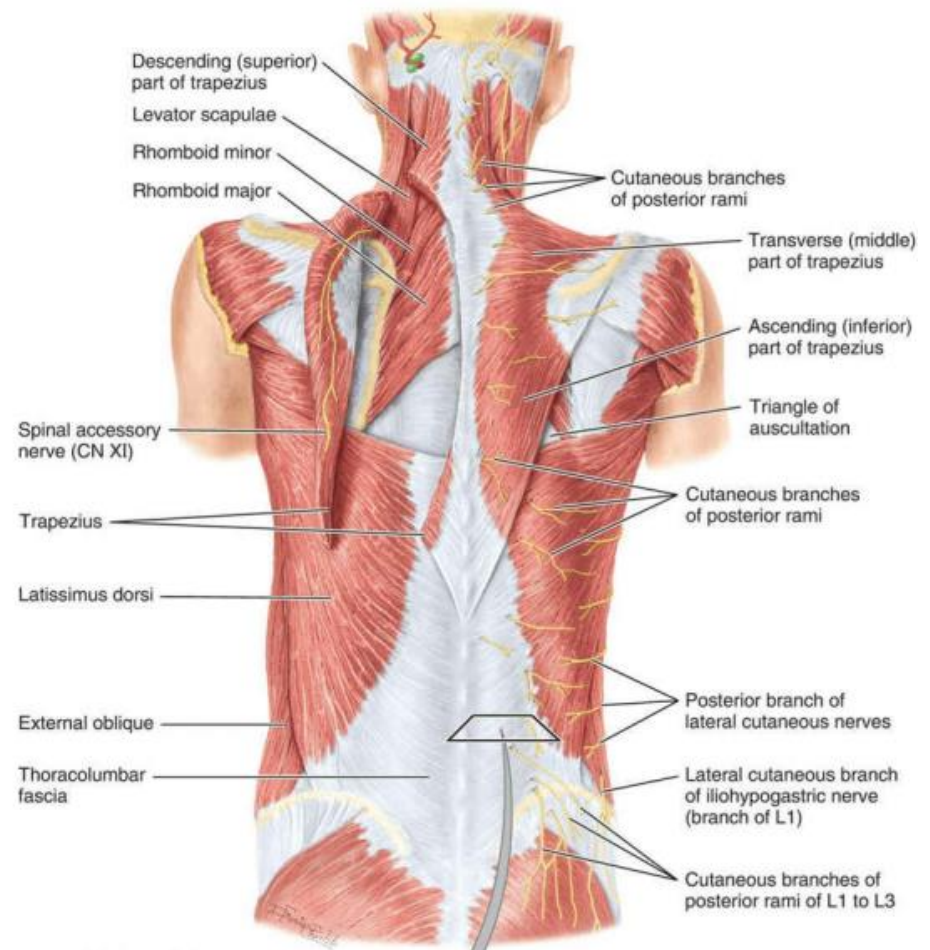
- ❑ It is separated from the deep group by thoracolumbar fascia.
  - ❑ **Serratus posterior superior** (*rib elevator*).
  - ❑ **Serratus posterior inferior** (*rib depressor*).
- ❑ Nerve supply: anterior rami of thoracic spinal nerves.
- ❑ Proprioceptive function





# Superficial Group Of Back Muscles

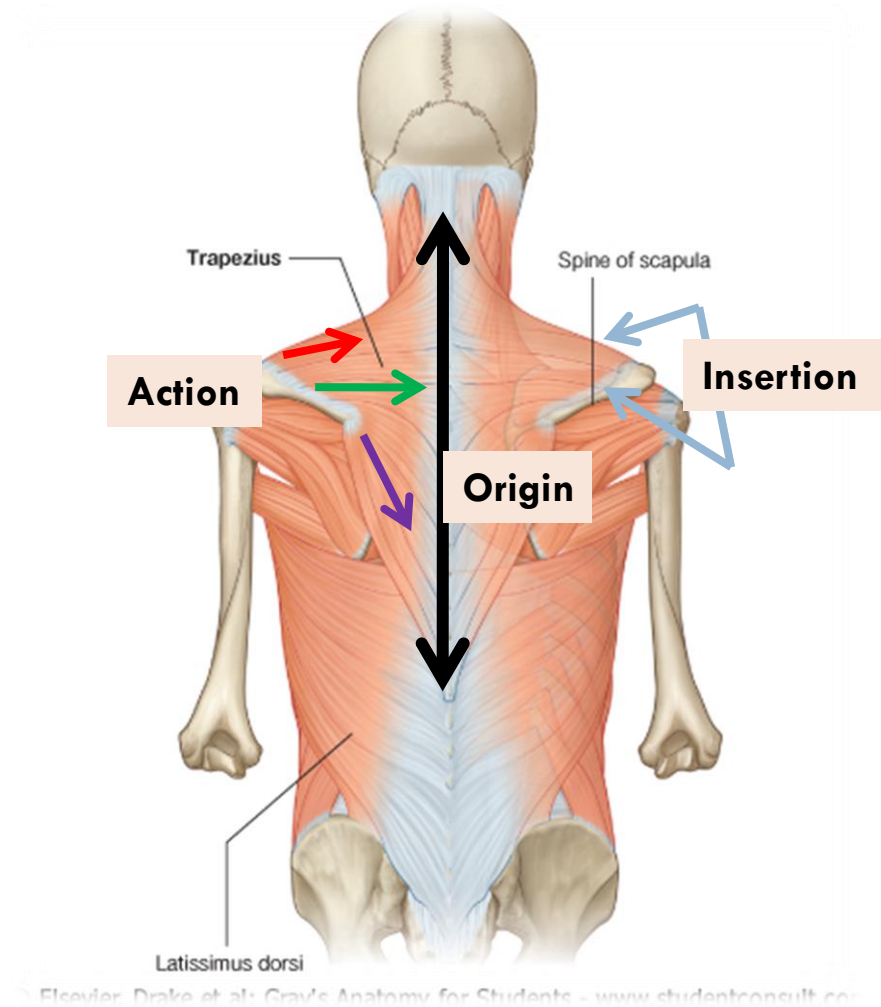
- ❑ **MUSCLES CONNECTING VERTEBRAL COLUMN TO SCAPULA** (move scapula through shoulder girdle joints):
  - ❑ *Trapezius.*
  - ❑ *Levator scapulae.*
  - ❑ *Rhomboid minor.*
  - ❑ *Rhomboid major.*
- ❑ **MUSCLE CONNECTING VERTEBRAL COLUMN TO HUMERUS** (move humerus through shoulder joint):
  - ❑ *Latissimus dorsi.*





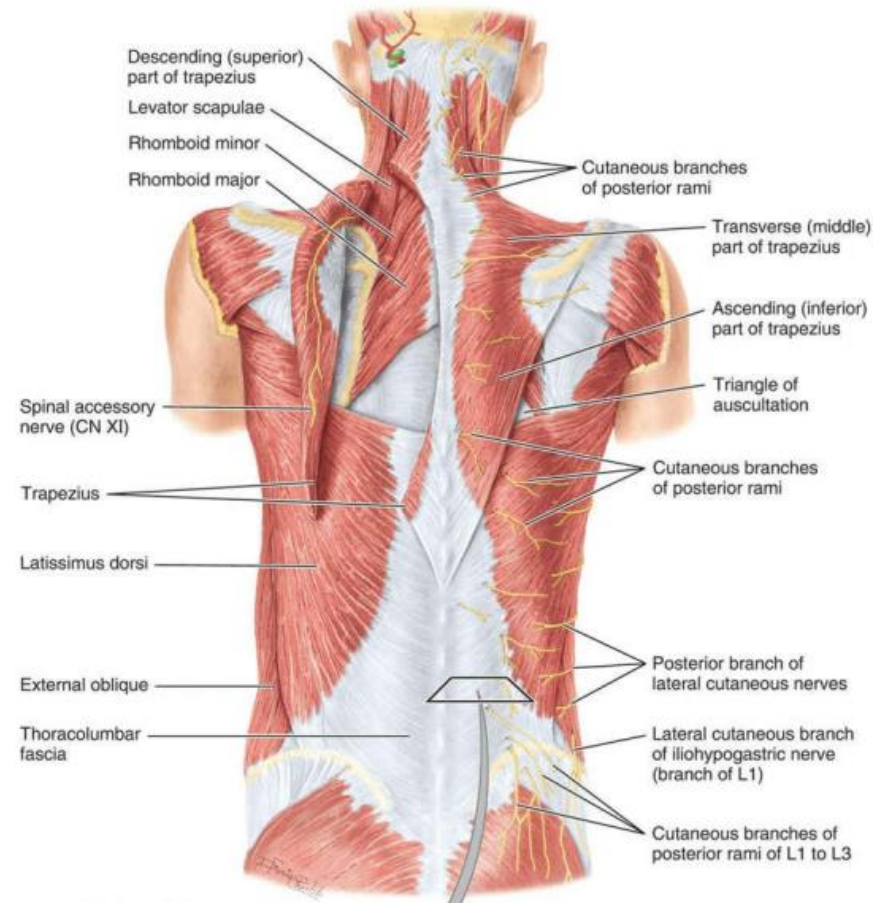
# TRAPEZIUS

- ❑ **Origin:** Spines of cervical & thoracic vertebrae
- ❑ **Insertion:** lateral 1/3 of clavicle + acromion & spine of scapula.
- ❑ **Action:** rotation of scapula during abduction of humerus above horizontal.
  - ❑ **Upper fibers:** elevate scapula.
  - ❑ **Middle fibers:** retract scapula
  - ❑ **Lower fibers:** depress scapula.
- ❑ **Nerve supply:** Spinal part of accessory (11<sup>th</sup> cranial) nerve.



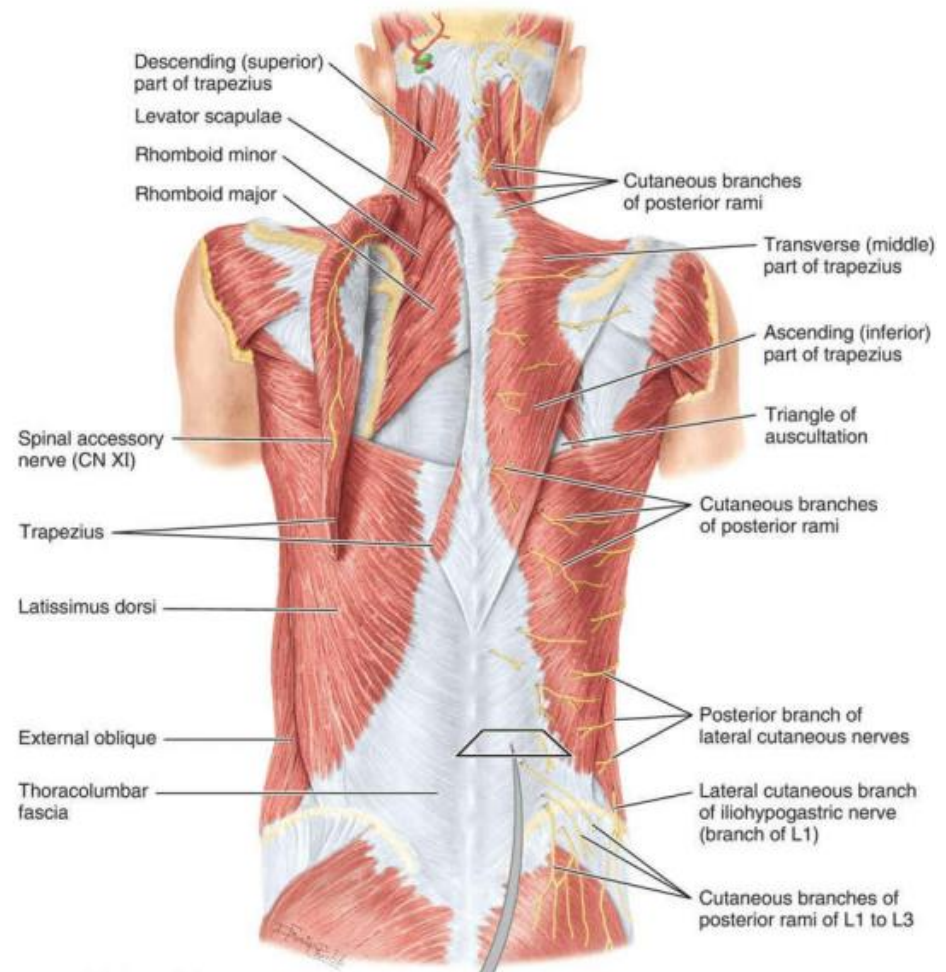
# LEVATOR SCAPULAE; RHOMBOID MINOR & MAJOR

- ❑ **Origin:**
  - ❑ *Levator scapulae*: cervical transverse processes
  - ❑ *Rhomboid minor & major*: thoracic spines
- ❑ **Insertion:** medial border of scapula.
- ❑ **Nerve supply:** dorsal scapular nerve.
- ❑ **Actions:**
  - ❑ *Levator scapulae*: elevates scapula.
  - ❑ *Rhomboid minor & major*: retract scapula.



# Latissimus Dorsi

- ❑ **Origin: spines of thoracic vertebrae.**
- ❑ **Insertion: bicipital groove of humerus.**
- ❑ **Nerve supply: thoracodorsal nerve.**
- ❑ **Actions: extension, adduction & medial rotation of humerus (arm, shoulder joint).**



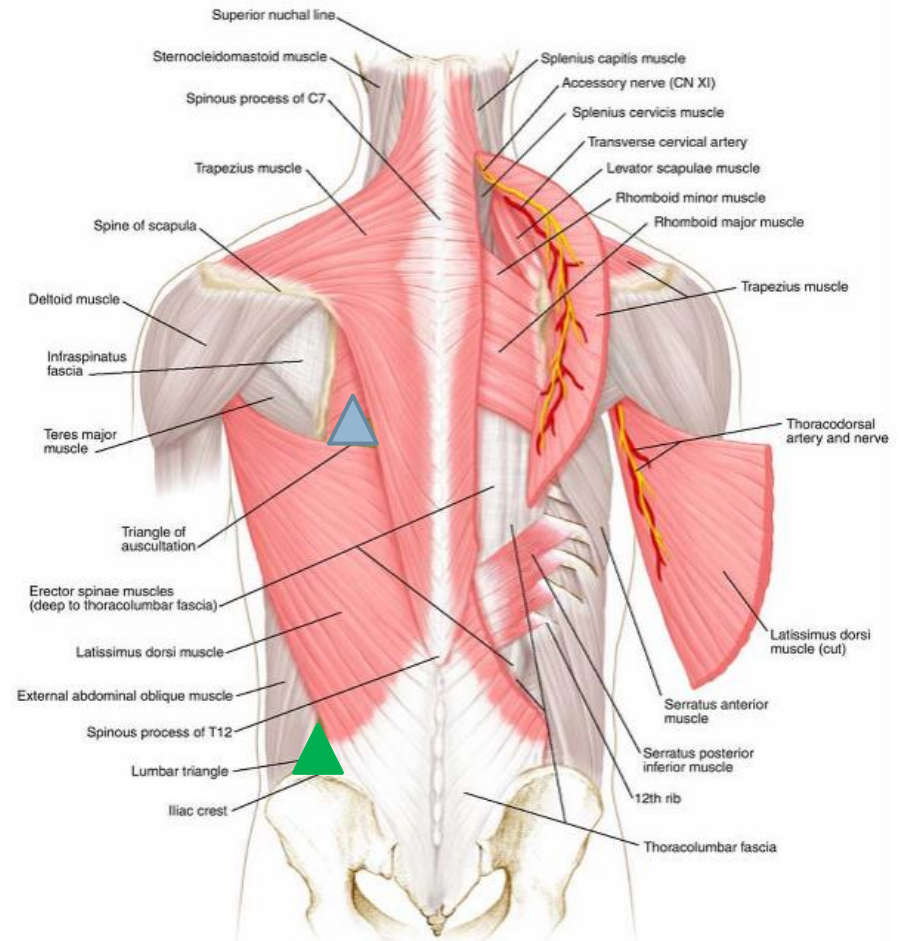
# Muscular Triangles Of Back

## □ Auscultatory Triangle: ▲

- Site on back where breath sounds are most easily heard with a stethoscope.
- Boundaries: latissimus dorsi, trapezius, and medial border of scapula.

## □ Lumbar Triangle: ▲

- Site where pus may emerge from the abdominal wall.
- Boundaries : latissimus dorsi, posterior border of external oblique muscle of the abdomen, and iliac crest.



# Muscles Involved In Respiration

## □ **Movements of Diaphragm**

- Contraction (descent) of diaphragm-Increase of vertical diameter of thoracic cavity
- Relaxation (ascent) of diaphragm)- Expiration

## □ **Movements of Ribs by external intercostal muscles**

- Pump Handle Movement ; Elevation of ribs; Increase in antero-posterior diameter of thoracic cavity
- Bucket Handle Movement; Elevation of ribs; Increase in lateral diameter of thoracic cavity

## □ **Expiratory Muscles:**

- Act only during forced expiration



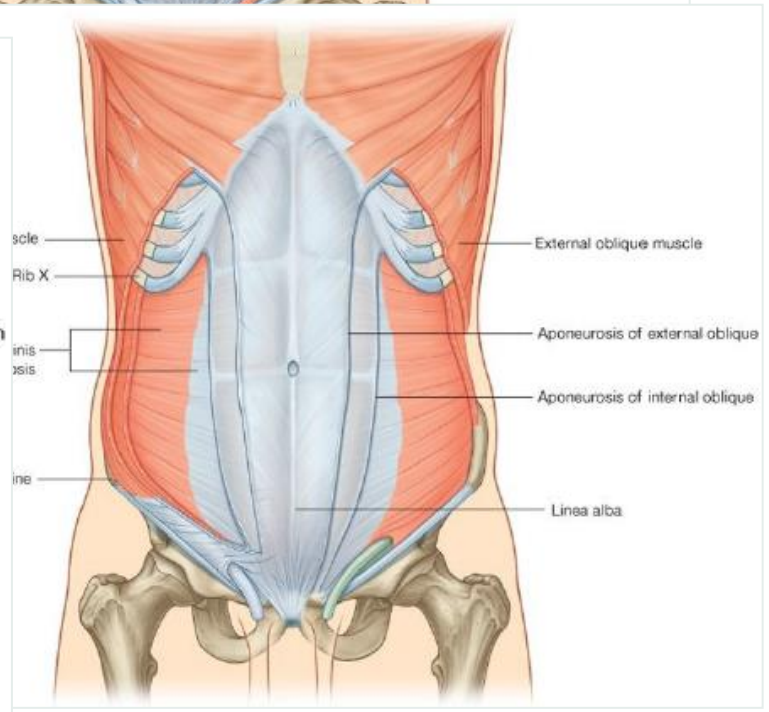
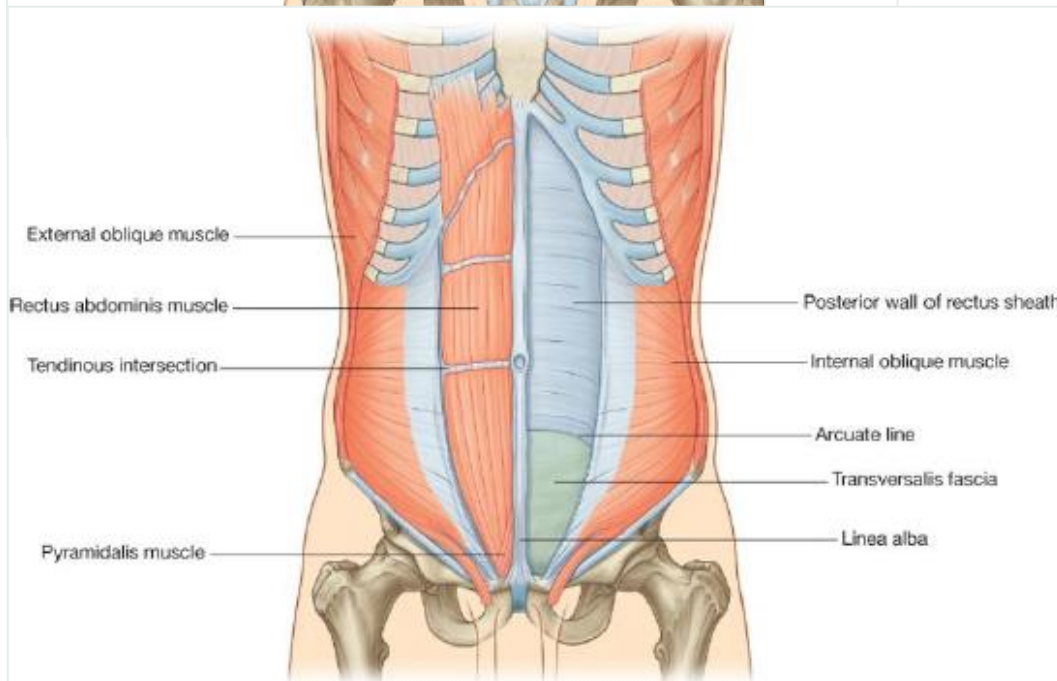
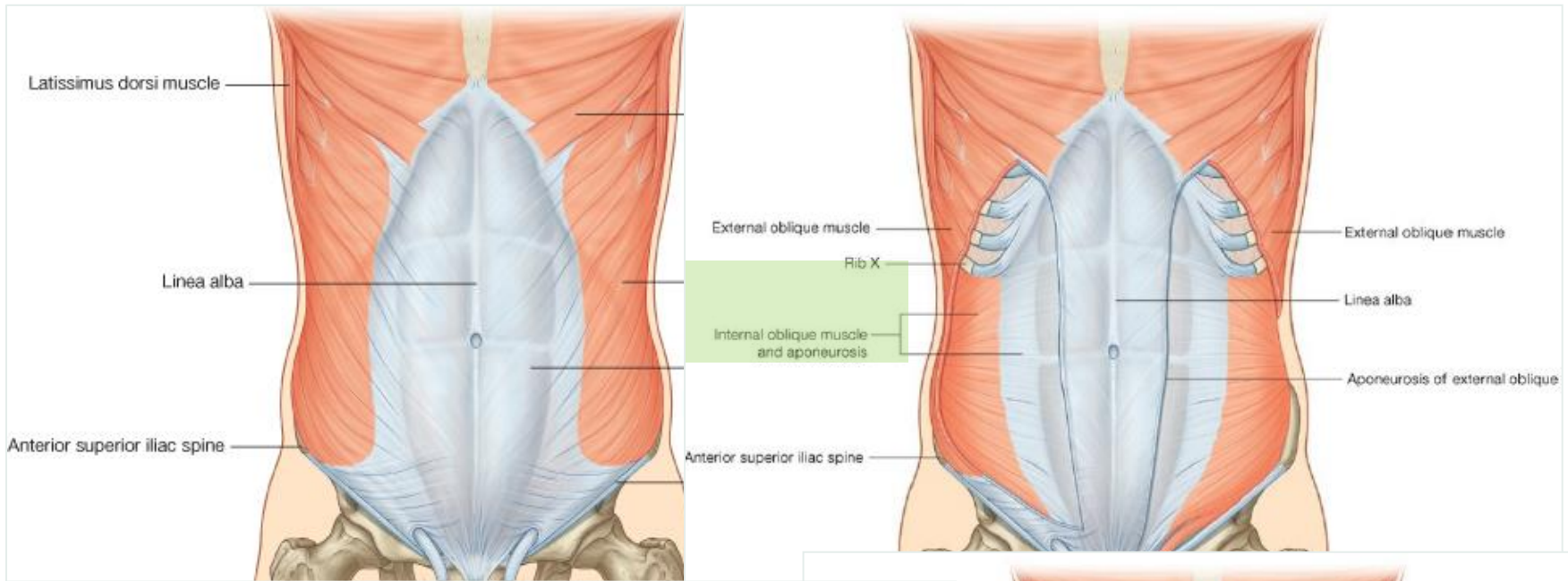
# Anterior Abdominal Wall

- **It is formed of 3 layers of muscles of fibers running in different directions (to increase strength of anterior abdominal wall) and two Vertical muscles**
  - **Form a strong expandable support for the anterolateral abdominal wall.**
  - **Protect the abdominal viscera from injury.**
  - **Compress the abdominal viscera to maintain or increase intra-abdominal pressure.**
  - **Produce the force required for defecation (evacuation of fecal material from the rectum), micturition (urination), vomiting, and parturition (childbirth).**
  - **Produce anterior and lateral flexion of the trunk, torsional (rotatory) movements of the trunk and help maintain posture.**

# Cont.

- The muscle fibers of the outer two layers running diagonally and perpendicular to each other
- The fibers of the deep layer running transversely
- All three flat muscles are continued anteriorly and medially as strong, sheet-like aponeuroses.
- Between the midclavicular line (MCL) and the midline, the aponeuroses form, **rectus sheath**
- The aponeuroses then interweave with their fellows of the opposite side, forming **linea alba**, which extends from the **xiphoid** process to the **pubic symphysis**.
- **Innervation**
  - Thoracoabdominal nerves (inferior 5 [T7-T11] thoracic nerves) and **subcostal nerve**



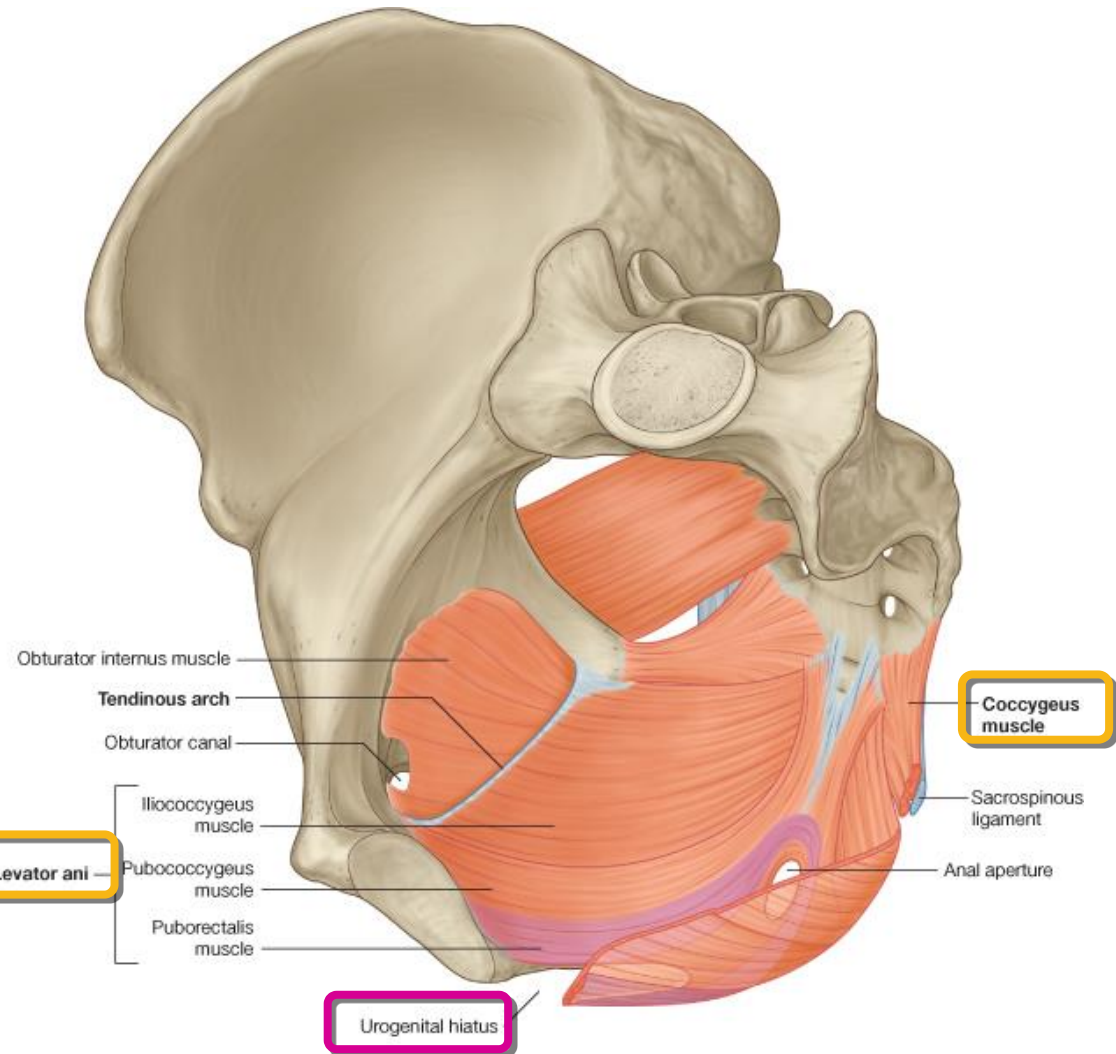


# Muscles of pelvic floor

- **The floor of the pelvis supports the pelvic viscera and is formed by the pelvic diaphragm.**
- **The pelvic floor stretches across the pelvis and divides it into the main pelvic cavity *above*, which contains the pelvic viscera, and the perineum *below*.**

# Pelvic Diaphragm

- The pelvic diaphragm is formed by the important **levatores ani muscles** and the small **coccygeus muscles** and their covering fasciae.
- It is **incomplete anteriorly** to allow passage of the urethra in males and the urethra and the vagina in females.
- **Nerve supply:** from the perineal branch of the fourth sacral nerve and from the perineal branch of the pudendal nerve.



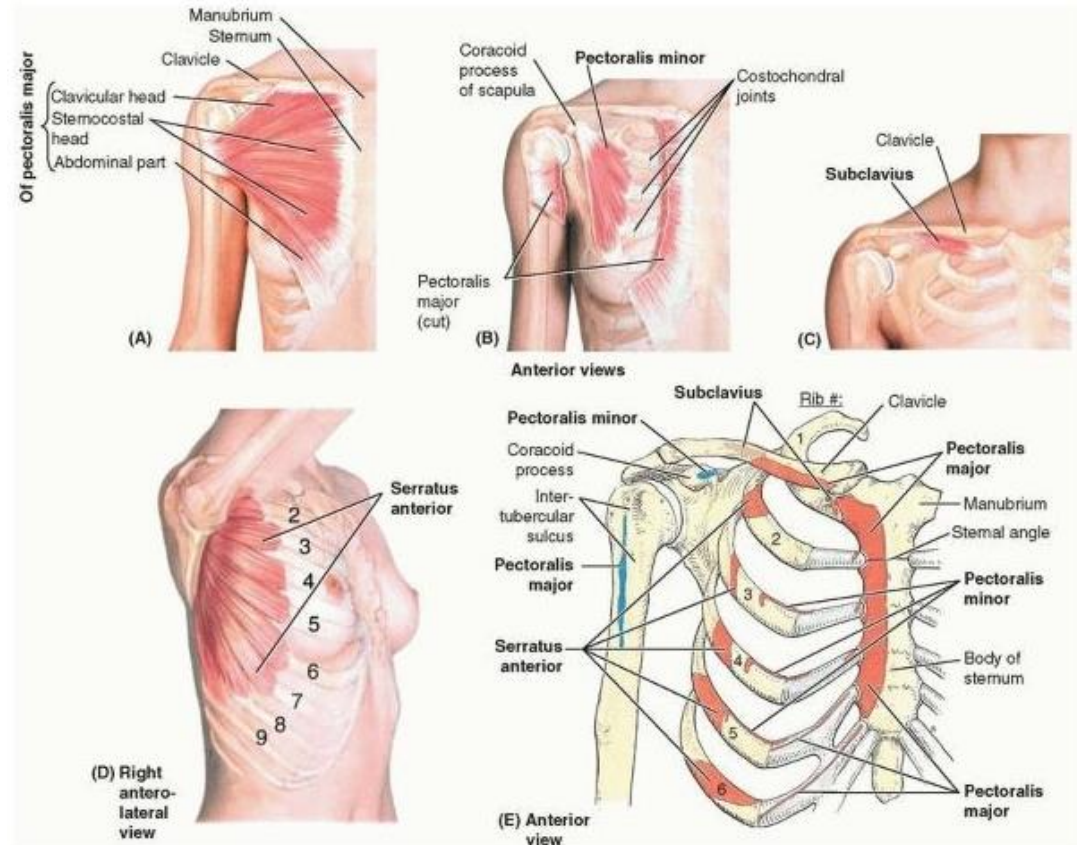
# Pectoral & Scapular Regions

- In terms of their attachments, the muscles of the proximal upper limb are
  - ▣ axioappendicular or
  - ▣ scapulohumeral.
- Axioappendicular muscles:
  - ▣ Serve to position the base from which the upper limb will be extended and function relative to the trunk.
  - ▣ These muscles consist of
    - anterior,
    - superficial posterior, and
    - deep posterior groups.
- The groups work antagonistically to elevate-depress and protract-retract the entire scapula or rotate it to elevate or depress the glenoid cavity and the glenohumeral joint

# Anterior Axioappendicular Muscles

- Four anterior axioappendicular muscles (thoracoappendicular or pectoral muscles) move the pectoral girdle:

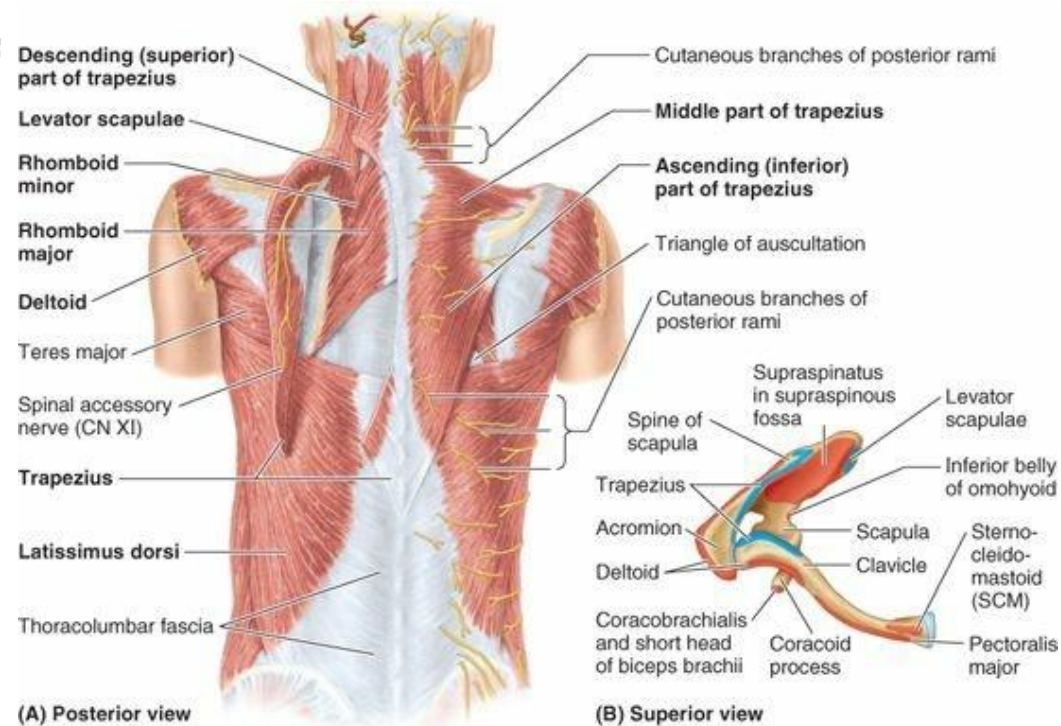
- pectoralis major,
- pectoralis minor,
- subclavius, and
- serratus anterior.





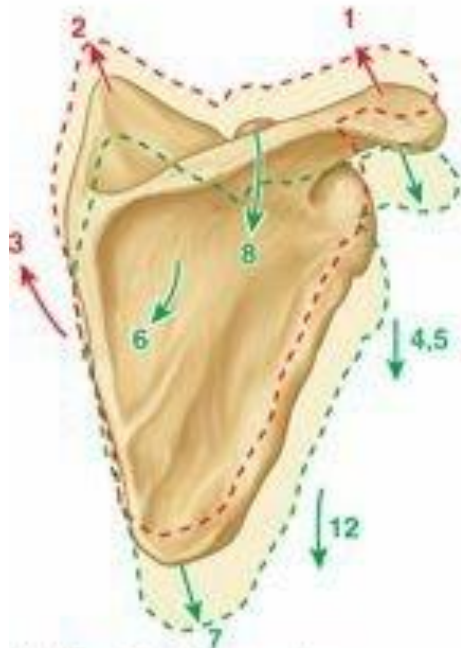
# Posterior Axioappendicular muscles

- **Attach the superior appendicular skeleton (of the upper limb) to the axial skeleton (in the trunk).**
- **Superficial posterior axioappendicular (extrinsic shoulder) muscles: trapezius and latissimus dorsi.**
- **Deep posterior axioappendicular (extrinsic shoulder) muscles: levator scapulae and rhomboids.**

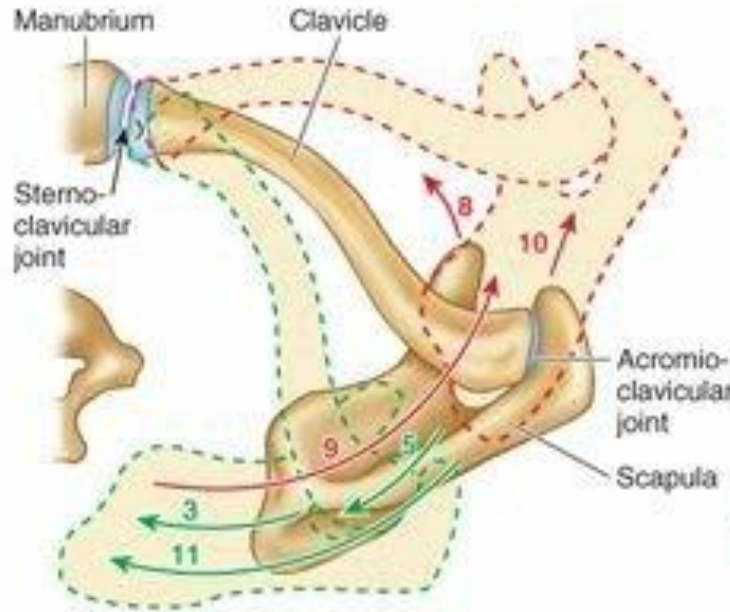




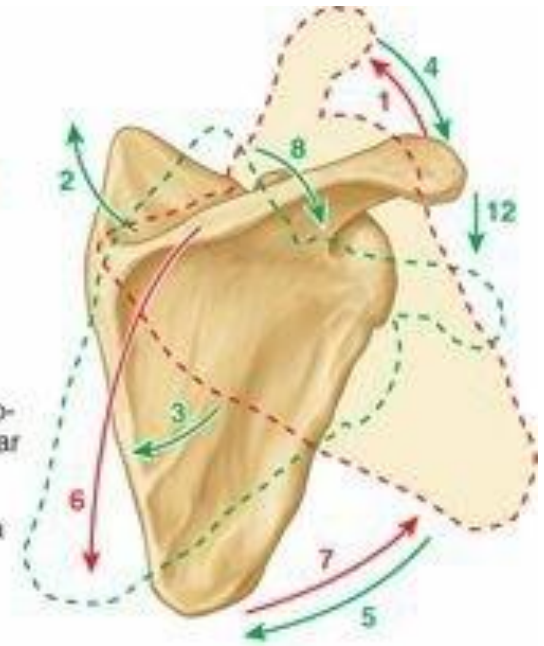
# Movements of scapula and muscles producing them



(A) Elevation/Depression  
Posterior view



(B) Protraction/Retraction  
Superior view of right half of pectoral girdle



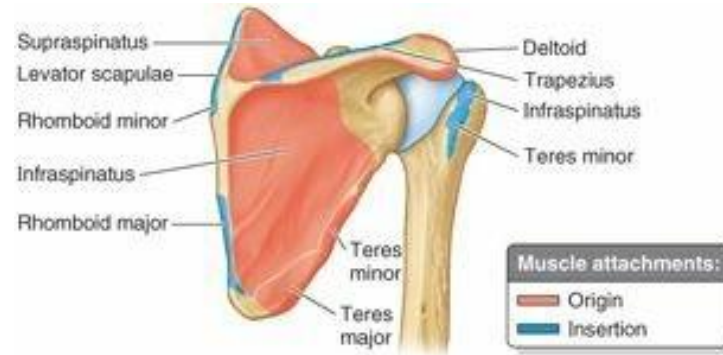(C) Upward rotation/  
Downward rotation  
Posterior view

# Cont.

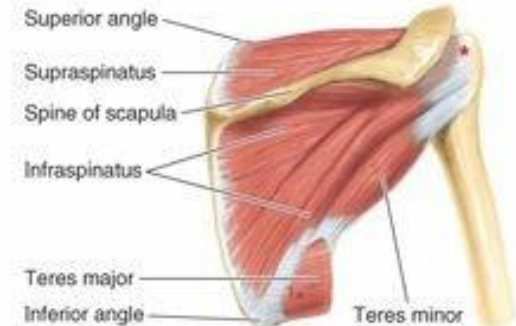Movement of Scapula	Muscles Producing Movement*	Nerve to Muscles	Range of Movement (Angular Rotation; Linear Displacement)
Elevation	Trapezius, descending part (1) Levator scapulae (2) Rhomboids (3)	Spinal accessory (CN XI) } Dorsal scapular	10–12 cm
Depression	Gravity (12) Pectoralis major, inferior sternocostal head (4) Latissimus dorsi (5) Trapezius, ascending part (6) Serratus anterior, inferior part (7) Pectoralis minor (8)	Pectoral nerves Thoracodorsal Spinal accessory (CN XI) Long thoracic Medial pectoral	
Protraction	Serratus anterior (9) Pectoralis major (10) Pectoralis minor (8)	Long thoracic Pectoral nerves Medial pectoral	40–45°; 15 cm
Retraction	Trapezius, middle part (11) Rhomboids (3) Latissimus dorsi (5)	Spinal accessory (CN XI) Dorsal scapular Thoracodorsal	
Upward rotation <sup>b</sup>	Trapezius, descending part (1) Trapezius, ascending part (6) Serratus anterior, inferior part (7)	} Spinal accessory (CN XI) Long thoracic	60°; inferior angle: 10–12 cm, superior angle: 5–6 cm
Downward rotation <sup>c</sup>	Gravity (12) Levator scapulae (2) Rhomboids (3) Latissimus dorsi (5) Pectoralis minor (8) Pectoralis major, inferior sternocostal head (4)	} Dorsal scapular  Thoracodorsal Medial pectoral Medial and lateral pectoral nerves	

# Scapulohumeral muscles

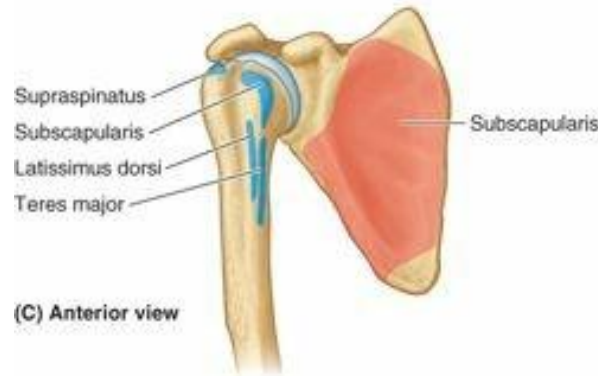
- Producing **abduction-adduction, flexion-extension, medial-lateral rotation, and circumduction of the arm.**
- Includes; **deltoid, teres major, and SITS muscles**



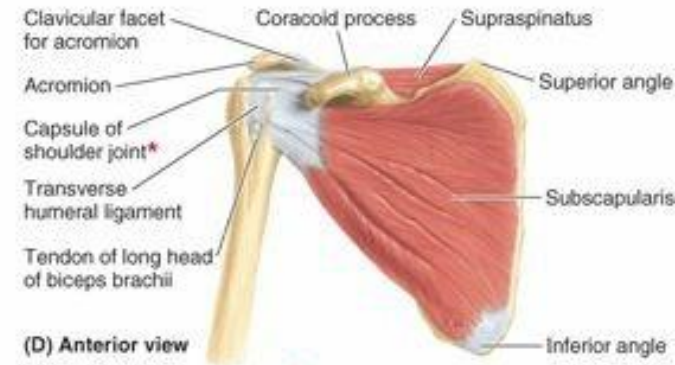
(A) Posterior view



(B) Posterior view



(C) Anterior view



(D) Anterior view

\*Musculotendinous rotator cuff

# Deltoid

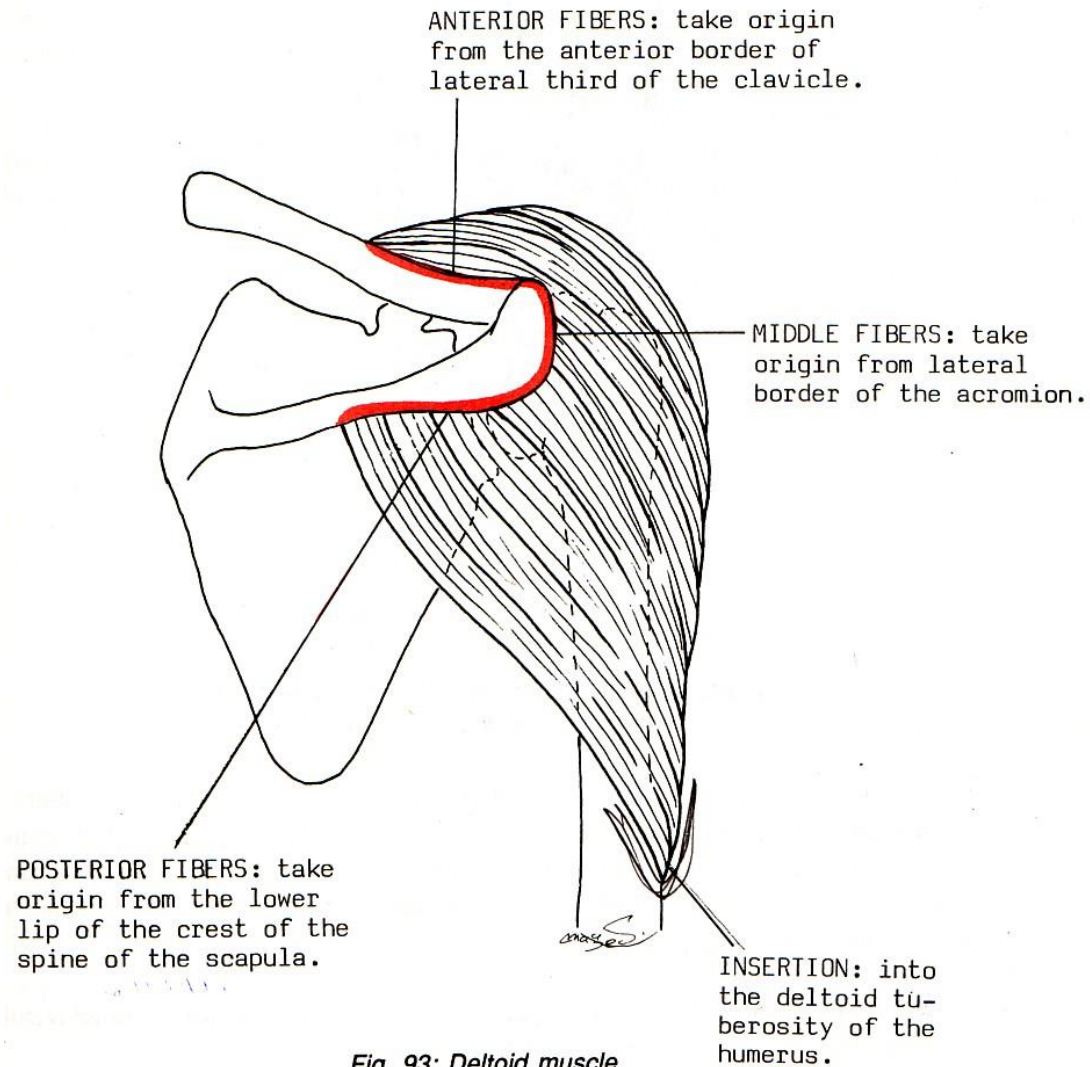


Fig. 93: Deltoid muscle.



# Rotator Cuff

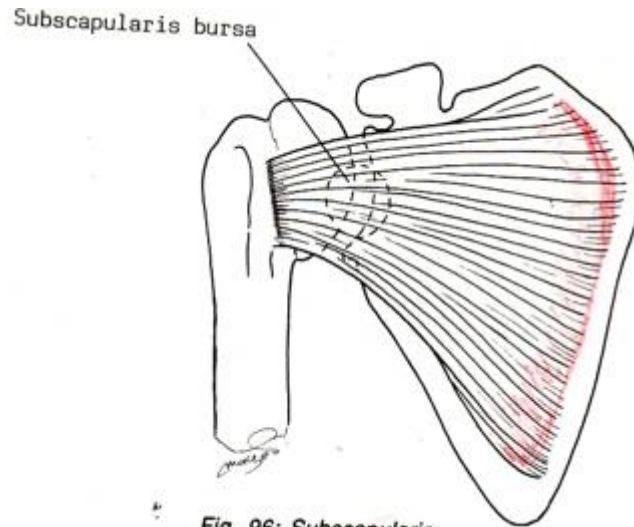


Fig. 96: Subscapularis.

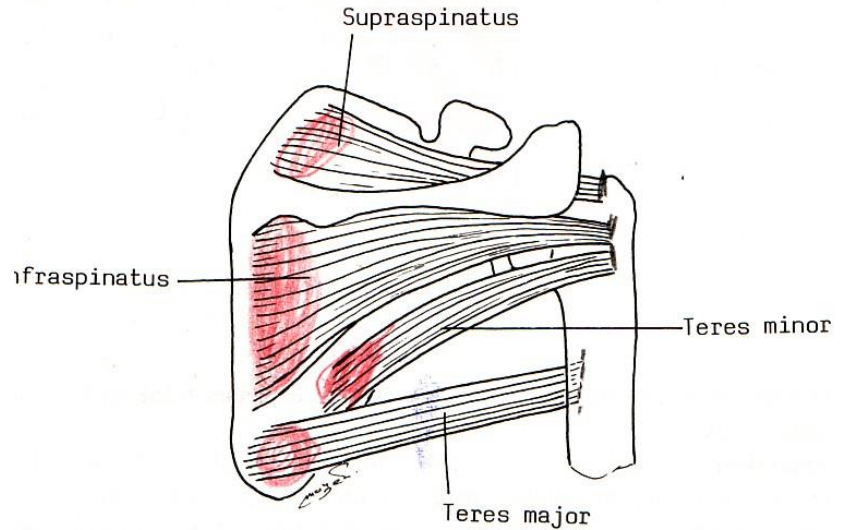


Fig. 98; Dorsal scapular muscles.

- The SITS muscles contribute to the formation of the **rotator cuff**, which both rotates the humeral head (**abducting and medially and laterally rotating the humerus**) and holds it firmly against the shallow socket of the glenoid cavity, increasing the integrity of the glenohumeral joint capsule.
- The cuff is deficient inferiorly and this is the site of potential weakness.

# Movements Of Shoulder Joint

## □ FLEXION:

- Anterior fibers of deltoid
- Pectoralis major
- Coracobrachialis (muscle of arm)
- Short head of biceps brachii (muscle of arm)

## □ EXTENSION:

- Posterior fibers of deltoid
- Latissimus dorsi
- Teres major

## □ ABDUCTION:

1. From 0° - 15°:  
Supraspinatus
2. From 15° - 90 °:  
Middle fibers of deltoid

## □ ADDUCTION:

1. Pectoralis major
2. Latissimus dorsi
3. Teres major



# Cont.

## □ MEDIAL ROTATION:

1. **Pectoralis major**
2. **Latissimus dorsi**
3. **Teres major**
4. **Anterior fibers of deltoid**
5. **Subscapularis**

## □ LATERAL ROTATION:

1. **Posterior fibers of deltoid**
2. **Infraspinatus**
3. **Teres minor**

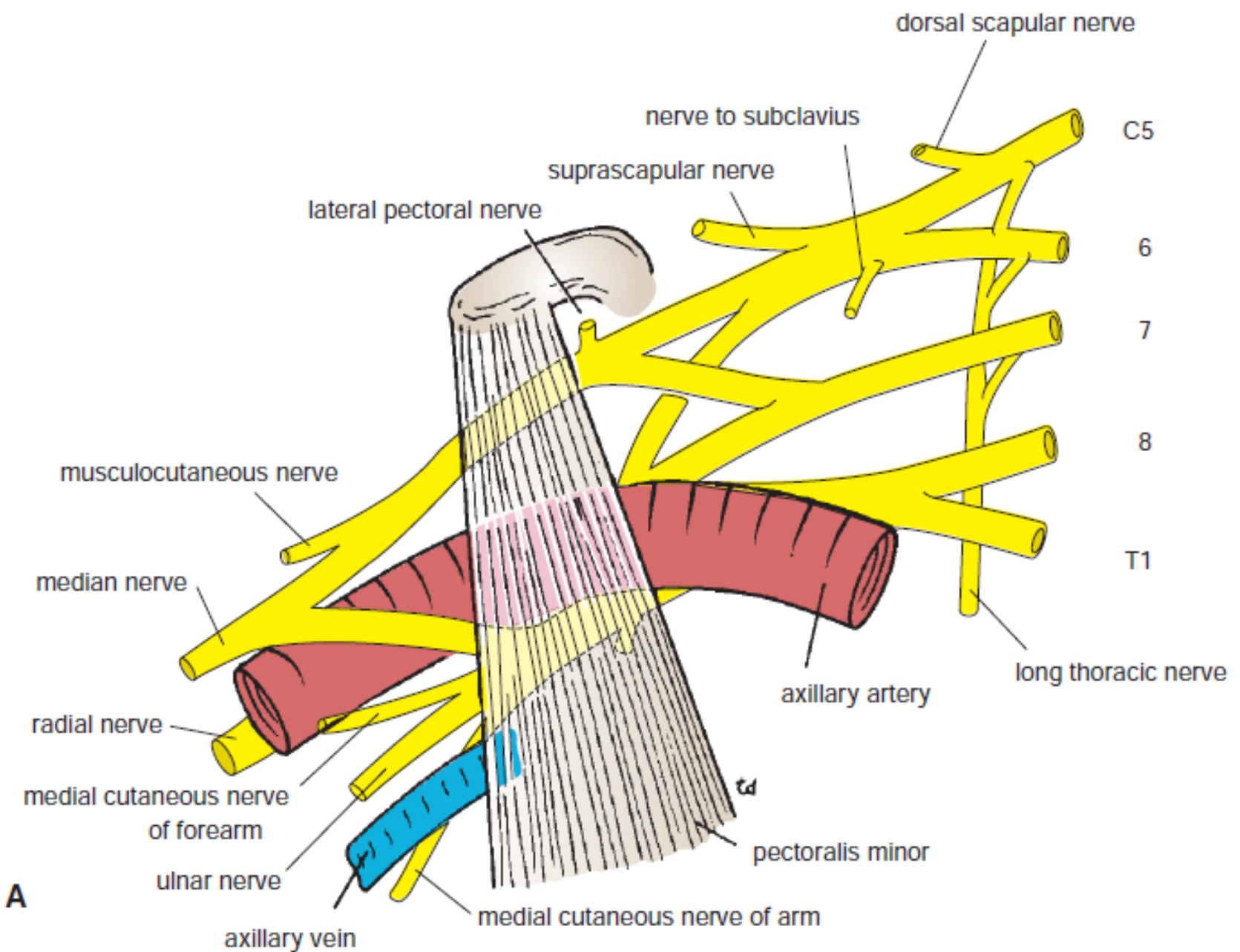
# Assignment?????

---

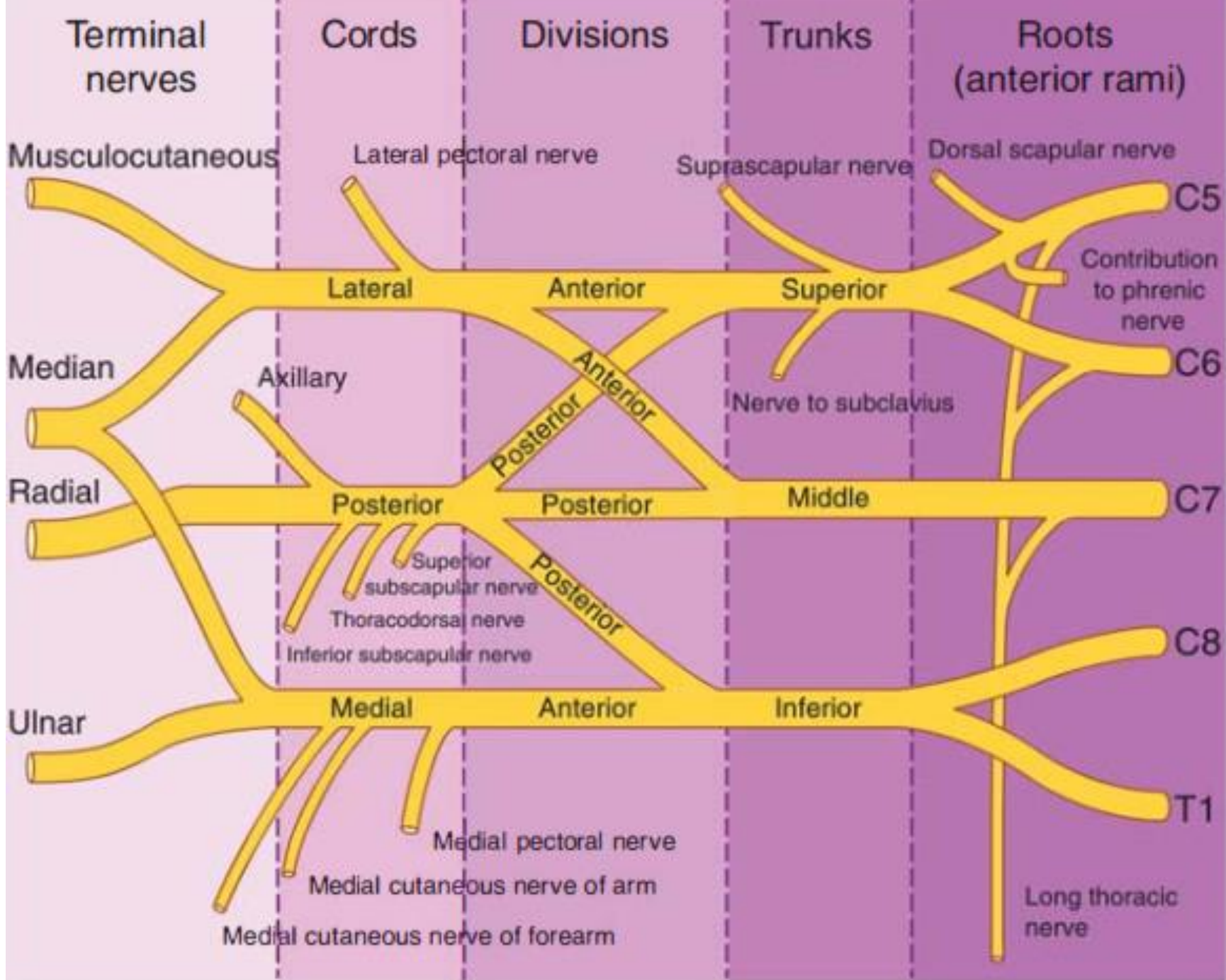
- Axilla
  - Boundary
  - Contents

# Brachial Plexus

- Brachial Plexus is a network of nerves that present at the root of the neck to enter the upper limb
- Brachial Plexus is present in the posterior triangle of the neck & axilla
- It is formed by the union of the anterior Rami of the ***Cervical 5th, 6th, 7th & 8th and the 1st thoracic spinal nerve.***
  - The roots of C5 & C6 unite to form Upper trunk
  - The root of C7 continues as the Middle trunk
  - The roots of C8 & T1 unite to form Lower trunk

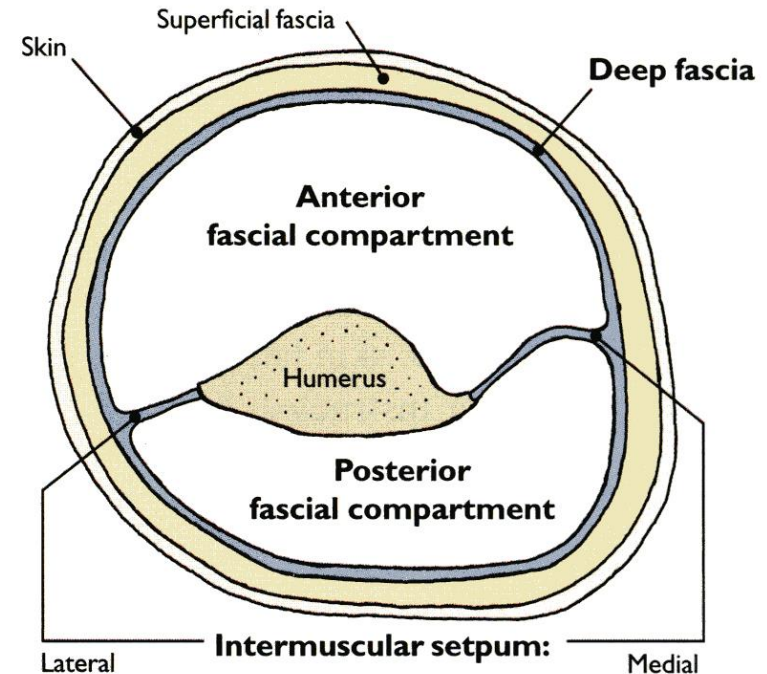


**A**



# Muscles of Arm

- The upper arm is enclosed in a **sheath of deep fascia**.
- **Two fascial septa**, one on the medial side and one on the lateral side, extend from this sheath and **are attached to the medial and lateral supracondylar ridges of the humerus, respectively**.
- By this means, the upper arm is divided into an **anterior** and a **posterior fascial compartment**, each having its **muscles, nerves, and arteries**.
- The chief action of both groups is at the elbow joint, but some muscles also act at the **glenohumeral joint**.





# Cont.

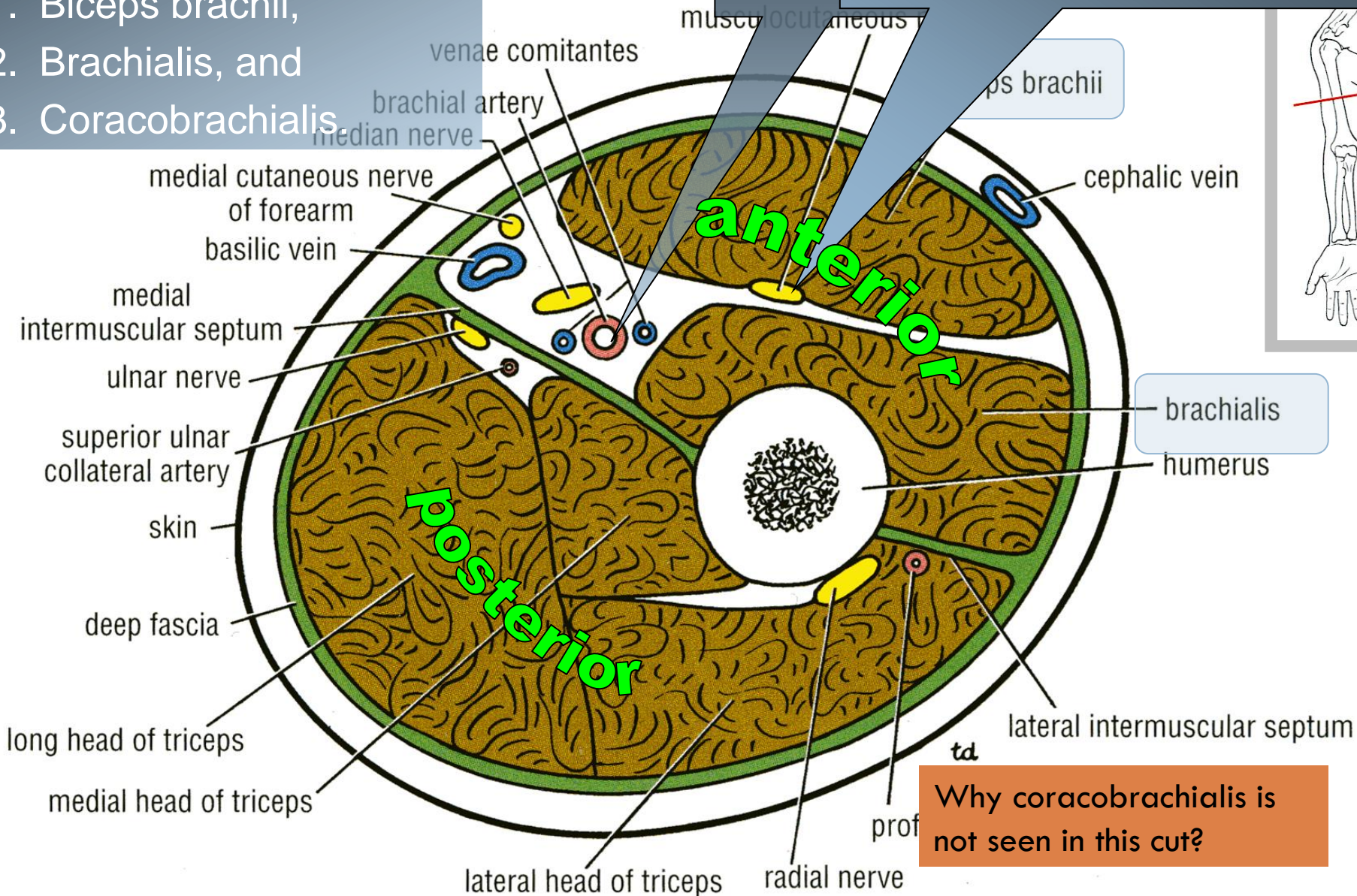
- **Anterior (flexor) compartment**
  - biceps brachii, brachialis, and coracobrachialis
  - supplied by **the musculocutaneous nerve,**
  - twice as strong as the extensors
  - we are better pullers than pushers
- **Posterior (extensor) compartment:**
  - triceps brachii, anconeus
  - **supplied by the radial nerve.**
  - particularly important for raising oneself out of a chair and for wheelchair activity.
- *Therefore, conditioning of the triceps is of particular importance in elderly or disabled persons.*

# CONTENTS

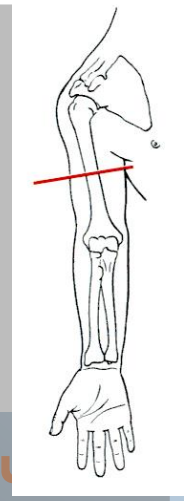
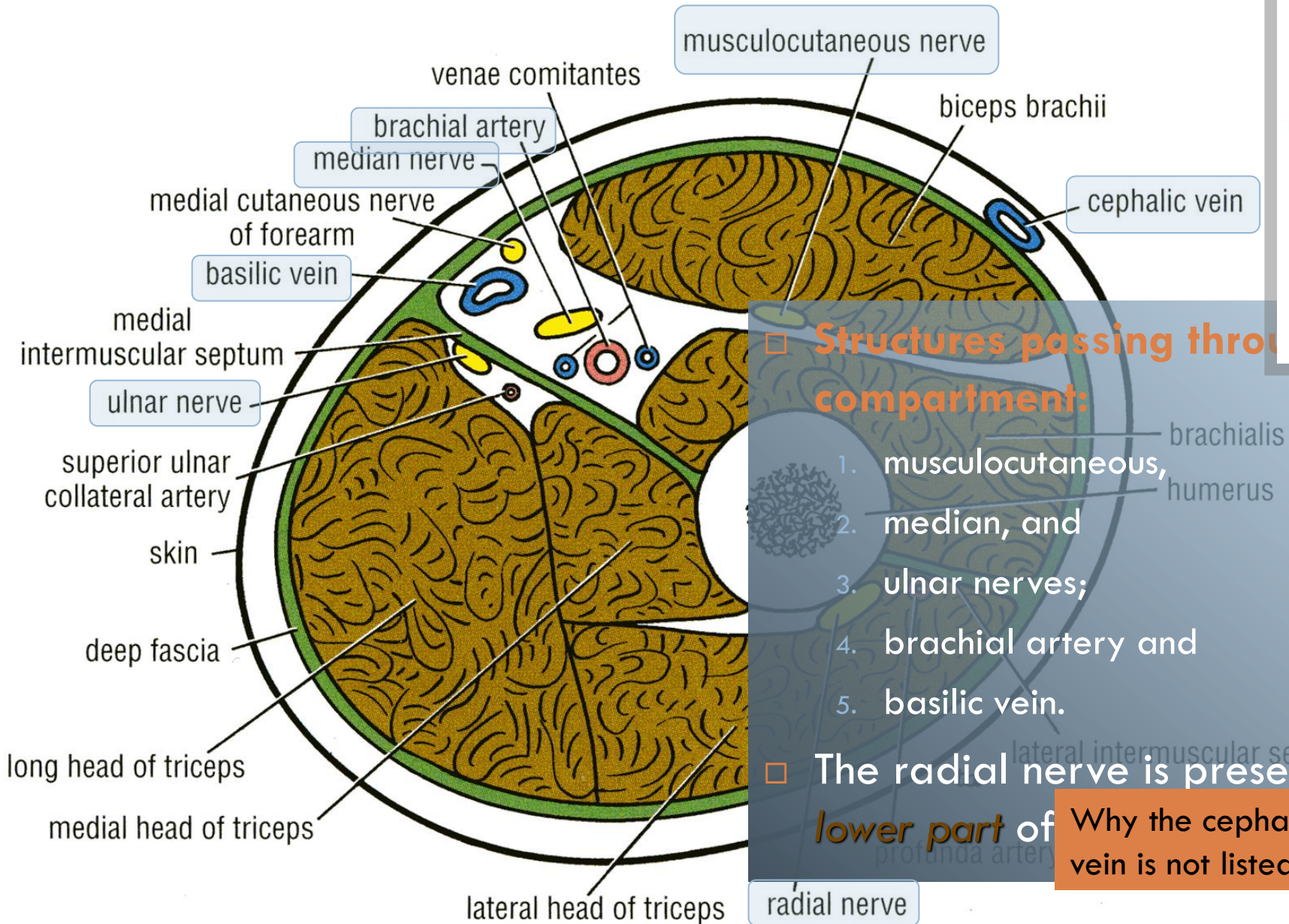
## Muscles:

1. Biceps brachii,
2. Brachialis, and
3. Coracobrachialis.

Blood supply: Brachial artery  
Nerve supply to the muscles: Musculocutaneous nerve.





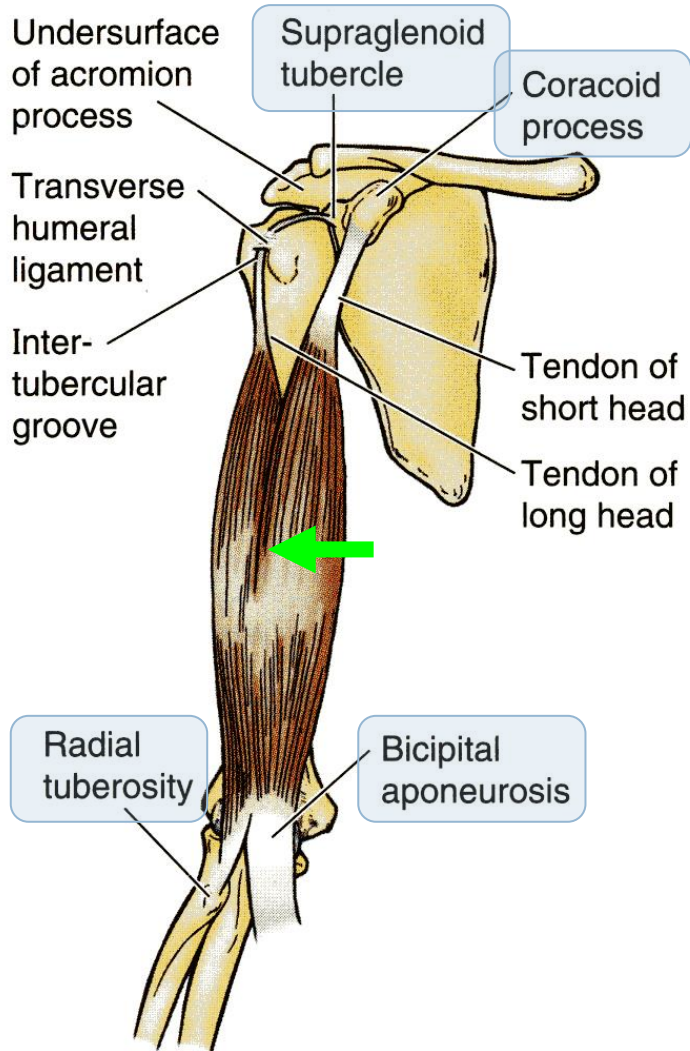


Structures passing through the compartment:
 

1. musculocutaneous,
2. median, and
3. ulnar nerves;
4. brachial artery and
5. basilic vein.

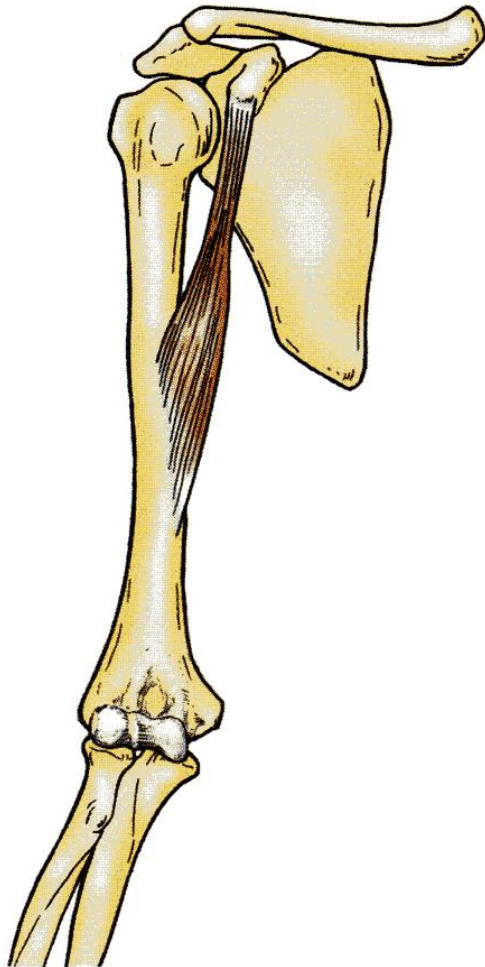
The radial nerve is present in the lower part of the compartment. Why the cephalic vein is not listed?

# BICEPS BRACHII



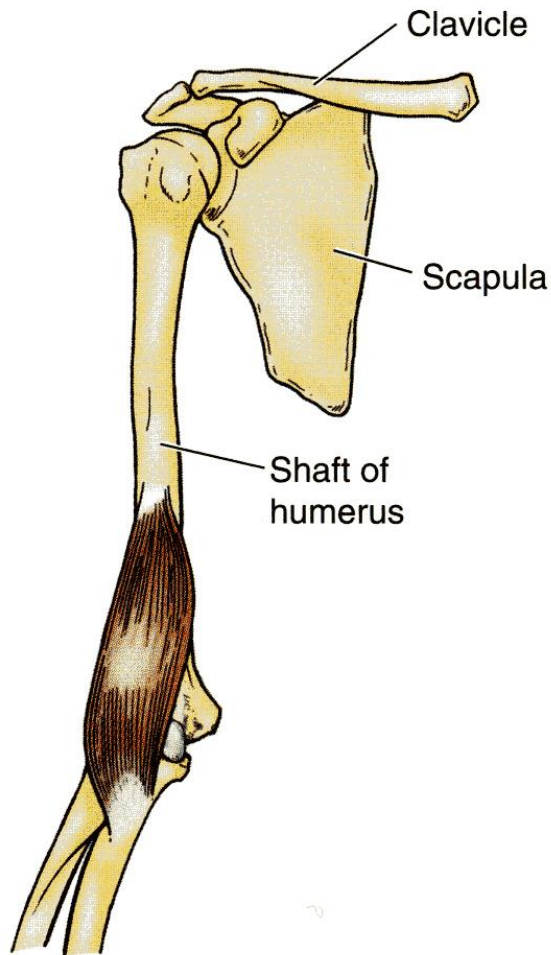
- **Origin:**
  - The long head from the supraglenoid tubercle of the scapula;
  - the short head from the tip of the coracoid process of the scapula.
- **Insertion:**
  - Into the posterior part of the tuberosity of the radius and, by an aponeurotic band called the bicipital aponeurosis, into the deep fascia on the medial aspect of the forearm.
  - The aponeurosis protects underlying structures present in the cubital fossa.
- **Nerve supply:**
  - Musculocutaneous nerve.
- **Action:**
  - The biceps is a powerful flexor of the elbow joint and a weak flexor of the shoulder joint.
  - The biceps is also a strong supinator of the forearm.

# Coracobrachialis



- ❑ **Origin:** From the tip of the coracoid process.
- ❑ **Insertion:** Into the middle of the medial side of the shaft of the humerus.
- ❑ **Nerve supply:** Musculocutaneous nerve.
- ❑ **Action:** It flexes the arm and is also a weak adductor.

# Brachialis

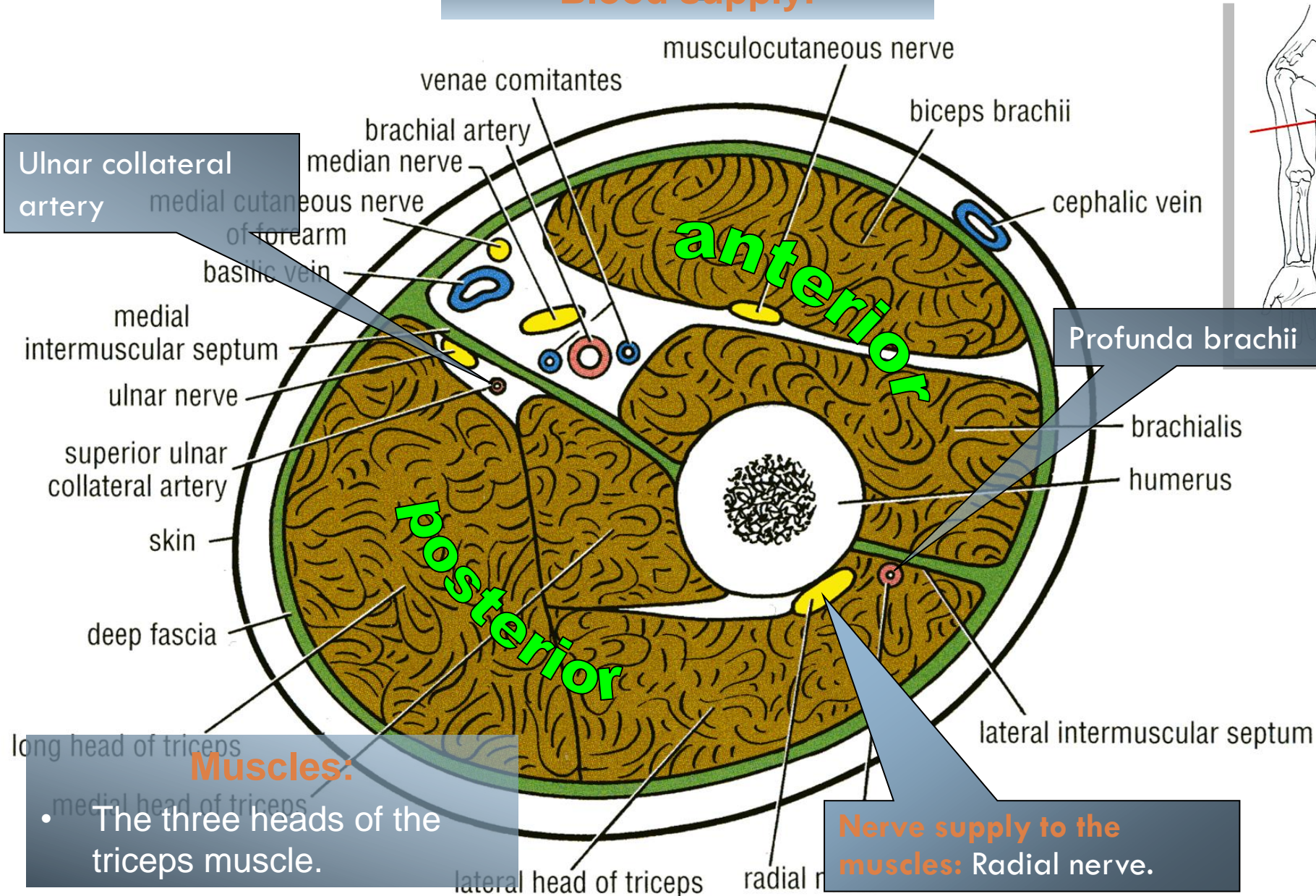


- **Origin:** From the front of the lower half of the humerus.
- **Insertion:** Into the anterior surface of the coronoid process of the ulna.
- **Nerve supply:** **Musculocutaneous nerve.**
  - A small part of the muscle that arises behind the deltoid tuberosity, and is therefore located in the posterior compartment, is supplied by the **radial nerve.**
- **Action:** It is a strong flexor of the elbow joint.



# Posterior Fascial Compartment Of The

**Blood supply:**



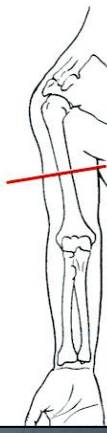**Ulnar collateral artery**

**Profunda brachii**

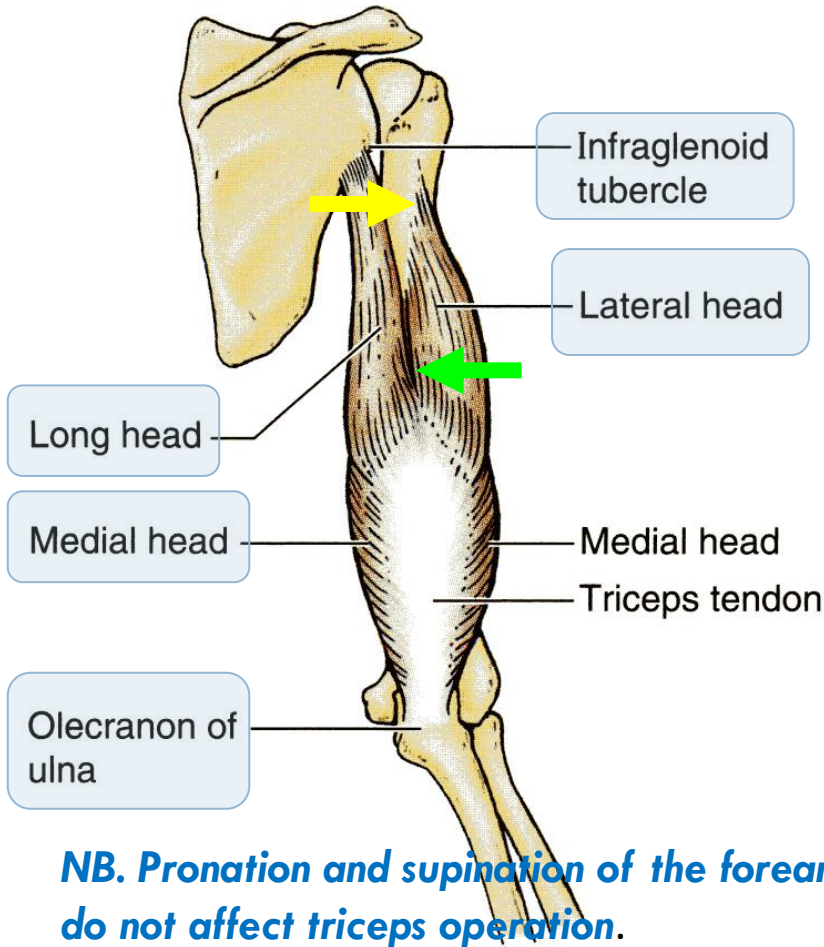
**Muscles:**

- The three heads of the triceps muscle.

**Nerve supply to the muscles:** Radial nerve.



# TRICEPS

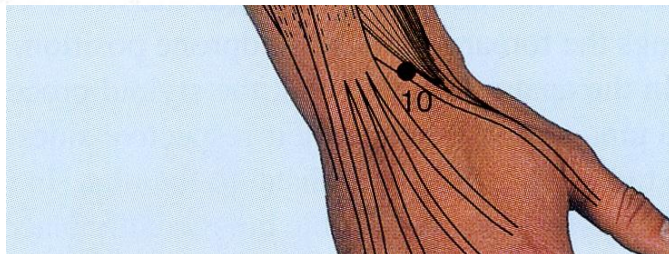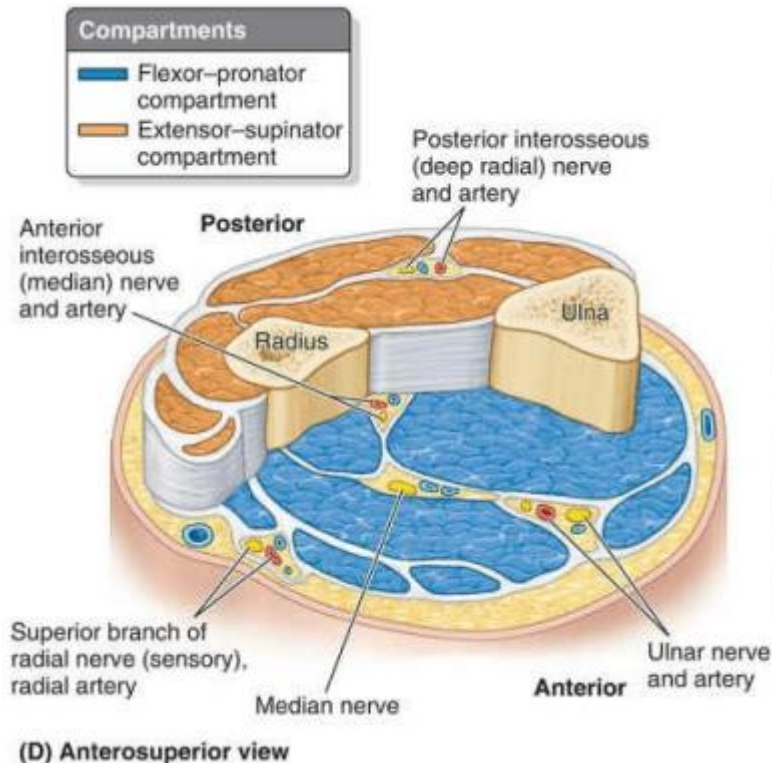


**NB. Pronation and supination of the forearm do not affect triceps operation.**

- The triceps is a large muscle that forms the greater part of the substance of the back of the arm.
- **Origin:**
- **Long head** from the infraglenoid tubercle of the scapula; **least active head.**
- **lateral head** from the upper half of the posterior surface of the shaft of the humerus **above the spiral groove; the strongest but is it recruited into activity primarily against resistance**
- **medial head** from the posterior surface of the lower half of the shaft of the humerus **below the spiral groove. workhorse of forearm extension**
- **Insertion:** The common tendon is inserted into the upper surface of the **olecranon** process of the ulna.
- **Nerve supply:** Radial nerve.
- **Action:** This muscle is a **strong extensor** of the elbow joint.



# Fascial Compartments of the Forearm



- The forearm is enclosed in a sheath of deep fascia, which is attached to the posterior border of the ulna
- This **fascial sheath**, together with the **interosseous membrane & fibrous intermuscular septa**, divides the forearm into several compartments, each having its own muscles, nerves, and blood supply.
- **The flexors and pronators of the forearm are in the anterior compartment** and are served mainly by **the median nerve**; the one and a half exceptions are innervated by **the ulnar nerve**.
- **The extensors and supinators of the forearm are in the posterior compartment** and are all served by **the radial nerve (directly or by its deep branch)**.

# Flexor Group

## □ These muscles: 8

- Act on the elbow & wrist joints and those of the fingers.
- Form fleshy masses in the proximal part and become tendinous in the distal part of the forearm.
- Arranged in three groups:
  - **I-Superficial: 4**
    - **Pronator teres**(pronation & flexion of forearm )
    - **Flexor carpi radialis**
    - **Palmaris longus**
    - **Flexor carpi ulnaris**

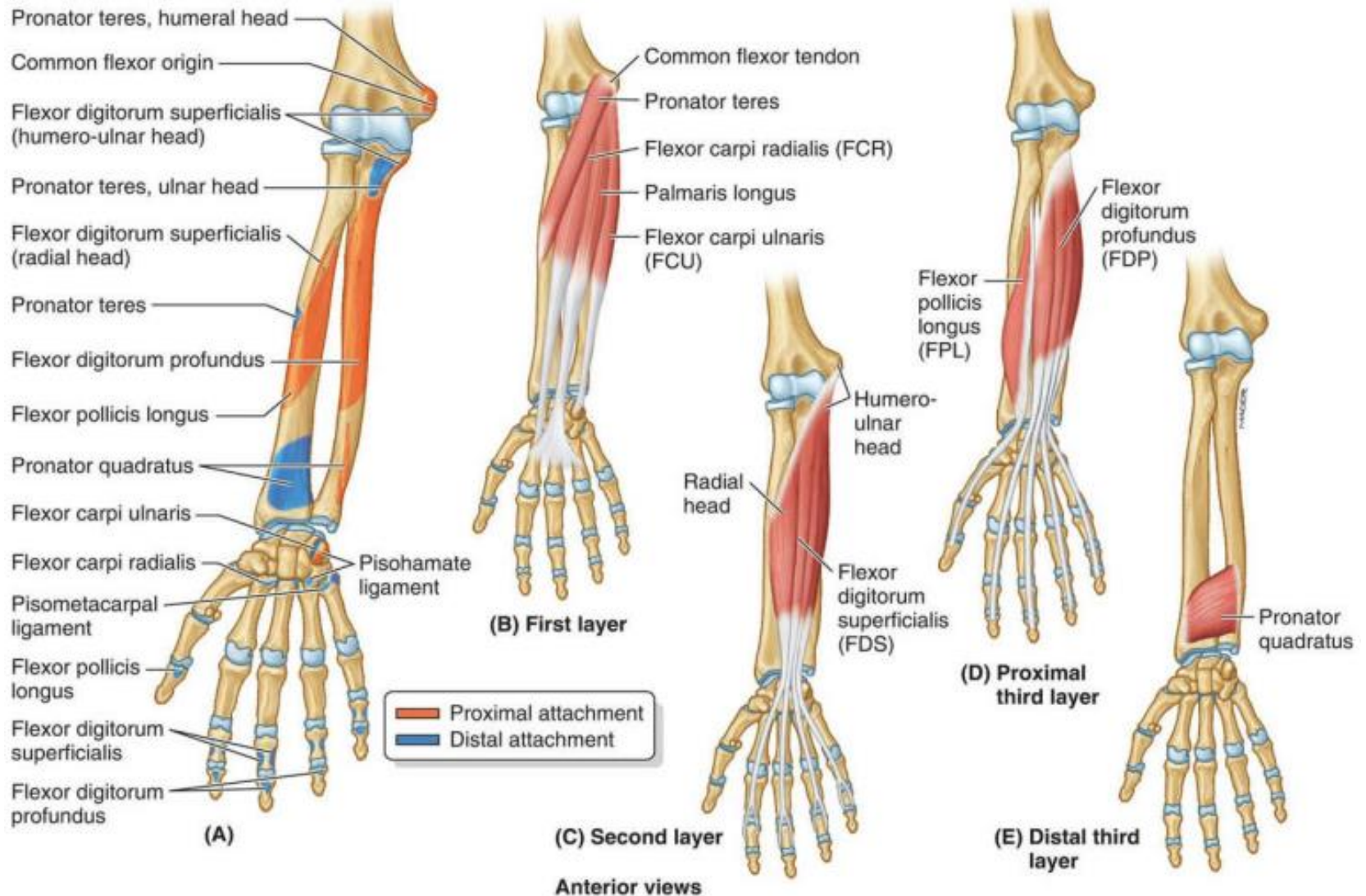
## ■ **II-Intermediate: 1**

- **Flexor digitorum superficialis**
- (Flexes middle and proximal phalanges of medial 4 fingers, and the hand)

## ■ **III- Deep: 3**

- **Flexor digitorum profundus**
- (Flexes middle and distal phalanges of medial four digits)
- **Flexor pollicis longus**
- (the only that flexes interphalangeal; metacarpophalangeal & carpometacarpal joints of thumb )
- **Pronator quadratus**
- (pronates forearm (prime mover), helps to hold the bones together)

# Flexor muscles of forearm



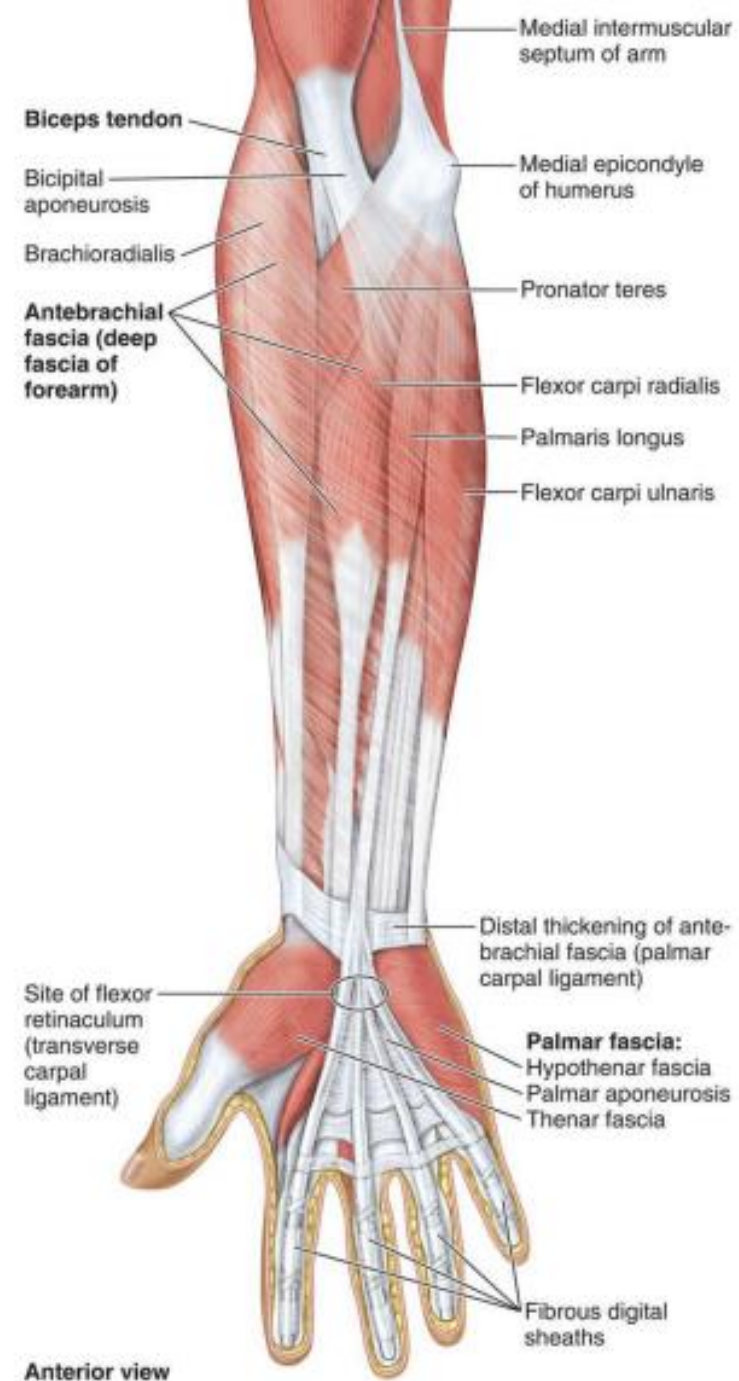# cont.

- **Functionally, the brachioradialis is a flexor of the forearm, but it is located in the posterior (posterolateral) or extensor compartment and is thus supplied by the radial nerve.**
- **Therefore, the brachioradialis is a major exception to the rule that**
  - ▣ **(1) the radial nerve supplies only extensor muscles and**
  - ▣ **(2) that all flexors lie in the anterior (flexor) compartment**



# Superficial Flexors:

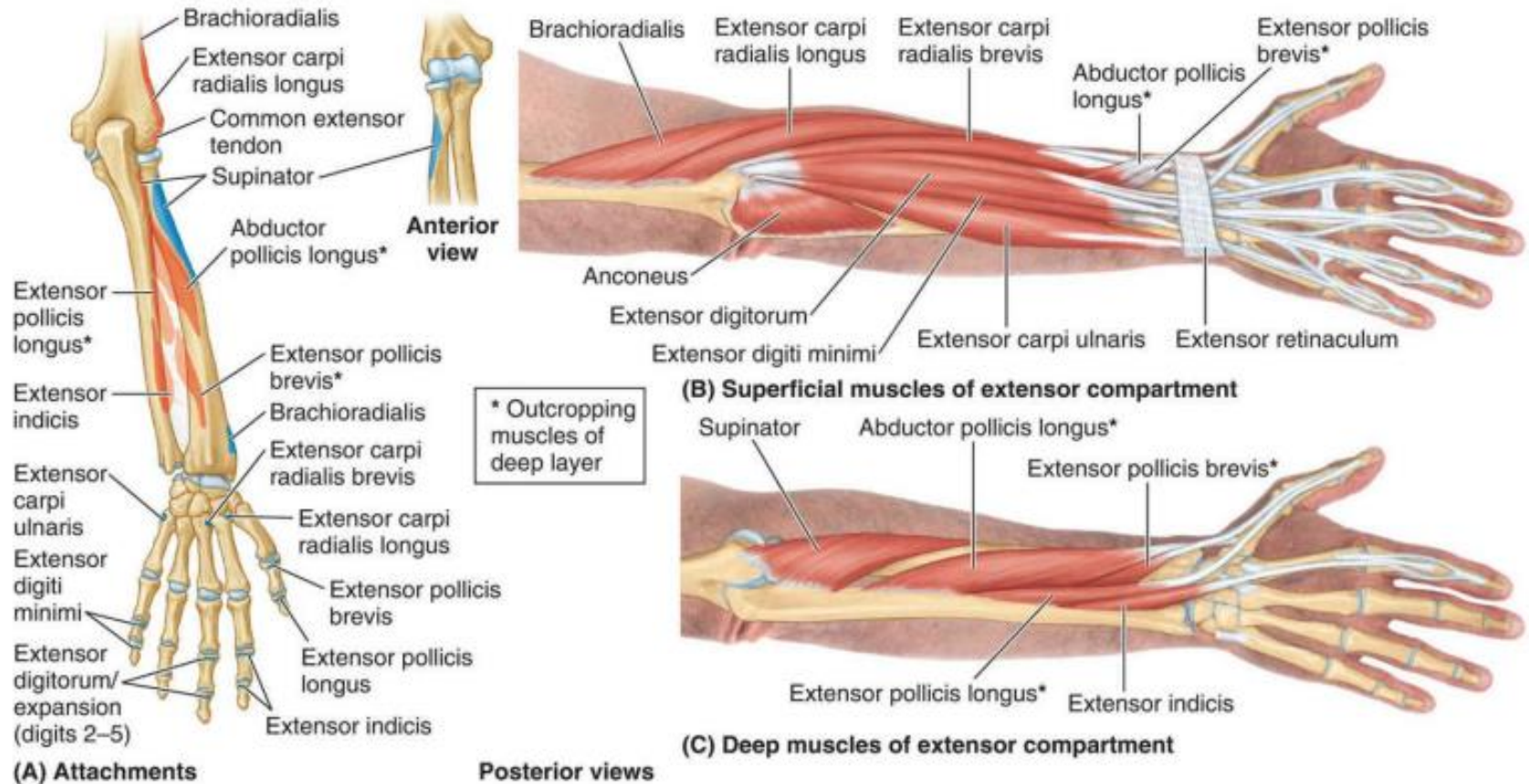
- They arise - more or less- from the common flexor origin (front of medial epicondyle).
- All are supplied by **median nerve** except one, **flexor carpi ulnaris**, FCU (ulnar).
- All cross the wrist joint except one, **pronator teres**, (PT).



# Posterior compartment: 3 groups

- Superficial group 6
  - **Brachioradialis???**
  - **Extensor carpi radialis brevis**
  - **Extensor carpi radialis longus**
  - **Extensor digitorum**
  - **Extensor digiti minimi**
  - **Extensor carpi ulnaris**
  - **Anconeus???**
- **Deep group 5 (3 to thumb + 1 to index + supinator).**
  - **Supinator.**
  - **Extensor indices.**
  - **Outcropping muscles of deep layer**
    - **Abductor pollicis longus.**
    - **Extensor pollicis brevis.**
    - **Extensor pollicis longus.**

# Extensor muscles of forearm

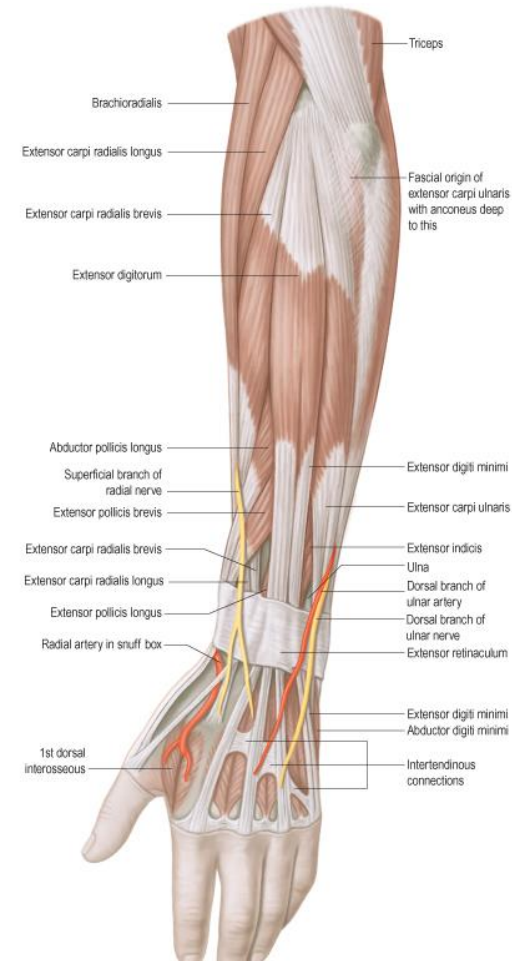


# Cont.

- **The extensor muscles are in the posterior (extensor–supinator) compartment of the forearm, and all of them are innervated by branches of the radial nerve.**
- **These muscles can be organized physiologically into three functional groups:**
  - **Muscles that extend and abduct or adduct the hand at the wrist joint (extensor carpi radialis longus, extensor carpi radialis brevis, and extensor carpi ulnaris).**
    - **Innervated by deep branch of radial nerve except ECRL by radial itself**
  - **Muscles that extend the medial four fingers (extensor digitorum, extensor indicis, and extensor digiti minimi).**
    - **Innervated by deep branch of radial nerve except EI by posterior interosseous nerve**
  - **Muscles that extend or abduct the thumb (abductor pollicis longus, extensor pollicis brevis, and extensor pollicis longus).**
    - **Innervated by posterior interosseous nerve**

# Superficial extensors

- All arises from the **common extensor origin, (front of lateral epicondyle) of the humerus, EXCEPT, 2 (BR & ECRL).**
- All cross the wrist **EXCEPT, one, brachioradialis.**
- All supplied by **deep branch of radial nerve, EXCEPT ABE**
- **A, anconeus**
- **B, Brachioradialis**
- **E, Extensor carpi radialis longus**
- **These 3 muscles are supplied by the radial nerve itself**

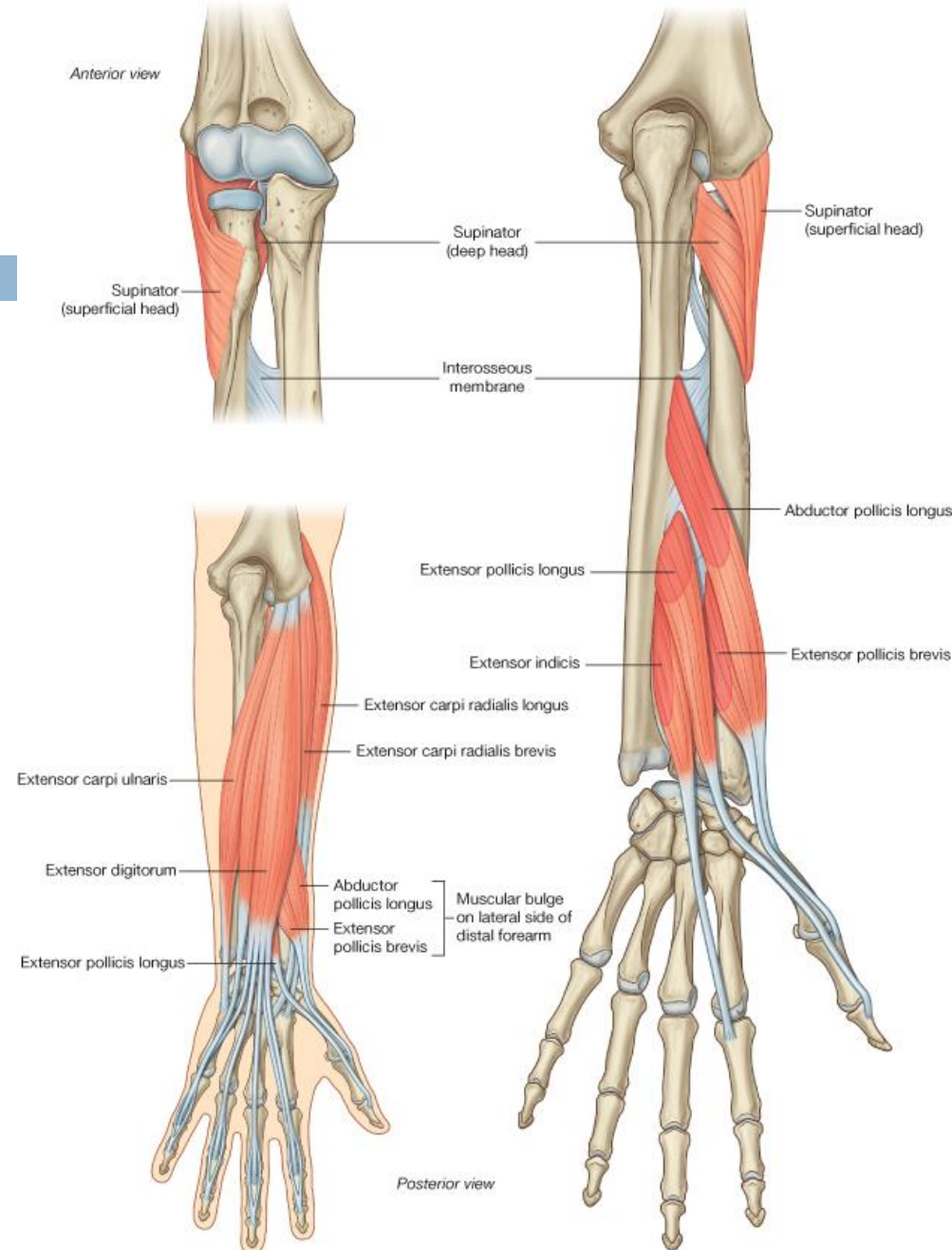


# II- Deep group:

## □ 5 muscles

- Abductor pollicis longus, (APL).
- Extensor pollicis brevis, (EPB).
- Extensor pollicis longus, (EPL).
- Extensor indicis (EI).
- Supinator.

- All back muscles of forearm are supplied by posterior interosseous nerve



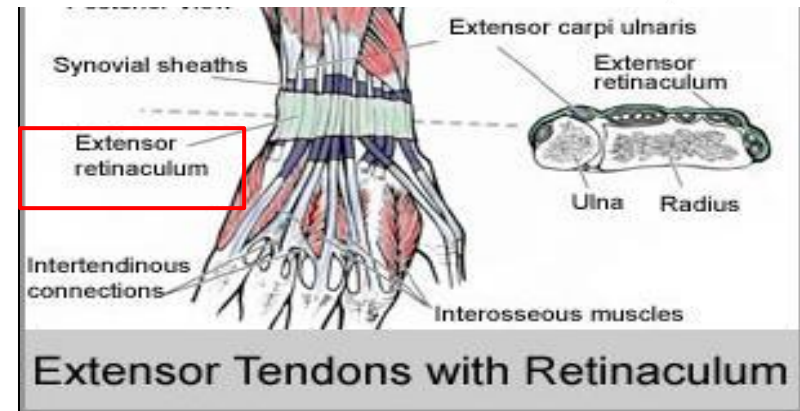
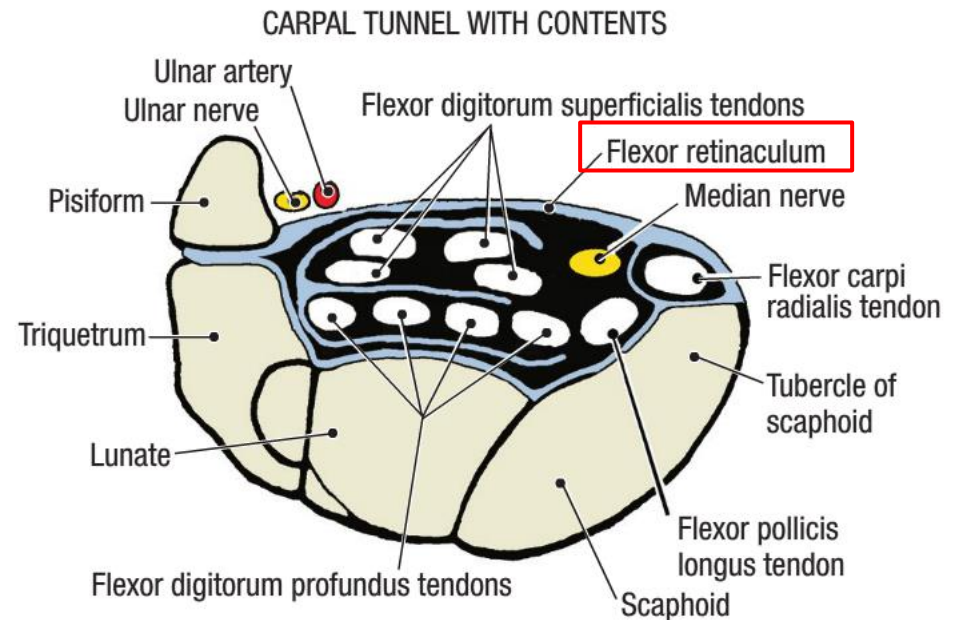


# Hand and wrist

- The *hand* is one of the most useful structures in the human body
  - ➔ **injuries to the hand should be taken care of carefully & immediately.**
  - ➔ **surgeon must know anatomy of hand exceptionally well.**
- Many of the tendons in forearm continue into the hand: some inserted into *carpal bones*, others into *metacarpals & phalanges*.
- Where tendons cross the wrist to enter the hand, they are held by *retaining bands*, localized thickenings of deep fascia.
  - ➔ These retaining bands are called ***retinacula***:
    - ➔ **an extensor retinaculum on dorsum of the wrist, & a flexor retinaculum on the anterior aspect of the hand.**

# Retinacula

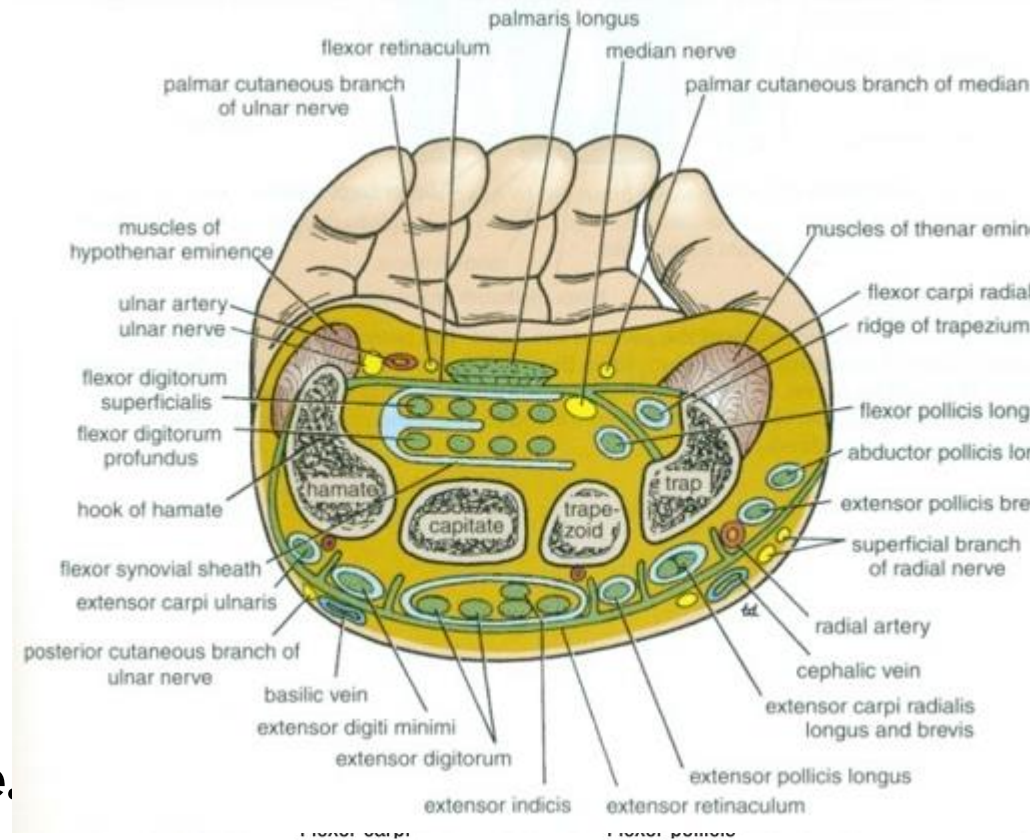
- **Flexor & Extensor Retinacula:**
- **Bands of Deep Fascia in front & back of Wrist**
- **Function:**
  - They Hold the long flexor and extensor tendons at the wrist in position.
- **Attachments:**
  - **Medially:** Both retinacula attached to Pisiform & Hook of Hamate.
  - **Laterally:**
  - Flexor Retinaculum attached to Tubercle of Scaphoid & Trapezium.
  - Extensor Retinaculum attached to Distal end of Radius



# Structures Superficial to Flexor Retinaculum

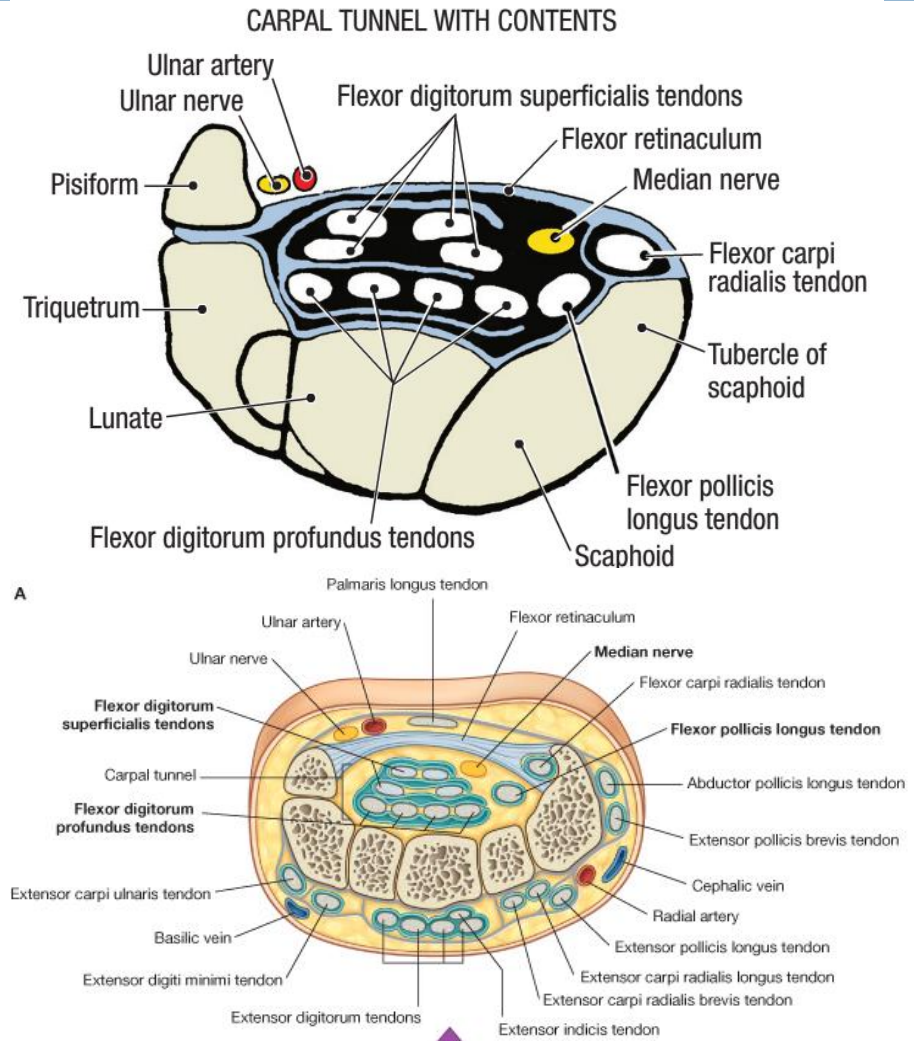
## From Medial to Lateral

1. **Tendon of Flexor carpi ulnaris.**
2. **Ulnar nerve.**
3. **Ulnar artery.**
4. **Palmar cutaneous branch of ulnar nerve.**
5. **Tendon of Palmaris longus.**
6. **Palmar cutaneous branch of median nerve.**



# Carpal Tunnel

- **Formed from Concave anterior surface of the Carpus covered by Flexor Retinaculum**
- **Contents**
- **From Medial to Lateral**
  - **Tendons of flexor digitorum superficialis & profundus**
  - **Median nerve**
  - **Flexor Pollicis Longus (Flexor carpi radialis)**



# Carpal Tunnel Syndrome

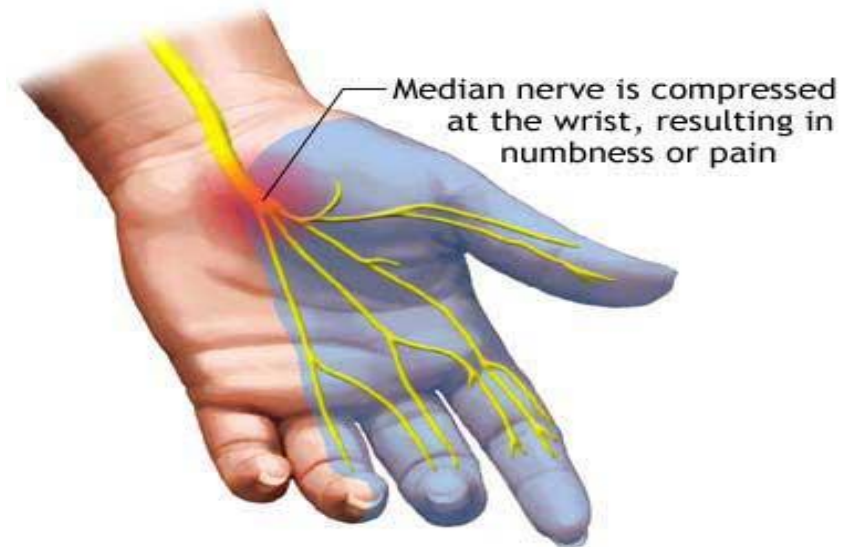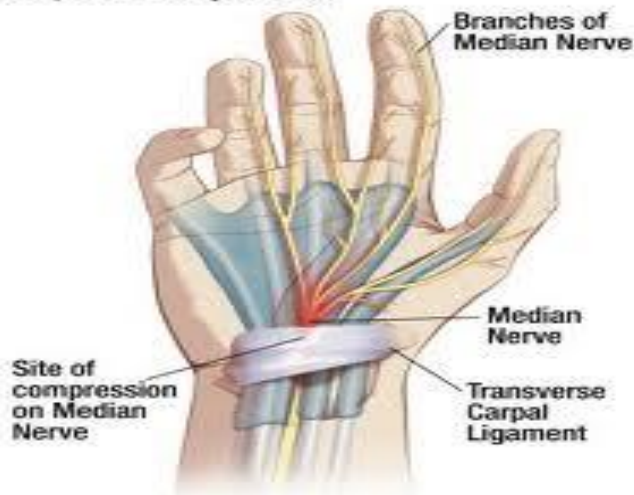
## □ Causes :

- **Compression of the median nerve within the carpal tunnel**

## □ Manifestations:

- **1. Burning pain (pins and needles ) in the lateral three and half fingers.**
  - **No paresthesia over the thenar eminence?**
- **2. Weakness or atrophy of the thenar muscles (*Ape Hand*).**
  - **Inability to Oppose the thumb.**

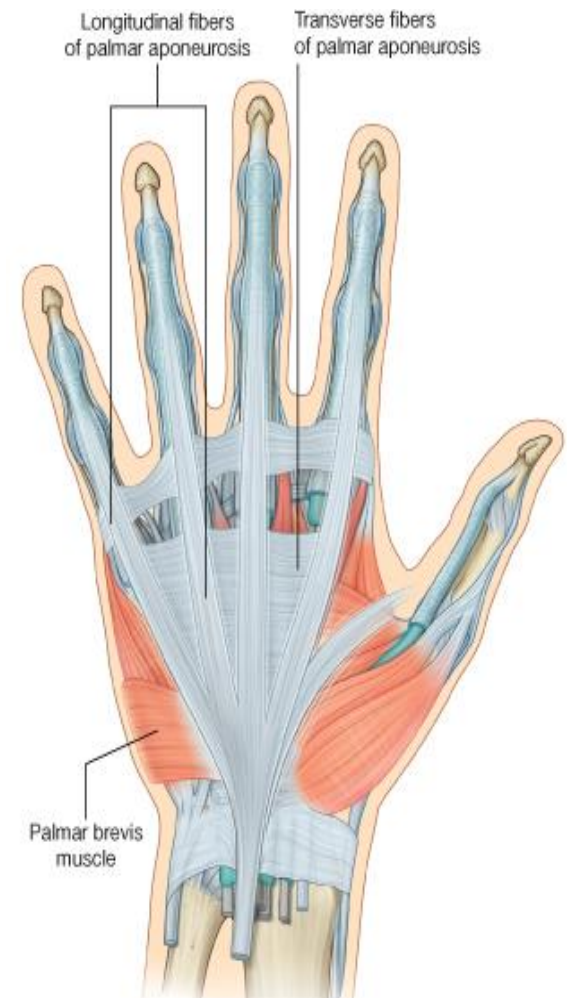
Carpal Tunnel Syndrome





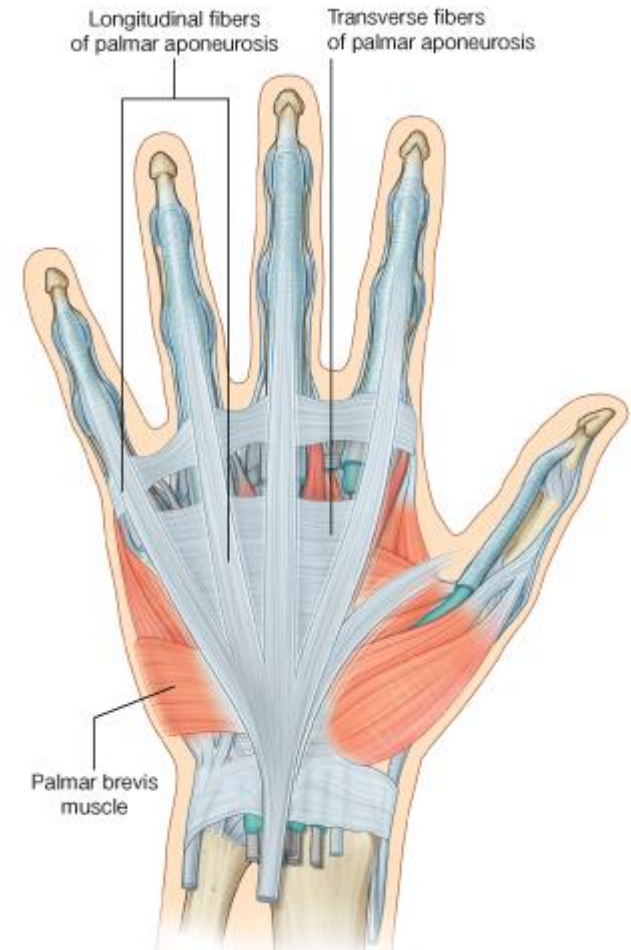
# Palmar Aponeurosis

- **It is thickened deep fascia.**
- **Triangular in shape , occupies the central area of the palm.**
- **The Apex :** attached to the distal border of flexor retinaculum and receives the insertion of palmaris longus tendon.
- **The Base :** divides at the bases of the fingers into four slips that pass into the fingers.
- **The Medial a& Lateral borders:** Continuous with the thinner deep fascia covering the Hypothenar & Thinner eminences.
- **Functions :**
  - 1. Gives firm attachment to the overlying skin and improves the grip.
  - 2. Protects the underlying tendons, vessels & nerves.



# Palm of the Hand: Compartments

- The palm contains a **central compartment**, behind the palmar aponeurosis, a **thenar** & a **hypothenar compartment**.
- **central compartment** contains most of the **flexor tendons, nerves & vessels** of the hand.
- tendon of **palmaris longus** is inserted into the **palmar aponeurosis**.
- **Septa** of **palmar aponeurosis** extend to fingers.
- A **palmar interosseous fascia** separates central compartment into a **superficial & deep component**.
- **deep component** contains the **interossei muscles** (b/n the metacarpals) & **adductor pollicis**.
- Numerous **fibrous bands** attach the **superficial fascia** to **deep fascia**, limiting **mobility of skin** of the **palm**.

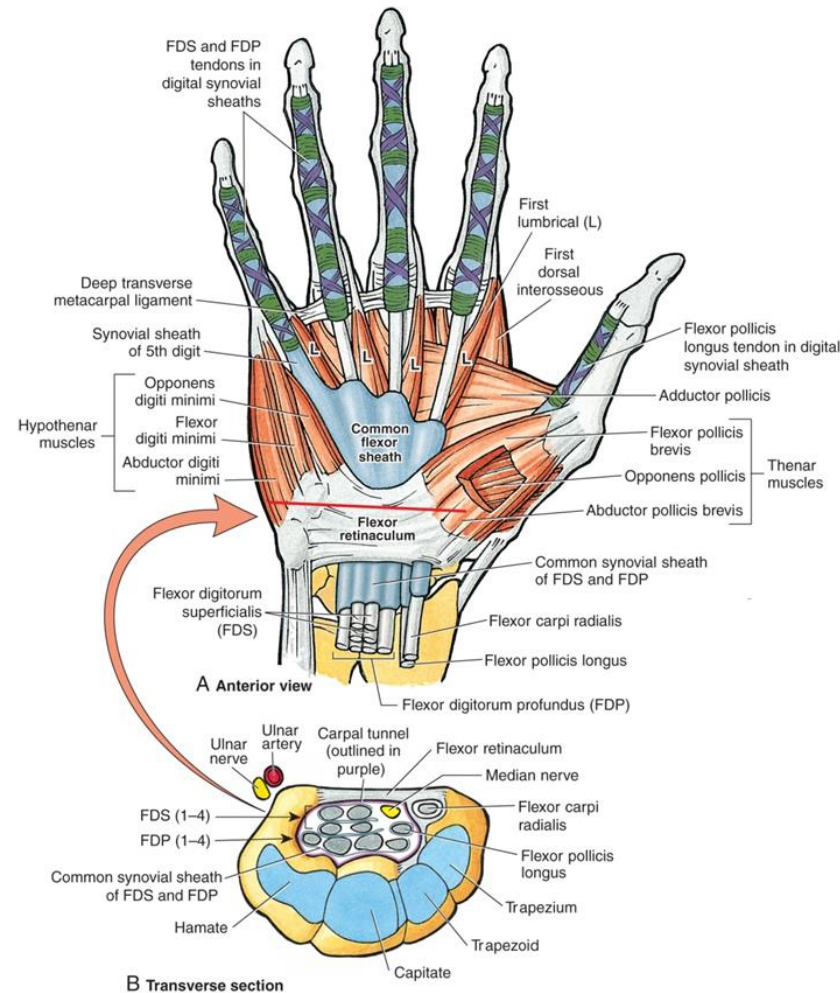


# Muscles & Tendons of the Hand

- **Extrinsic muscles** are those entering from the forearm → concerned with grip.
- **Intrinsic muscles:** small muscles found on palmar & dorsal compartments of the hand → control fine movements of the finger & thumb.
- **The intrinsic muscles** of the hand can be arranged into:
  - **Short muscles of thumb and little finger (thenar & hypothenar muscles)**
  - **Lumbrical muscles**
  - **Interossei muscles**
  - **Adductor pollicis**

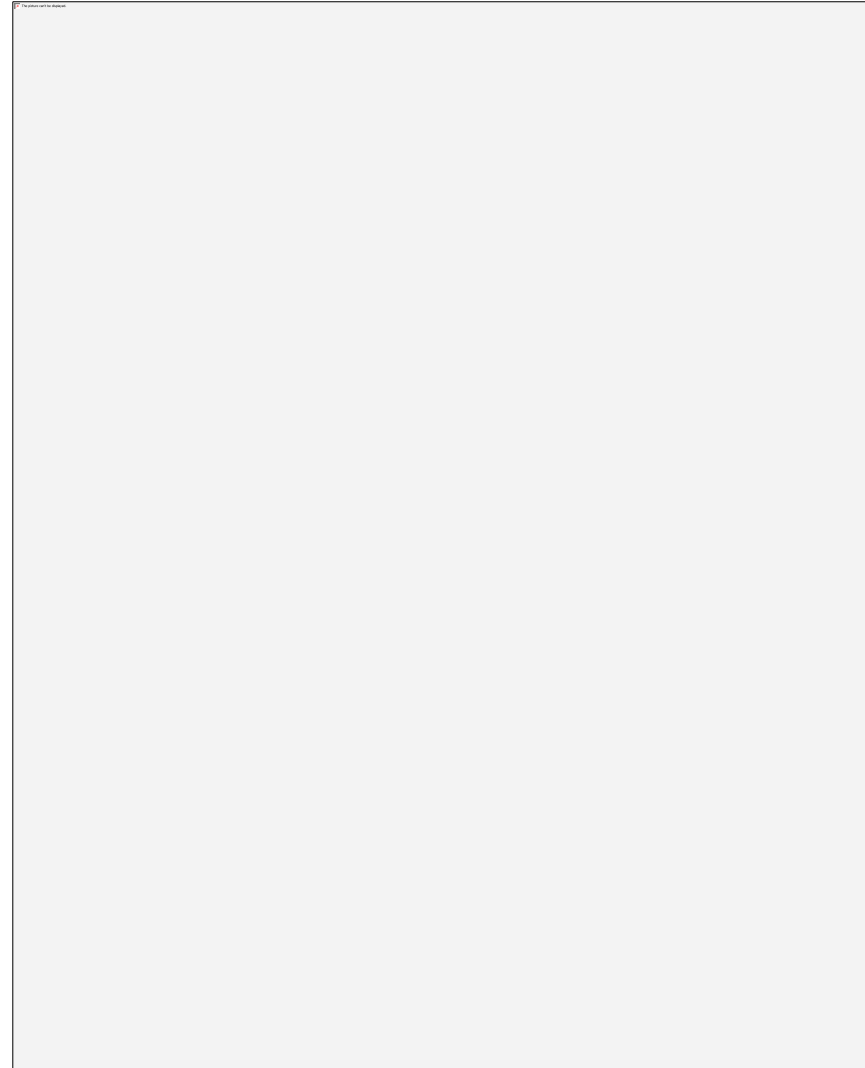
# Short muscles of thumb and little finger

- **Three muscles of thenar eminence: abductor pollicis brevis, flexor pollicis brevis, and opponens pollicis.**
  - ➔ **arise from the flexor retinaculum & insert into the thumb.**
  - ➔ **supplied by median nerve.**
- **Three muscles of the hypothenar eminence: abductor digiti minimi, flexor digiti minimi & opponens digiti minimi.**
  - ➔ **arise from flexor retinaculum & insert into little finger.**
  - ➔ **innervated by the ulnar nerve.**
- **These 2 groups of small muscles act on thumb & little finger, respectively.**
- **Also help to “cup” palm & thus assist in grip of a large object.**



# Lumbrical muscles

- Lumbrical muscles *arises*, on *lateral (radial) side*, from each of the 4 *profundus (FDP) tendons*
- Each runs along radial side of the *metacarpophalangeal joint* & inserts on the *extensor expansion* on the *dorsum* of the *first phalanx*.
- *flex* the *metacarpophalangeal joint* & *extend* the *interphalangeal joints*.





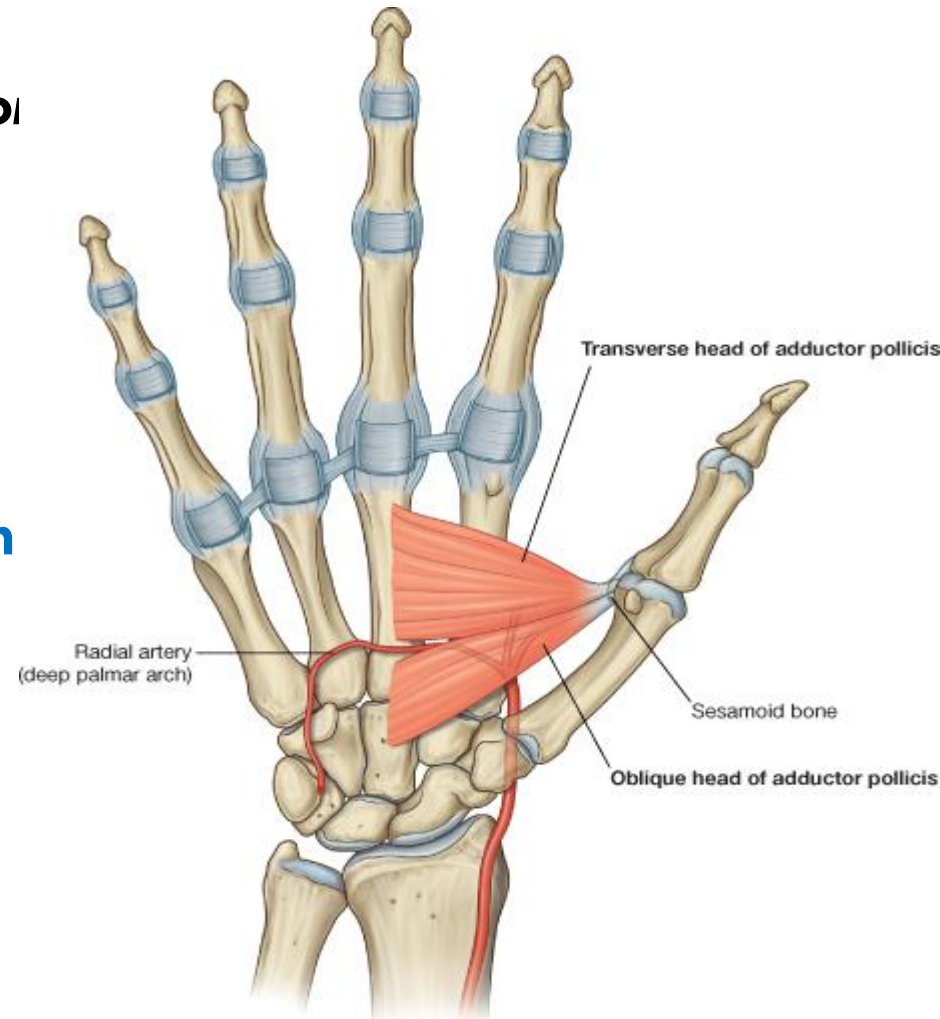
# Interossei muscles

- **Fill the spaces b/n metacarpals.; 3 or 4 palmar & 4 dorsal interossei (DIO)**
- **Like the lumbricals, DIO insert into the dorsal extensor expansions:**
  - **→ Hence, they flex metacarpophalangeal joints & extend interphalangeal joint,**
  - **→ In addition, palmar interossei adduct the fingers and the dorsal interossei abduct the fingers.**



# Adductor pollicis

- A triangular muscle, lies deep in the palm just anterior to the metacarpals.
- Arises from the 2nd & 3rd metacarpals & adjacent carpal bones.
- Fibers run laterally to the thumb.
- Adduct the thumb & aids in grip of the thumb.



# Arrangement of muscles on dorsum of hand

## 1. Extensor tendons:

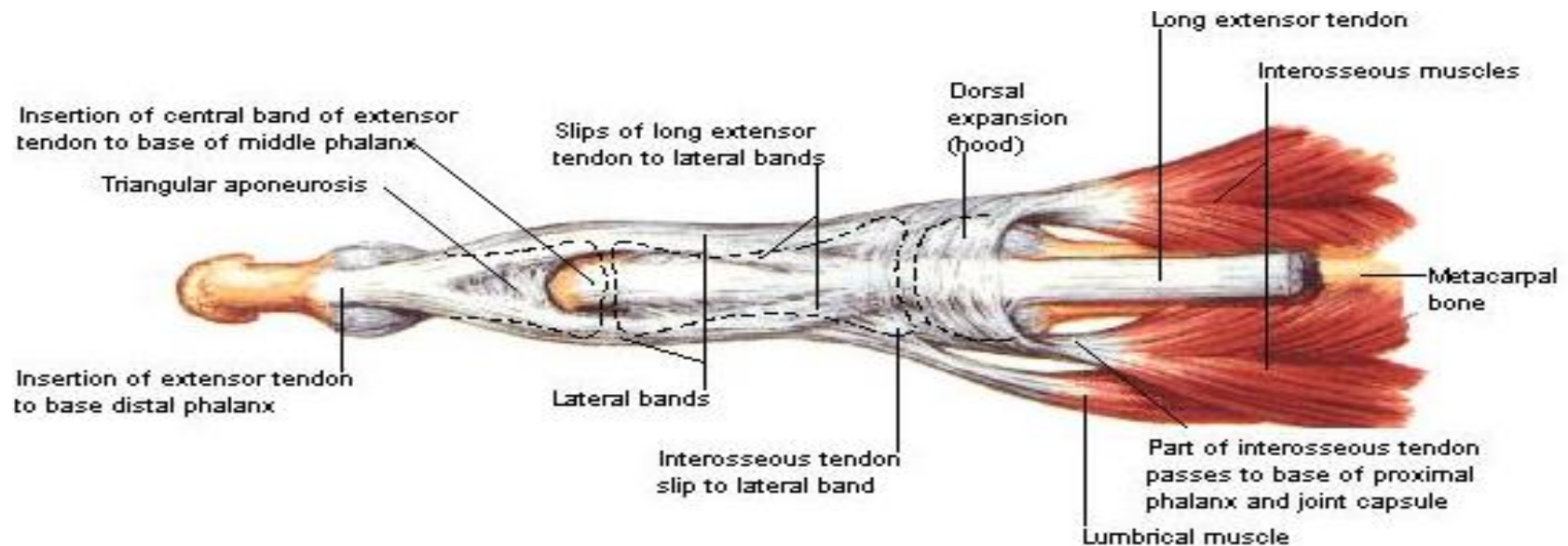
- have synovial sheaths where they pass deep to extensor retinaculum.
- are inserted into middle & distal phalanges by slips of tendons of extensor digitorum, which divide and reunite: → dorsal extensor expansions.  
→ **lumbricals & interossei inserted into these dorsal extensor expansions.**

## 2. The dorsal interossei:

- dorsal interossei can be felt b/n metacarpals: → deep b/n extensor tendons.
- are separated from muscles of palm by palmar interosseous fascia.


# Dorsal Extensor Expansion

- It is formed by the union of the tendons of : Extensor digitorum, Extensor indicis, extensor digiti minimi, palmar and dorsal interossei and lumbricals muscles.
- All these tendons unite to form one tendon which divides into 3 slips, a median one attached to middle phalanges and 2 lateral attached to the terminal phalanges.



# Nerves of the Hand

- **Median nerve**
  - supplies 3 thenar muscles & 2 lateral lumbricals.
- **Ulnar nerve**
  - supplies all the other muscles: 3 hypothenar muscles, medial-2 lumbricals, adductor pollicis, all interossei.
- **Radial nerve**
  - supplies no intrinsic muscles of the hand.
- **Note: All intrinsic muscles of hand are supplied by C8 or T1, whether thru median or ulnar nerves.**





# Nerve injury of the upper limb

- **Many deformities of the upper limb, particularly those resulting from nerve injuries, are readily interpreted anatomically.**

# Upper Lesions of Brachial Plexus (Erb-Duchenne Palsy)

- **Upper lesions of brachial plexus are usually the result of tearing the 5th & 6th roots of brachial plexus.**
- **This may occur in infants during a difficult delivery or in adults following a violent fall on the shoulder or a blow to the shoulder.**
- **The major nerves involved are:**
  - ▣ **suprascapular nerve (1)**
  - ▣ **musculocutaneous nerve (2)**
  - ▣ **Axillary (3)**
- **“waiter’s tip”**

# Lower brachial plexus lesions:

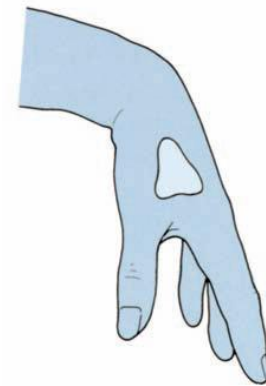
- **Injuries caused by excessive abduction of arm: as a result of someone clutching for an object when falling from a height.**
- **1<sup>st</sup> thoracic nerve (T1) is usually torn**
  - ➔ **fibers from T1 help form ulnar & median nn.**
  - ➔ **small muscles of hand (interossei & lumbricals) affected.**
- **Hand has a clawed appearance due to hyperextension of metacarpophalangeal joints & flexion of interphalangeal joints.**

# Cont.

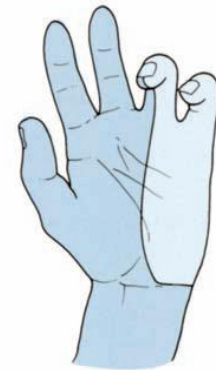- → **extensor digitorum** is unopposed by lumbricals & interossei & extends the metacarpophalangeal joints.
- Because **flexor digitorum superficialis & profundus** are unopposed by lumbricals & interossei, **middle & terminal phalanges** are flexed.
- There is also **sensory loss** along **medial side of forearm, hand & medial 2 fingers**
- Lower brachial plexus lesions may also result from malignant metastases from lungs in lower deep cervical lymph nodes & an aberrant **cervical rib**.

# Deformities of the hand

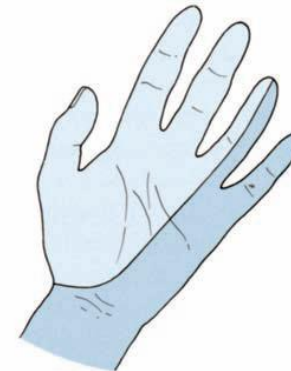
- Deformities of the hand:????
- (a) **Radial n palsy—wrist drop.**
- (b) **Ulnar nerve palsy—‘main engriffe’ or claw hand.**
- (c) **Median nerve palsy—‘monkey’s hand’.**
- (d) **Volkman’s contracture—another claw hand deformity.**
- *The pale blue areas represent the usual distribution of anaesthesia.*



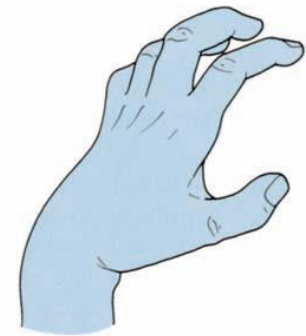
(a)



(b)



(c)



(d)

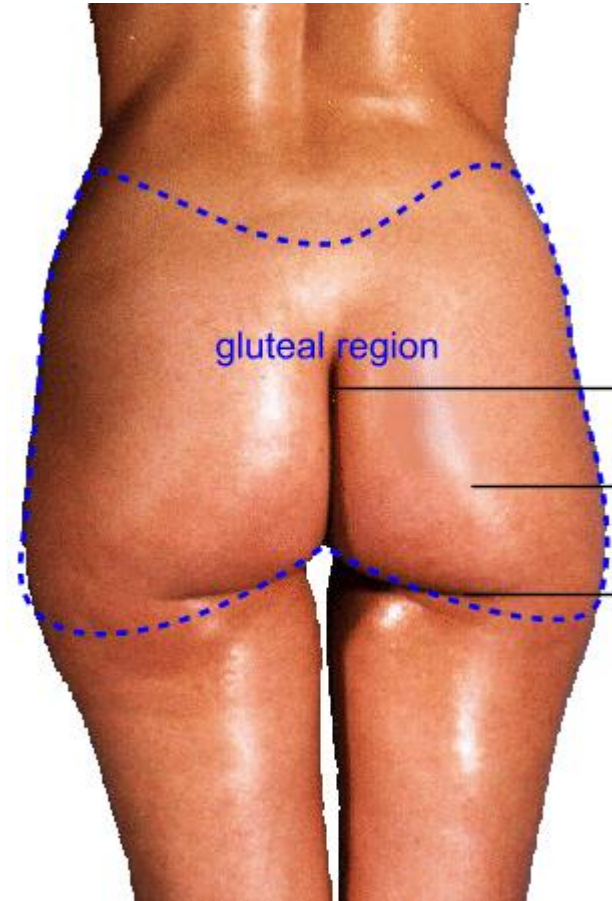


# Organization of Proximal Lower Limb

- The lower limbs function primarily in standing and walking...
- It is important to be familiar with lower limb movements and concentric and eccentric contractions of muscles
- During evolution with the assumption of bipedalism and an erect posture.
  - The development of a prominent gluteal w/h is unique to humans
  - Modification of the shape of the femur necessary for bipedal walking and running (specifically the “bending” of the bone, creating the angle of inclination and the trochanters) allows the superior placement of the abductors of the thigh into the gluteal region.

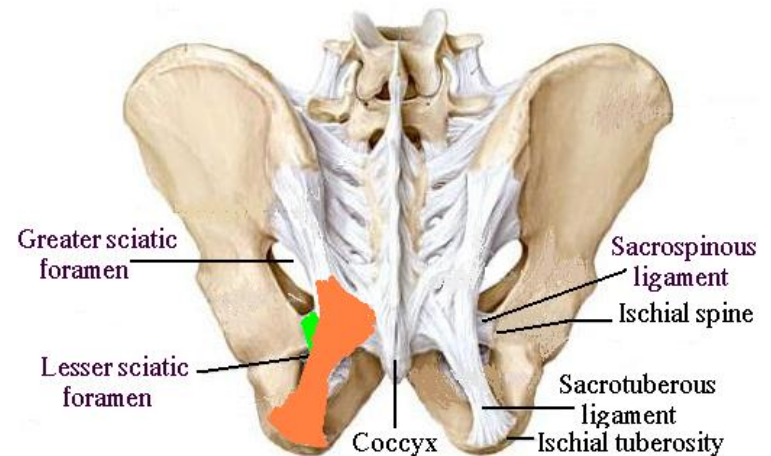
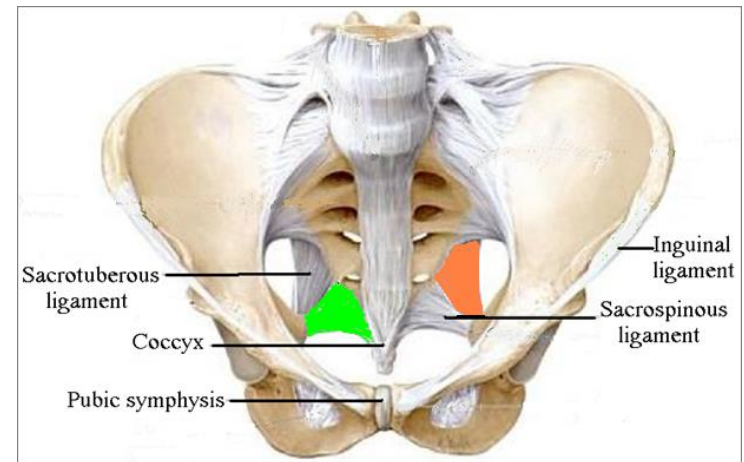
# The Gluteal Region (Buttock+)

- It is the region behind the pelvis, extending from the **iliac crest superiorly** to the **gluteal fold** (fold of the buttock) **inferiorly**
- Gluteal fold indicates the **lower border of the gluteus maximus muscle** (gluteal sulcus/crease is a skin crease for the hip joint)
- A deep midline groove, the **natal (intergluteal) cleft** separates the buttocks from each other.
- The gluteal muscles (gluteus maximus, medius, and minimus and tensor fasciae latae) form the bulk of the region.
- **Physically part of the trunk, functionally, the gluteal region is definitely part of the lower limb.**



# Ligaments of the Gluteal Region

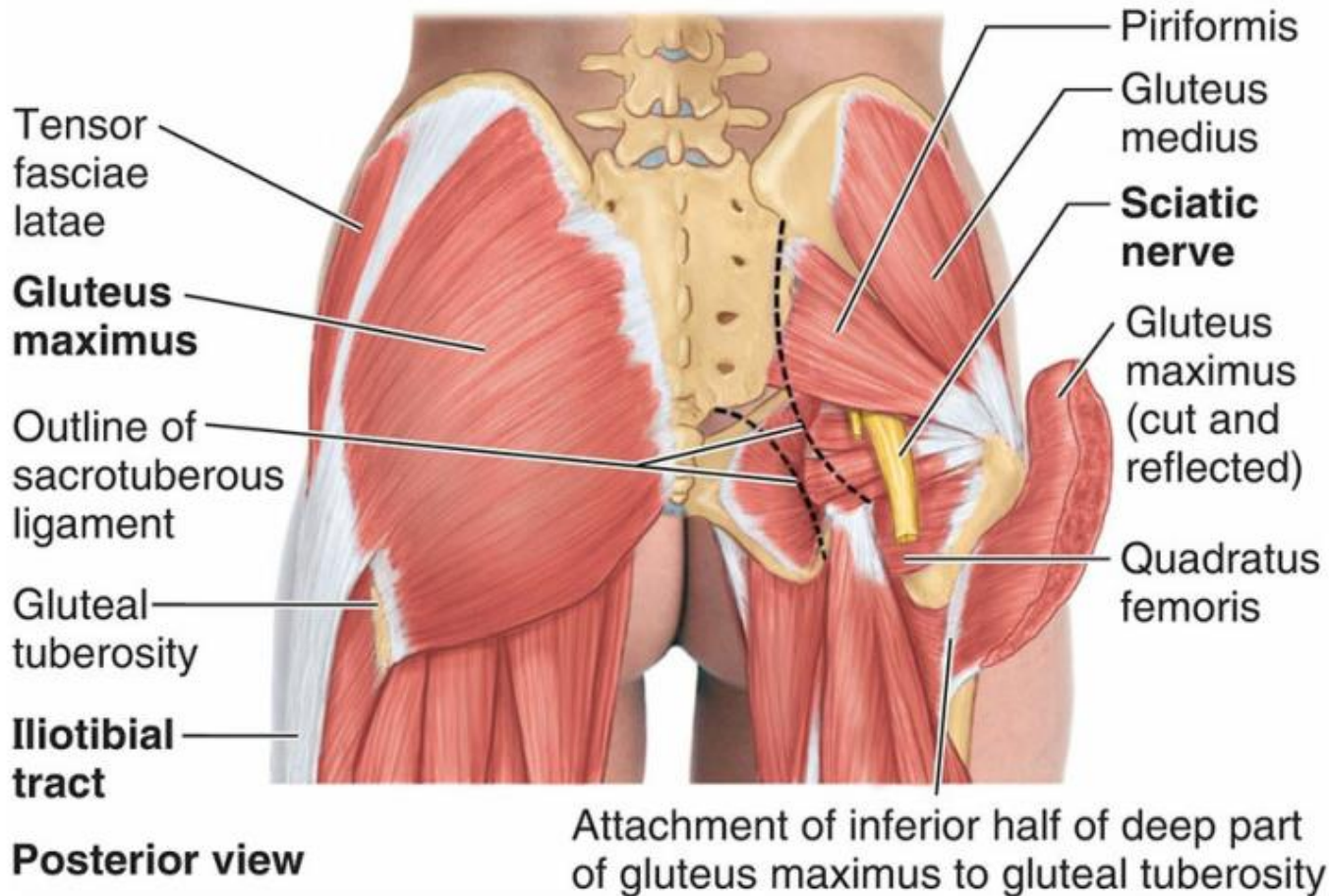
- **2 ligaments:**
  - **Sacrospinous, connecting sacrum to ischial spine**
  - **Sacrotuberous, connecting sacrum to ischial tuberosity**
- **They convert the greater & lesser sciatic notches into greater & lesser sciatic foramina**
- **Their main function is to:**
  - **Stabilize the sacrum**
  - **Prevent its posterior rotation at the sacroiliac joint**



# Muscles of Gluteal Region

- **The muscles of the gluteal region share a common compartment but are organized into two layers:**
  - **The superficial layer** (maximus, medius, and minimus) and the tensor fasciae latae.
    - These muscles all have proximal attachments to the posterolateral (external) surface and margins of the ala of the ilium and are mainly **extensors, abductors, and medial rotators of the thigh**.
  - **The deep layer** (piriformis, obturator internus, superior and inferior gemelli, and quadratus femoris) covered by the inferior half of the gluteus maximus.
    - All have distal attachments on or adjacent to **the intertrochanteric crest of the femur**.
    - **Lateral rotators** of the thigh, but they also **stabilize the hip joint**, working with the strong ligaments of the hip joint to steady the femoral head in the acetabulum.

# Muscles of Gluteal Region





# Cont.

## ORIGINS:

### Gluteus minimus:

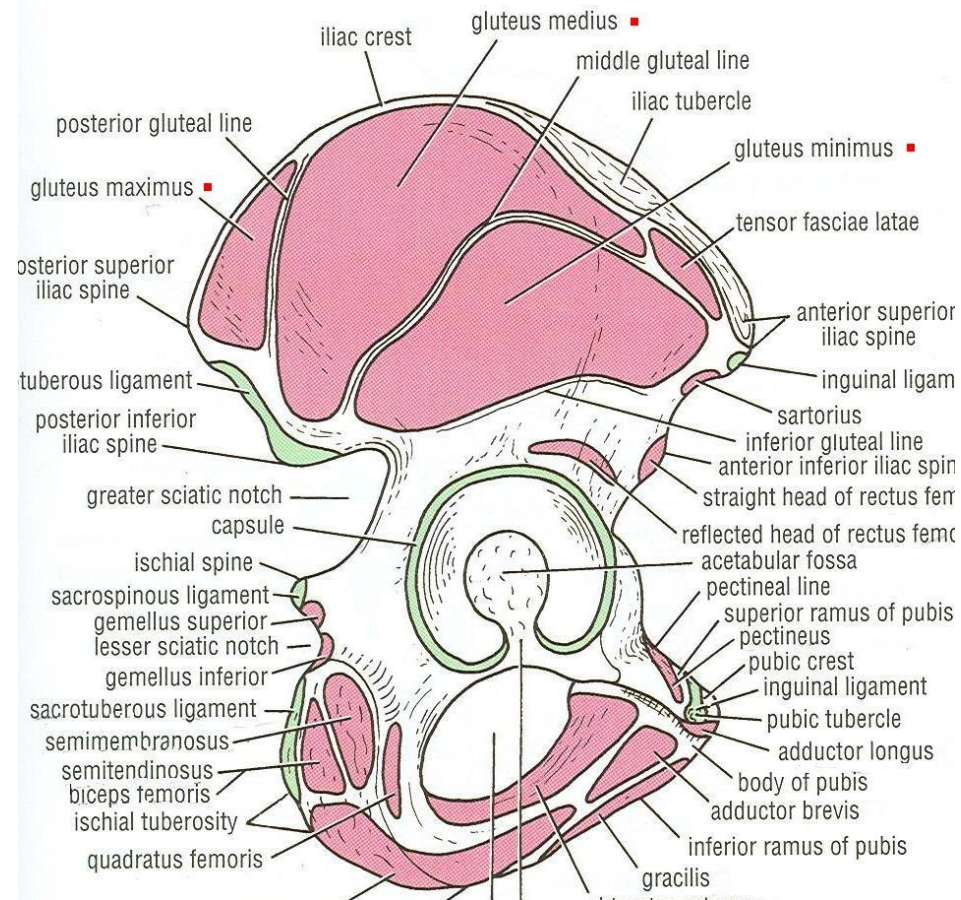
- Anterior part of the gluteal surface of ilium

### Gluteus medius:

- Middle part of the gluteal surface of ilium.

### Gluteus maximus:

- Posterior part of the gluteal surface of ilium.
- Main origin of gluteus maximus: Back of sacrum & coccyx & back of Sacrotuberous ligament.

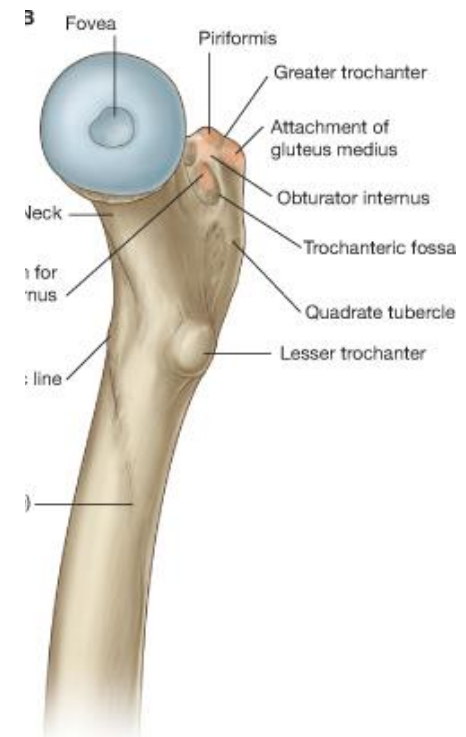
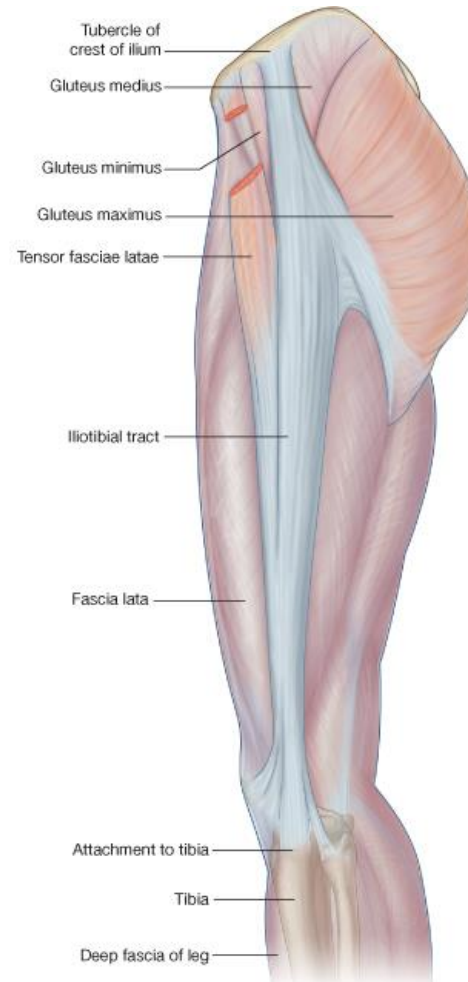




# Cont.

## □ Insertion:

- **Gluteus minimus:**  
anterior surface of the greater trochanter
- **Gluteus medius:**  
lateral surface of the greater trochanter
- **Gluteus maximus:**
  1. **Main insertion:**  
iliotibial tract
  2. **Other insertion:**  
gluteal tuberosity of the femur.



- www.studentconsult.com

# Nerve Supply & Action

## □ Gluteus medius & minimus:

### □ **Nerve supply:**

- Superior gluteal nerve.

### □ **Action:**

- Abduction & Medial rotation of hip joint.
- Also they prevent tilt of the pelvis on raising the other limb from ground.

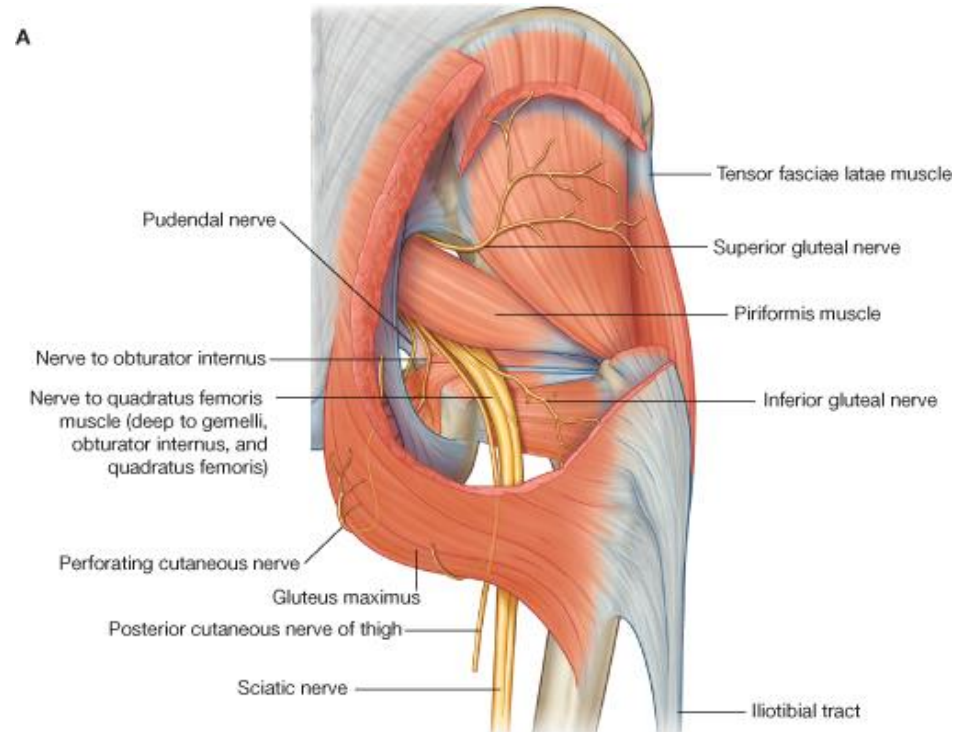
## □ Gluteus maximus:

### □ **Nerve supply:**

- Inferior gluteal nerve.

### □ **Action:**

- Extension & lateral rotation of the hip joint.
- Through its attachment to iliotibial tract, it stabilizes the femur on the tibia during standing.



# Small muscles

## □ Obturator Internus:

### □ Origin:

- Side wall of the pelvis.

### □ Insertion:

- Greater trochanter.

### □ Nerve supply:

- Nerve to obturator internus.

## □ Superior & Inferior Gemelli:

### □ Origin:

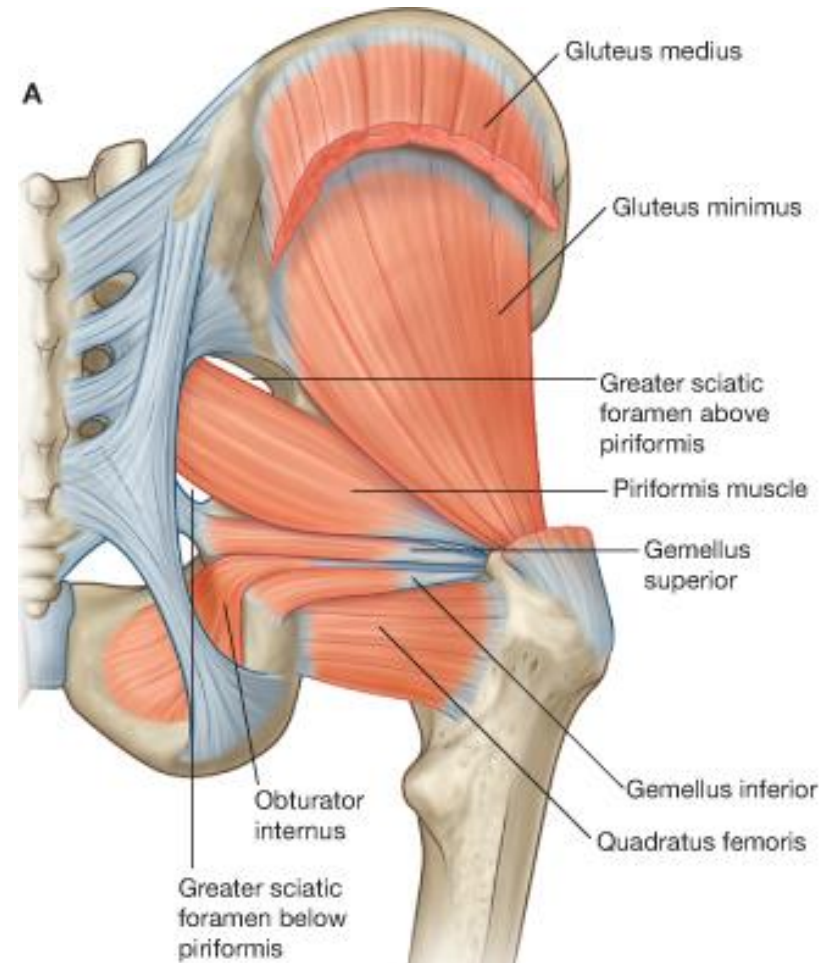
- Upper and lower part of lesser sciatic notch respectively.

### □ Insertion:

- Into tendon of obturator internus.

### □ Nerve supply:

- Superior gemellus: nerve to obturator internus.
- Inferior gemellus: nerve to quadratus femoris.



# Cont.

## □ Piriformis:

### □ **Origin:**

- Pelvic surface of middle 3 sacral vertebrae.

### □ **Insertion:**

- Greater trochanter.

### □ **Nerve supply:**

- Anterior rami of S1,2.

## □ Quadratus femoris:

### □ **Origin:**

- Ischial tuberosity.

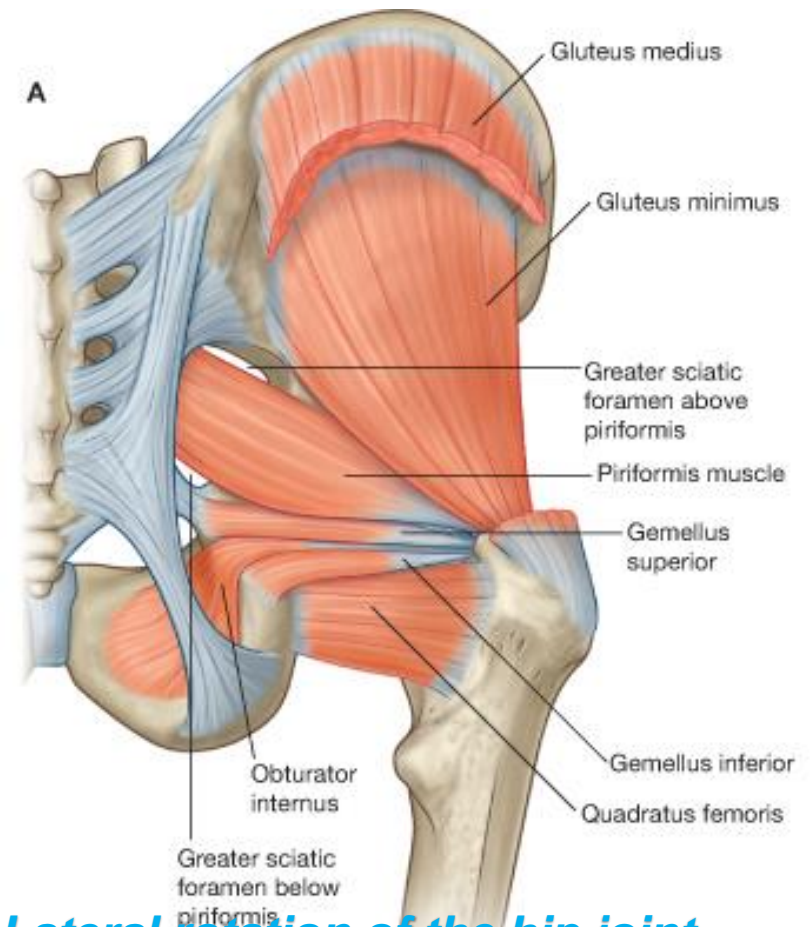
### □ **Insertion:**

- Quadrate tubercle.

### □ **Nerve supply:**

- Nerve to quadratus femoris.

**Action: All have SIMILAR ACTION: Lateral rotation of the hip joint.  
Control movement of the hip joint.**



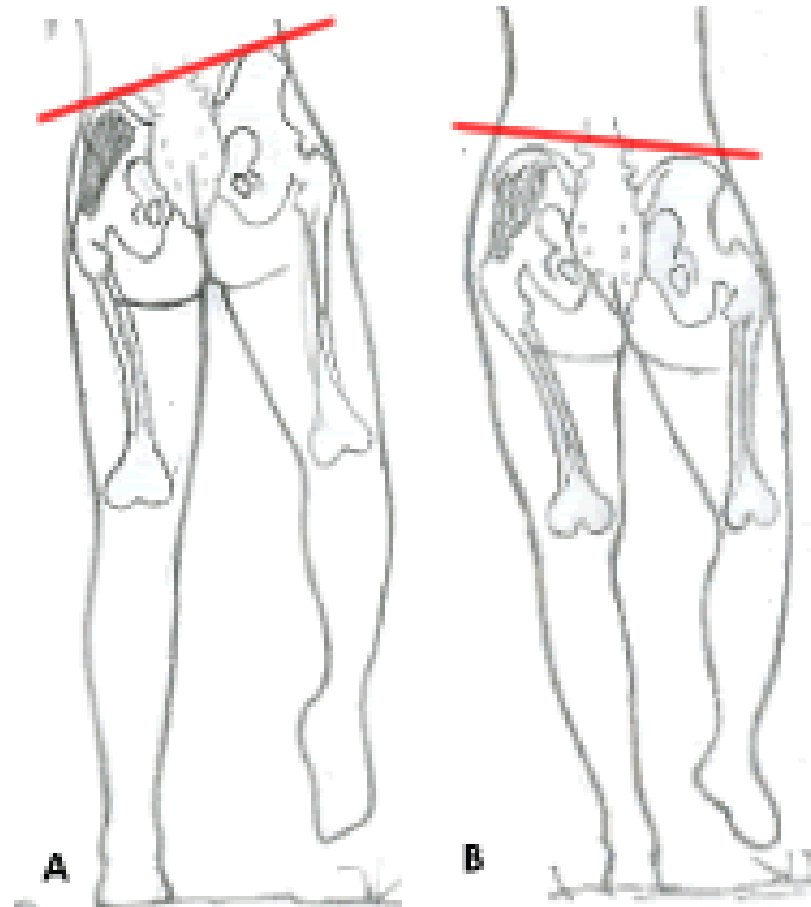
# Lateral balance control

- The gluteus medius and minimus of the supporting limb abduct the pelvis tilting and holding it so that the pelvis on the swinging side is prevented from sagging to the unsupported side.
- This supportive mechanism of the two muscles is generally referred to as **lateral balance control**.
- Its integrity depends on three main features:
  - ▣ The **two muscles** must be functioning normally.
  - ▣ The **hip joint** must be intact.
  - ▣ The **length** and **neck shaft angle** of the **femur** must be normal
- *What happens when any one of the features of lateral balance control is compromised?*

# Trendelenburg's gait

- When any of the features of lateral balance control fails, the supporting is upset.
- The pelvis tends to fall on the unsupported side when the individual stands on the affected limb.
- This is called *Trendelenberg sign*. The person walks with a characteristic lurching or waddling gait.
- *In A : Negative Trendelenburg's test . The hip abductors are acting normally tilting the pelvis upwards when the opposite leg is raised from the ground*

*In B : Positive Trendelenburg's test . The hip abductors are unable to control the dropping of the pelvis when the opposite leg is raised*



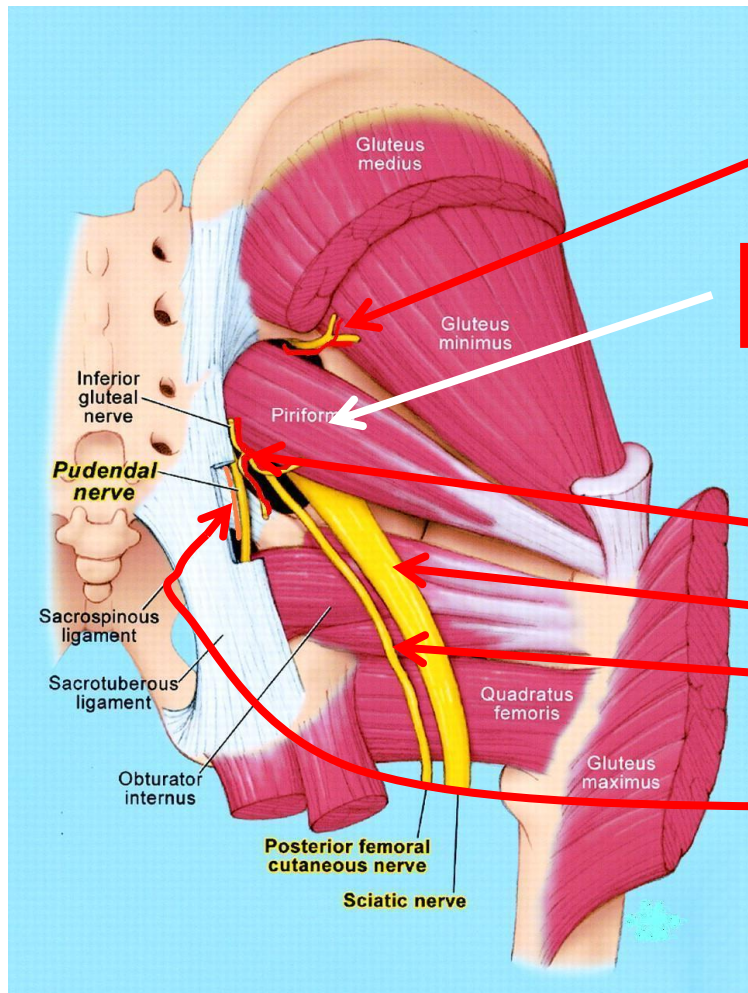


# Reading????

---

- ***Nelaton's line***
- **Shoemaker's line**

# Structures passing through the greater sciatic foramen



## Above the piriformis:

- Superior gluteal vessels & nerve

**Piriformis: an important landmark**

## Below the piriformis:

- Inferior gluteal vessels & nerve
- Sciatic nerve
- Posterior cutaneous nerve of thigh
- Pudendal nerve & Internal pudendal vessels
- Nerve to obturator internus
- Nerve to quadratus femoris

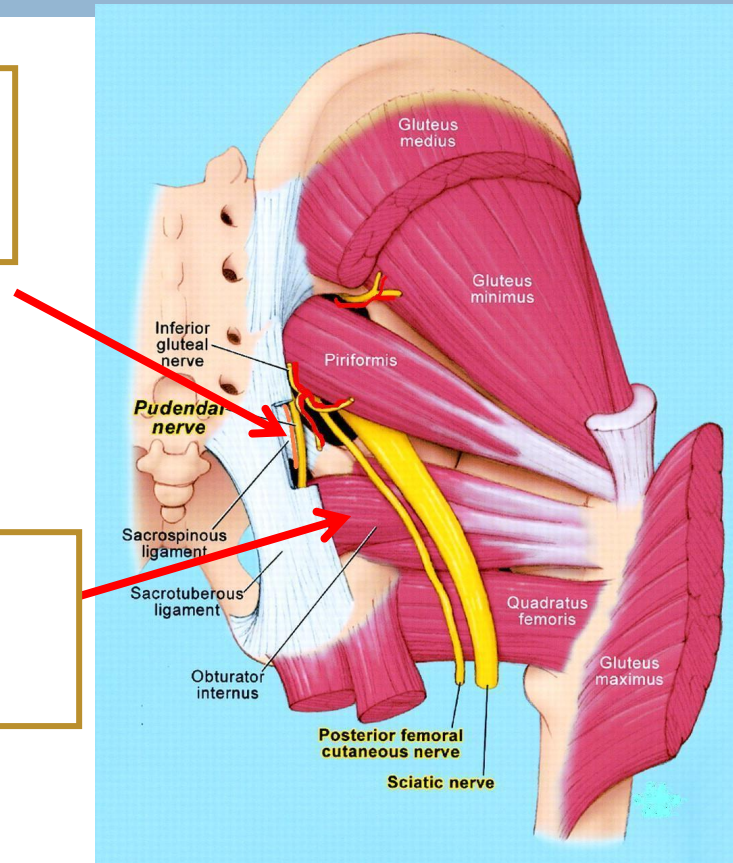
# Structures passing through the lesser sciatic foramen

## Entering:

Pudendal nerve &  
Internal pudendal vessels

## Exiting:

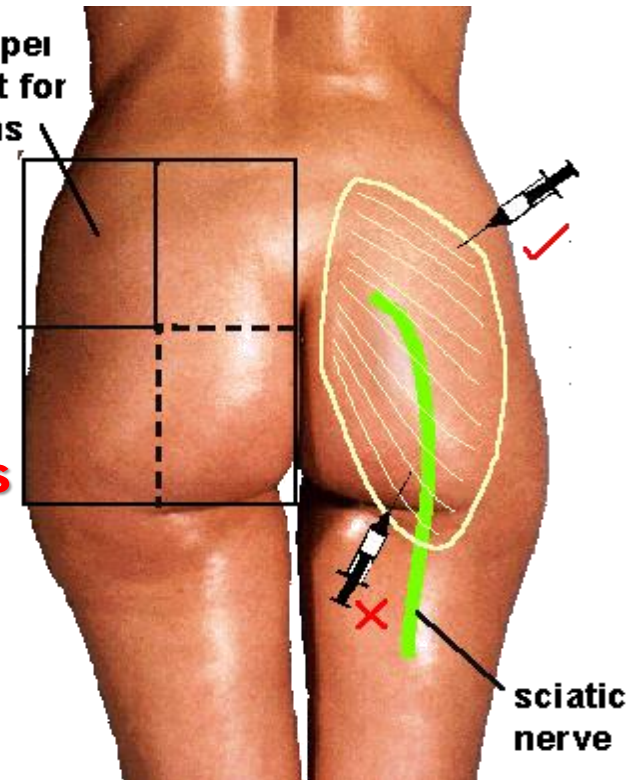
Tendon of obturator internus  
Nerve to obturator internus



# Safe Area for Intramuscular Injection

- Intramuscular injection enables a large amount of a drug to be introduced at once but absorbed gradually.
- The injection site must be carefully selected to avoid injury to the underlying large vessels and nerves.
- **Outer upper quadrant of the buttock is the safe area for intramuscular injection to avoid injury to the underlying sciatic nerve**

outer upper quadrant for injections



# The thigh

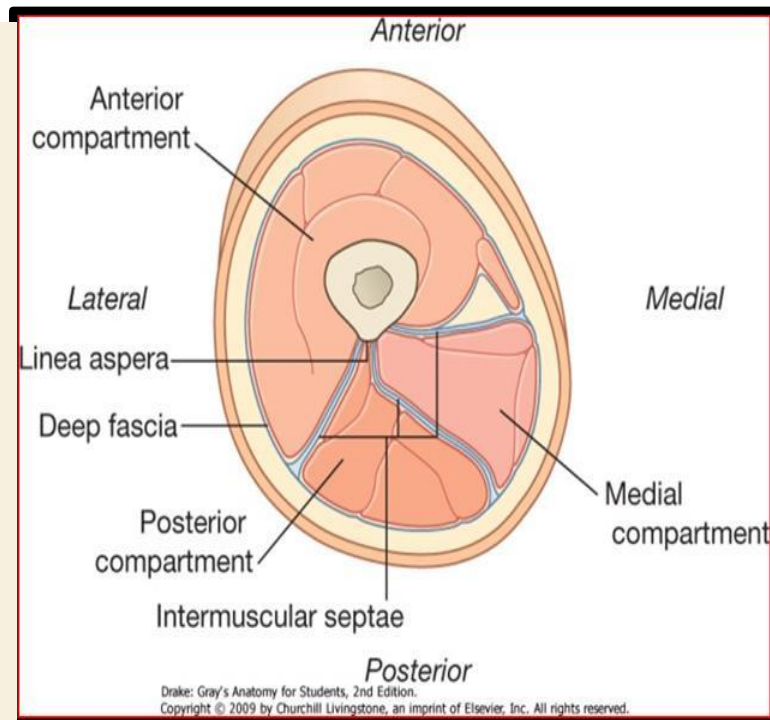
---

- **The thigh muscles are organized into three compartments by intermuscular septa that pass deeply between the muscle groups from the inner surface of the fascia lata to the linea aspera of the femur.**

# Compartments of thigh

## Anterior Compartment

- **Extensors of knee:**  
Quadriceps femoris
- **Flexors of hip:**
  1. Sartorius
  2. Pectineus
  3. psoas major
  4. Iliacus
- ❖ **Nerve supply:**  
Femoral nerve



## Medial Compartment

- **Adductors of hip:**
  1. Adductor longus
  2. Adductor brevis
  3. Adductor magnus (adductor part)
  4. Gracilis
- ❖ **Nerve supply:**  
Obturator nerve

## Posterior Compartment

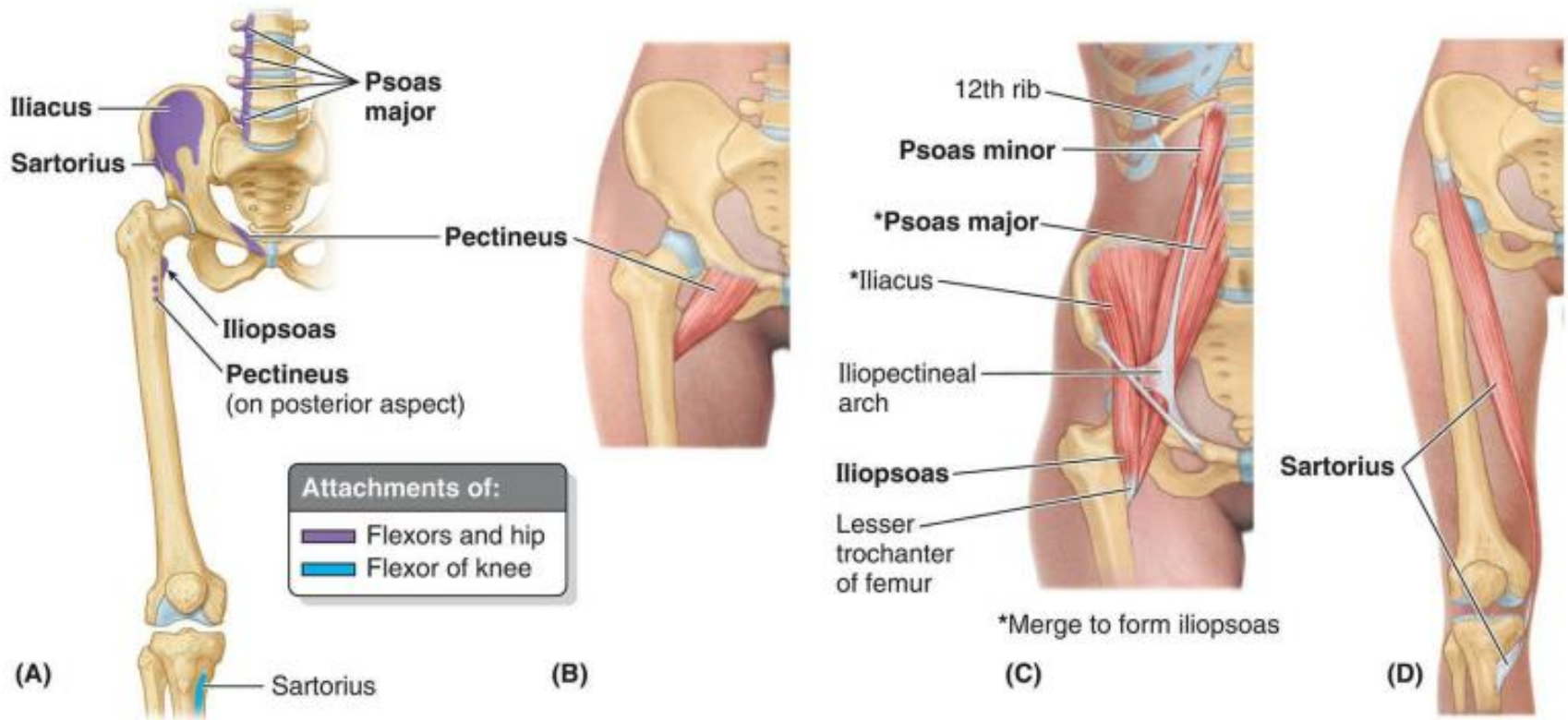
- **Flexors of knee & extensors of hip:**  
Hamstrings
- ❖ **Nerve supply:**  
Sciatic nerve



# Anterior Compartment Of Thigh

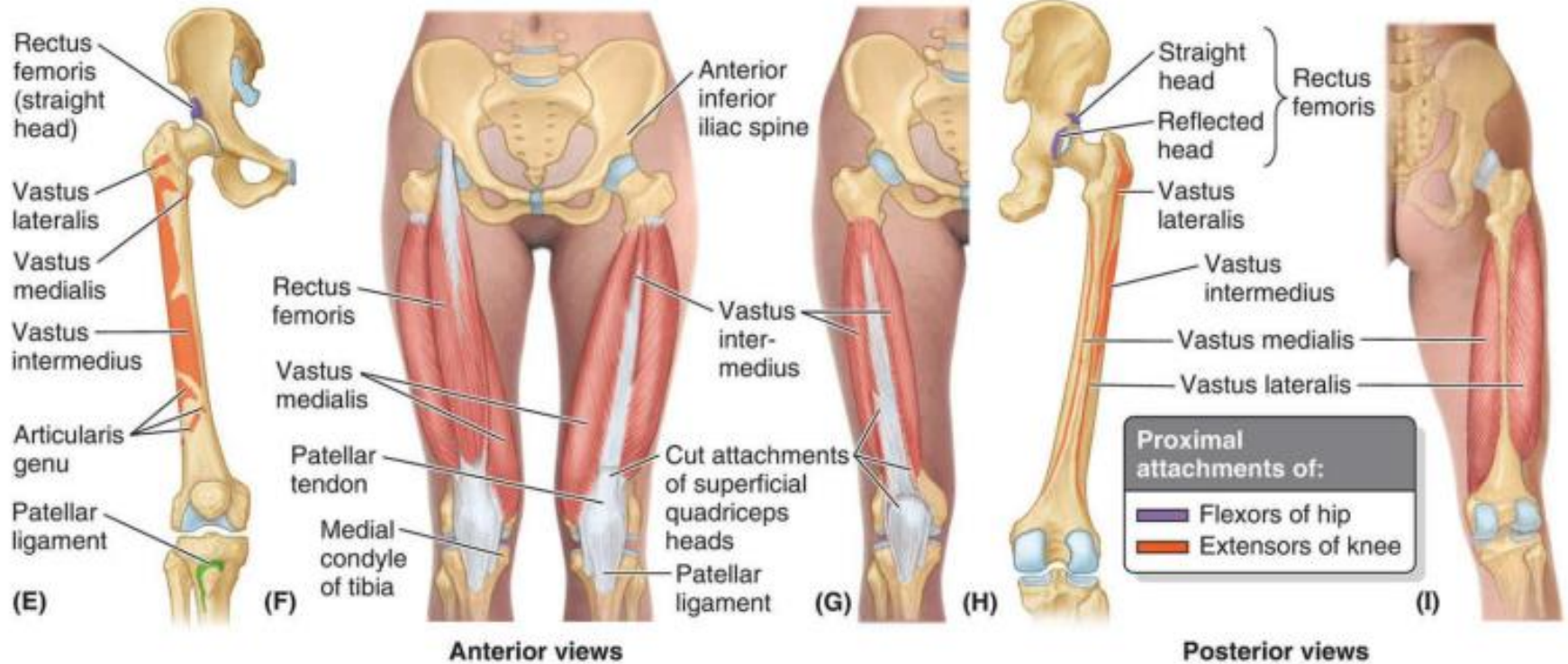
- The large anterior compartment of the thigh contains the anterior thigh muscles, the flexors of the hip and extensors of the knee.
- The anterior thigh muscles include the *pectineus, iliopsoas, sartorius, and quadriceps femoris.*<sup>1</sup>
- The major muscles of the anterior compartment tend to atrophy (diminish) rapidly with disease, and physical therapy is often necessary to restore strength, tone, and symmetry with the opposite limb after immobilization of the thigh or leg.
- Femoral nerve (L2, L3, L4) supplies muscles of anterior compartment of the thigh (quadriceps femoris), including pectineus muscle.
- Psoas m. receives its nerve supply from the lumbar plexus.

# Anterior Compartment Of Thigh



Anterior views

# Cont.

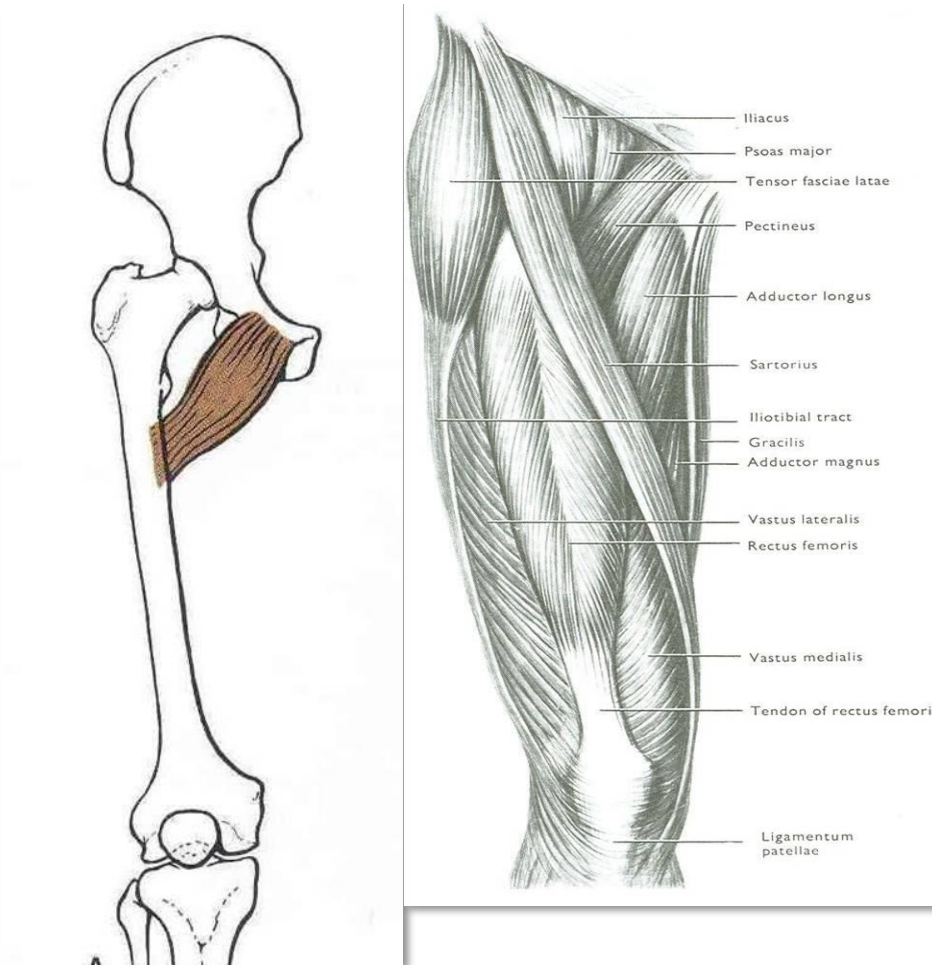


# Sartorius



- **Origin**
  - Anterior superior iliac spine
- **Insertion**
  - Upper part of medial surface of tibia
- **Action**
  - (Tailor's Position)
  - Flexion, abduction & lateral rotation of hip joint
  - Flexion of knee joint

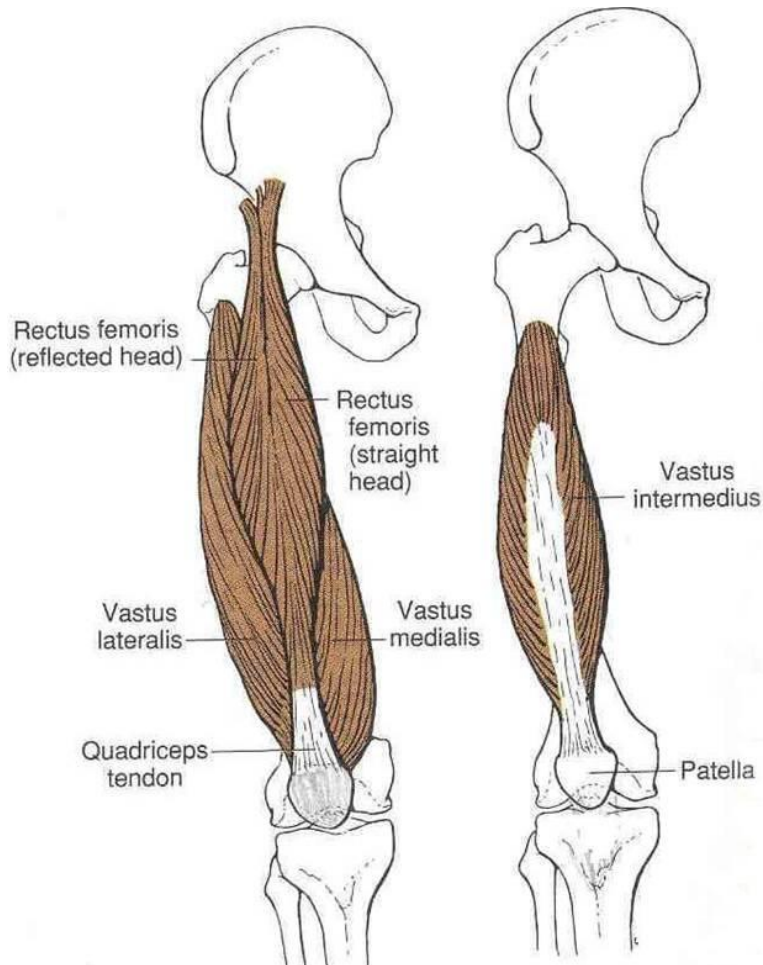
# Pectineus



- **Origin:**
  - **Superior pubic ramus**
- **Insertion:**
  - **Back of femur (below lesser trochanter)**
- **Action:**
  - **Flexion & adduction of hip joint**



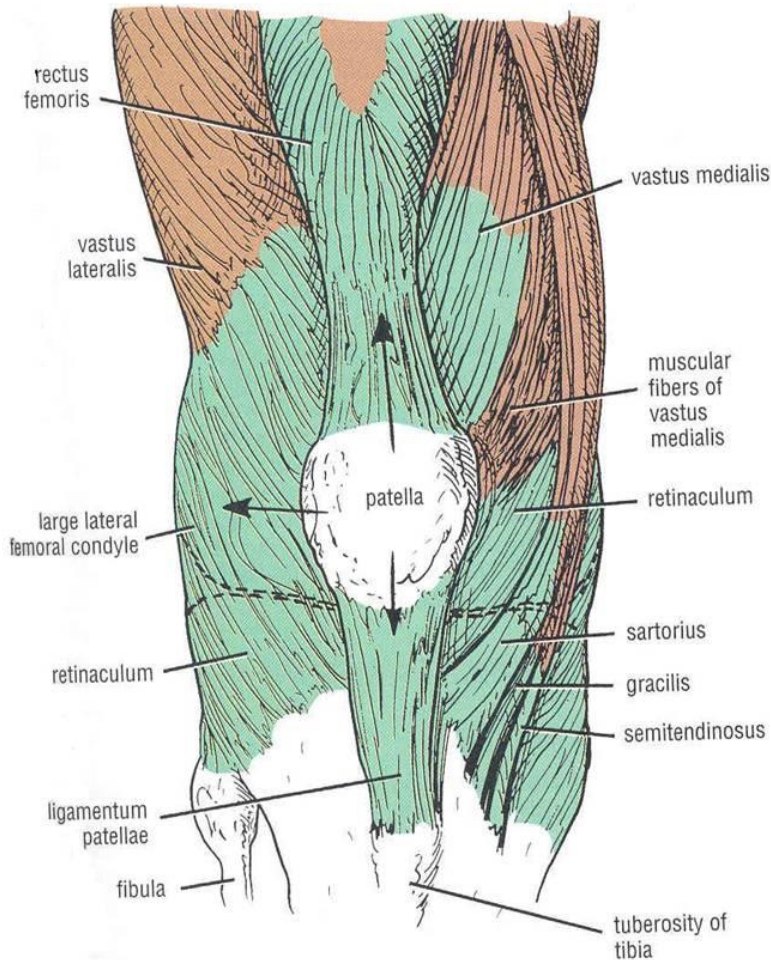
# Quadriceps Femoris



- **ORIGIN:**
- **Rectus femoris:** Anterior inferior iliac spine (Hip bone)
- Susceptible to injury and avulsion from the anterior inferior iliac spine during kicking, hence the name “kicking muscle.” A loss of function of the rectus femoris may reduce thigh flexion strength by as much as 17%
- **Vastus intermedius:**
  - Front of shaft of femur
- **Vastus medialis:**
  - Posterior border of femur
- **Vastus lateralis:**
  - Posterior border of femur (Linea aspera).



# Cont.



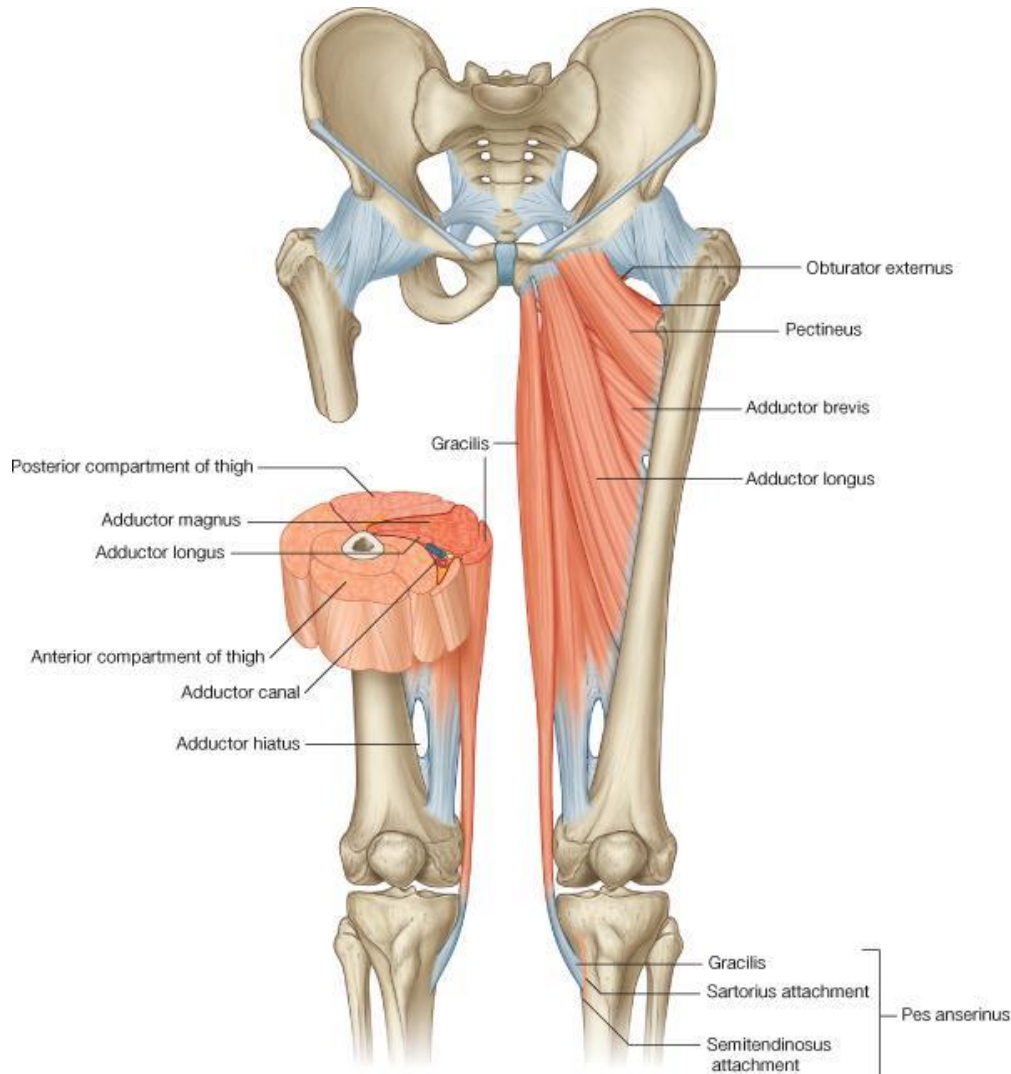
## □ Insertion:

- Into PATELLA
- (Patella is a sesamoid bone)
- From patella into TUBEROSITY OF TIBIA through **LIGAMENTUM PATELLAE (PATELLAR LIGAMENT)**

## □ Action:

- **Extension of knee joint**

# Medial Compartment Of Thigh



## ❑ Muscles:

1. Adductor longus
2. Adductor brevis
3. Adductor magnus (Adductor part)
4. Gracilis and
5. Obturator externus

## ❑ Action:

- ❑ ADDUCTION OF HIP JOINT
- ❑ N.B.: Gracilis also flexes knee joint + adduction of thigh

## ❑ Nerve Supply:

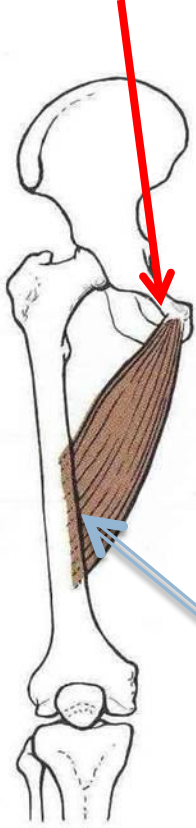
- ❑ OBTURATOR NERVE

# Cont.

- In general, they attach proximally to the **antero-inferior external surface of the bony pelvis** (pubic bone, ischiopubic ramus, and ischial tuberosity), and **adjacent obturator membrane**, and distally to **the linea aspera of the femur**.
- All adductor muscles, except the **“hamstring part”** of the adductor magnus and **part of the pectineus**, are supplied by the **obturator nerve (L2–L4)**.
- The hamstring part of the adductor magnus is supplied by the tibial part of the sciatic nerve (L4).
- *Although they are important in many activities, it has been shown that a reduction of as much as 70% in their function will result in only a slight to moderate impairment of hip function.*

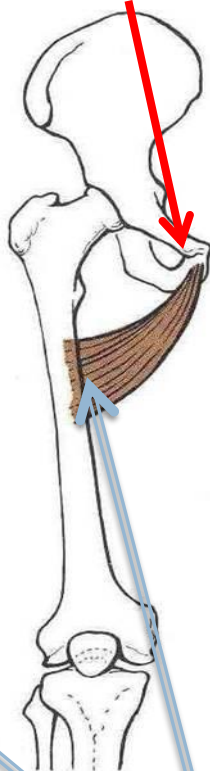
# Origin

▪ Body of pubis



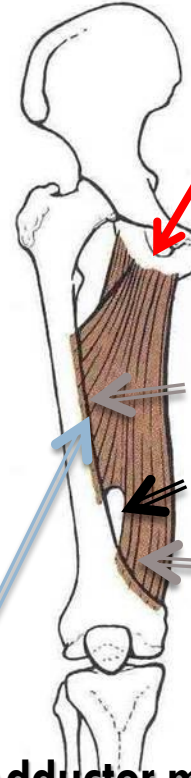
**Adductor longus**

▪ Body of pubis  
▪ Inferior pubic ramus



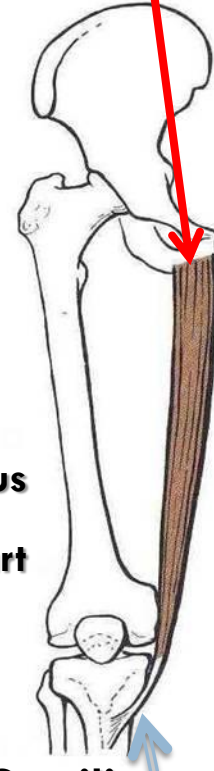
**Adductor brevis**

▪ Inferior pubic ramus  
▪ Ischial ramus



**Adductor magnus  
(adductor part)**

Ischial  
tuberosity



**Gracilis**

# Insertion

▪ Posterior border of femur (Linea Aspera)

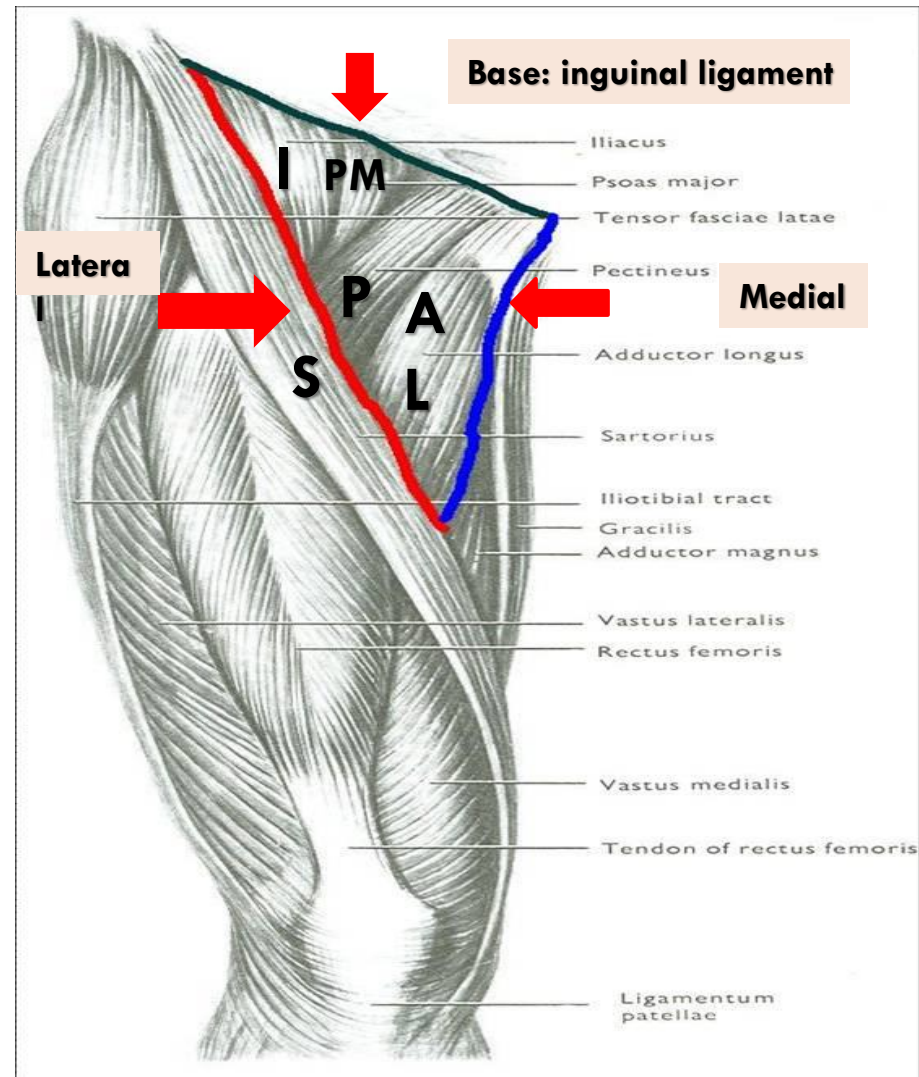
▪ Upper part of medial  
surface of tibia  
(behind sartorius)

# Injury to Adductor Longus

- ❑ **Muscle strains of the adductor longus may occur in horseback riders and produce pain (rider's strain).**
- ❑ **Ossification sometimes occurs in the tendons of these muscles because the horseback riders actively adduct their thighs to keep from falling from their animals.**
- ❑ **The areas of the ossified tendons are sometimes called “riders' bones.”**

# Femoral Triangle

- **Site:**
  - Upper 1/3 of front of thigh
- **Boundaries:**
  - **Base:** inguinal ligament
  - **Lateral:** medial border of sartorius
  - **Medial:** medial border of adductor longus
- **Roof:**
  - Skin
  - Fasciae: superficial & deep
- **Floor:** *From medial to lateral*
  - Adductor longus
  - Pectineus
  - Psoas major
  - Iliacus

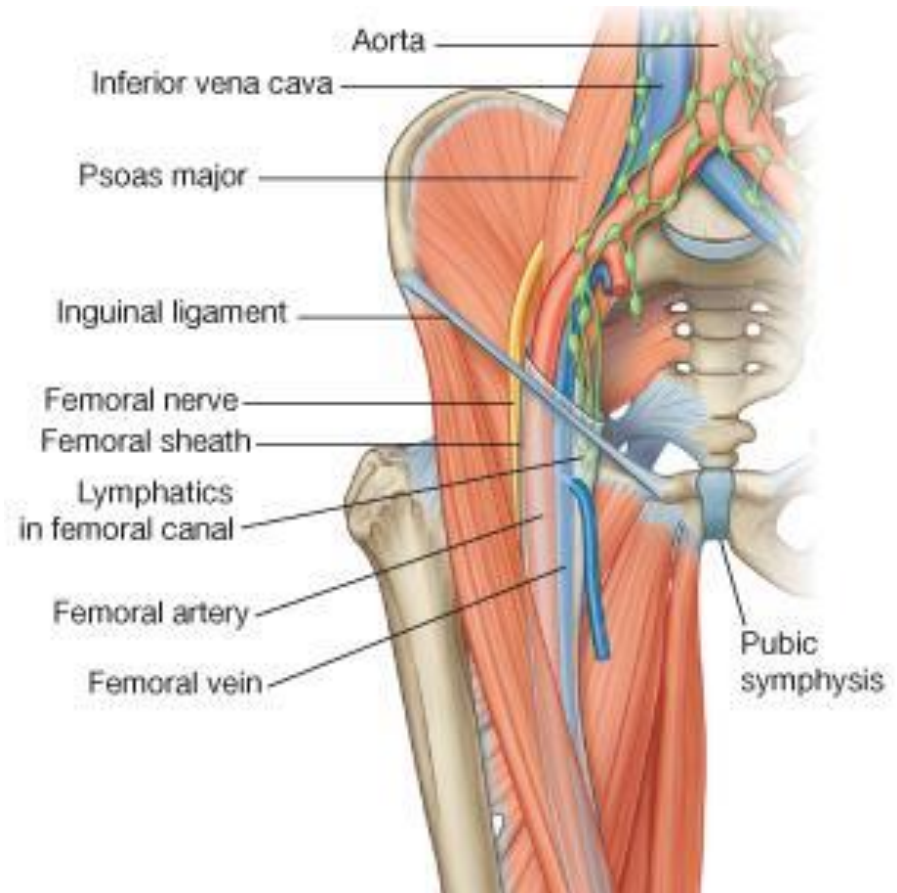




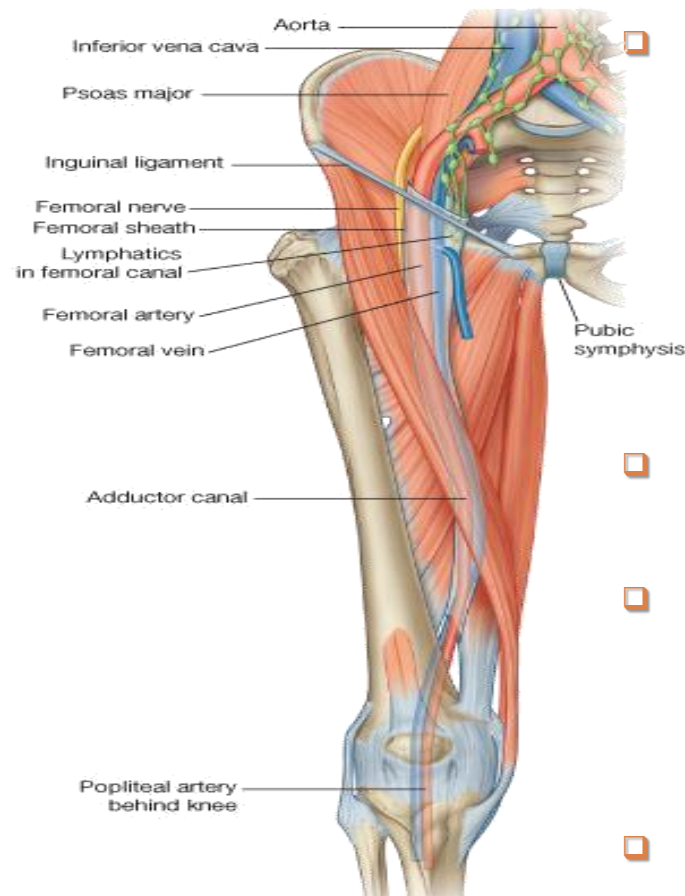
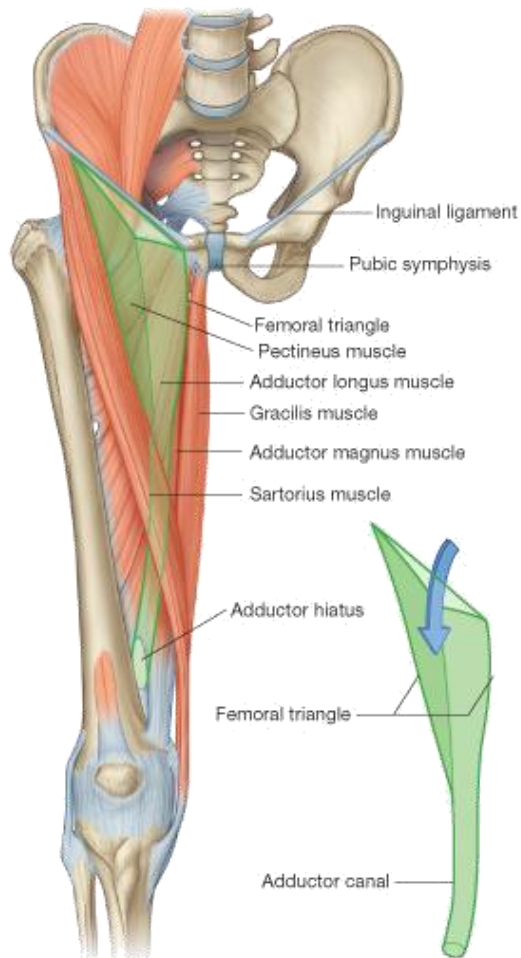
# Cont.

## □ Contents:

- **Femoral vein**
- **Femoral artery**
- **Both vein & artery are enclosed in a fascial envelope (Femoral sheath)**
- **Femoral nerve**
- **Deep inguinal lymph nodes**



# Adductor Canal (Subsartorial Canal)

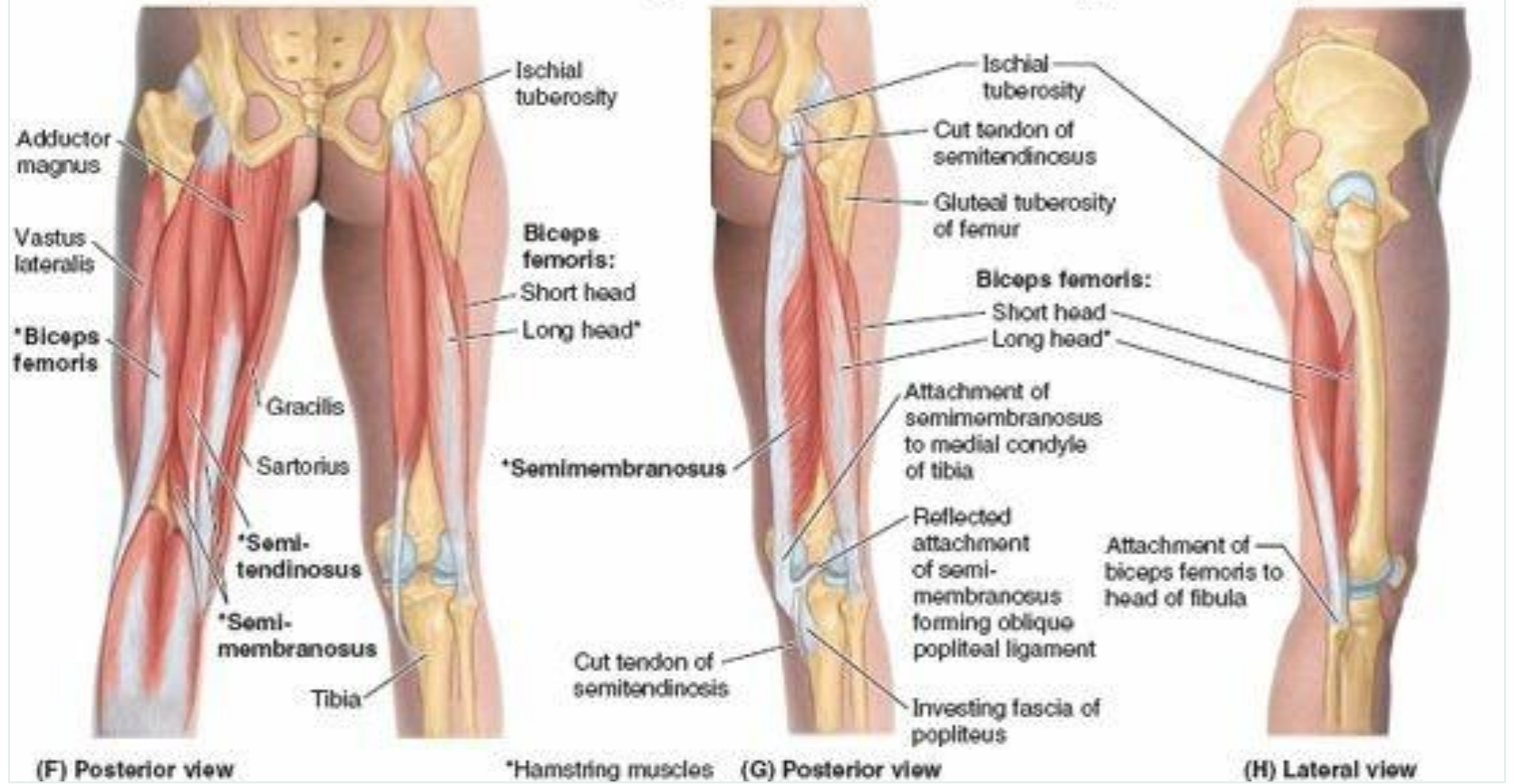
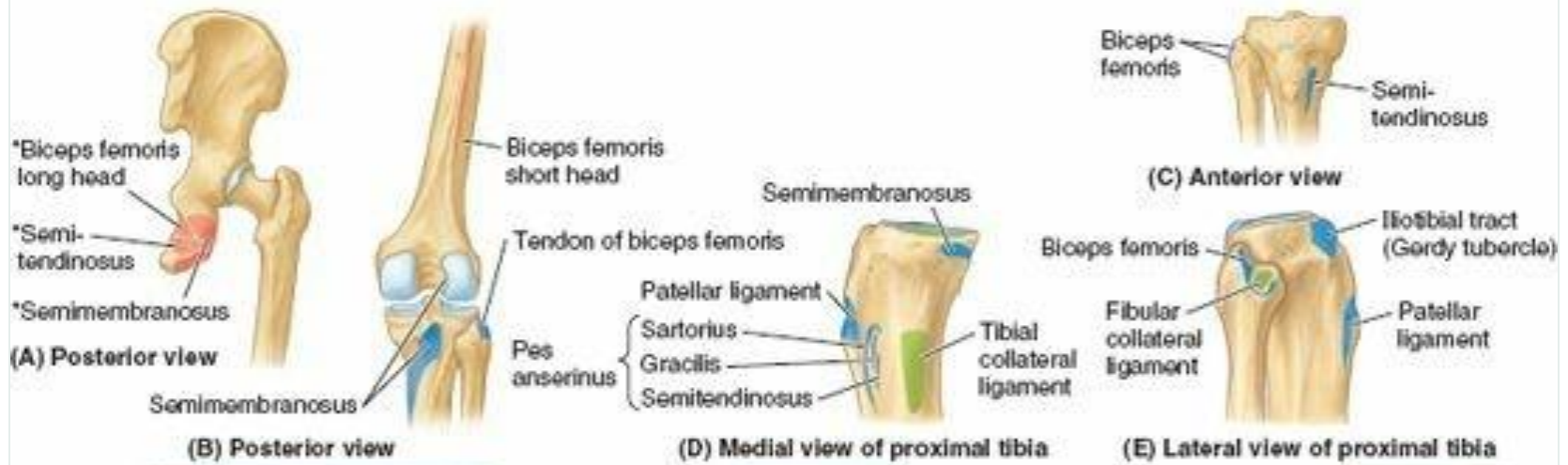


- **Intermuscular passage of A fascial envelope for femoral artery & vein to become the popliteal vessels in the popliteal fossa at the back of knee.**
- **SITE: In middle 1/3 of front of thigh**
- **EXTENT: From apex of femoral triangle to adductor hiatus (in adductor magnus)**
- **BOUNDARIES:**
  - \*Roof: Sartorius**
  - \*Floor: Adductor longus & magnus**

# Posterior Compartment Of The Thigh

- **Muscles in the posterior aspect of the thigh are hamstrings.**
- **The hamstring muscles are:**
  - **(1) semitendinosus,**
  - **(2) semimembranosus, and**
  - **(3) biceps femoris (long head).**
- **The hamstring muscles (“hamstrings” for short) share common features:**
  - **Proximal attachment to the ischial tuberosity deep to the gluteus maximus.**
  - **Distal attachment to the bones of the leg.**
  - **Thus they span and act on two joints, producing extension at the hip joint and flexion at the knee joint.**
  - **Innervation by the tibial division of the sciatic nerve.**

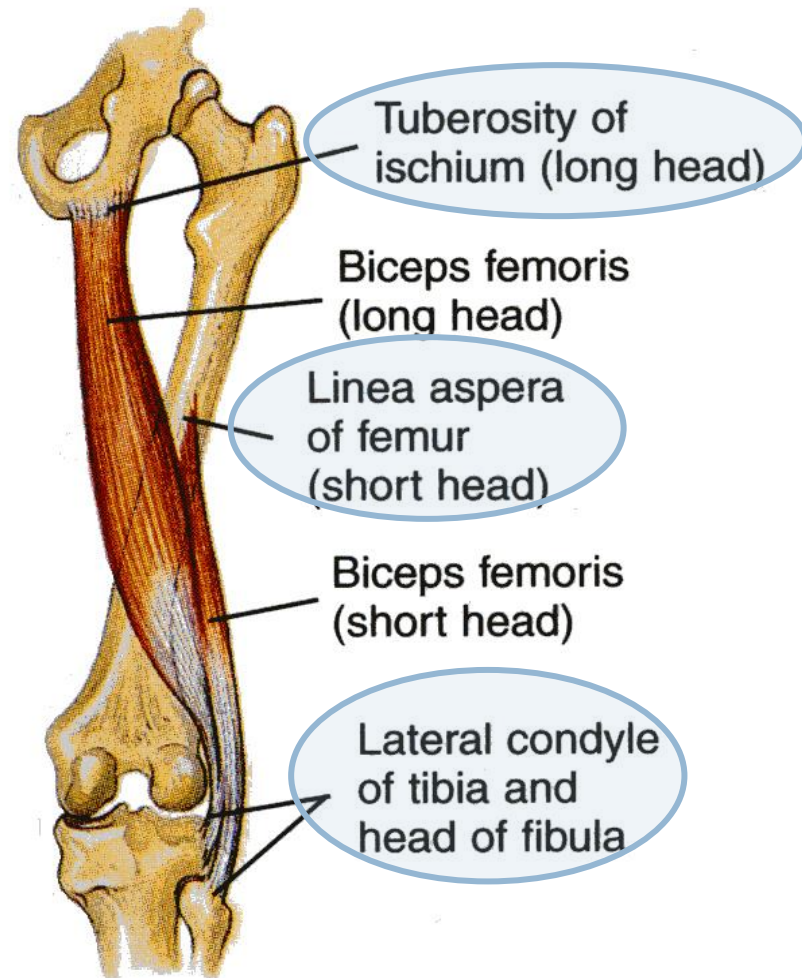




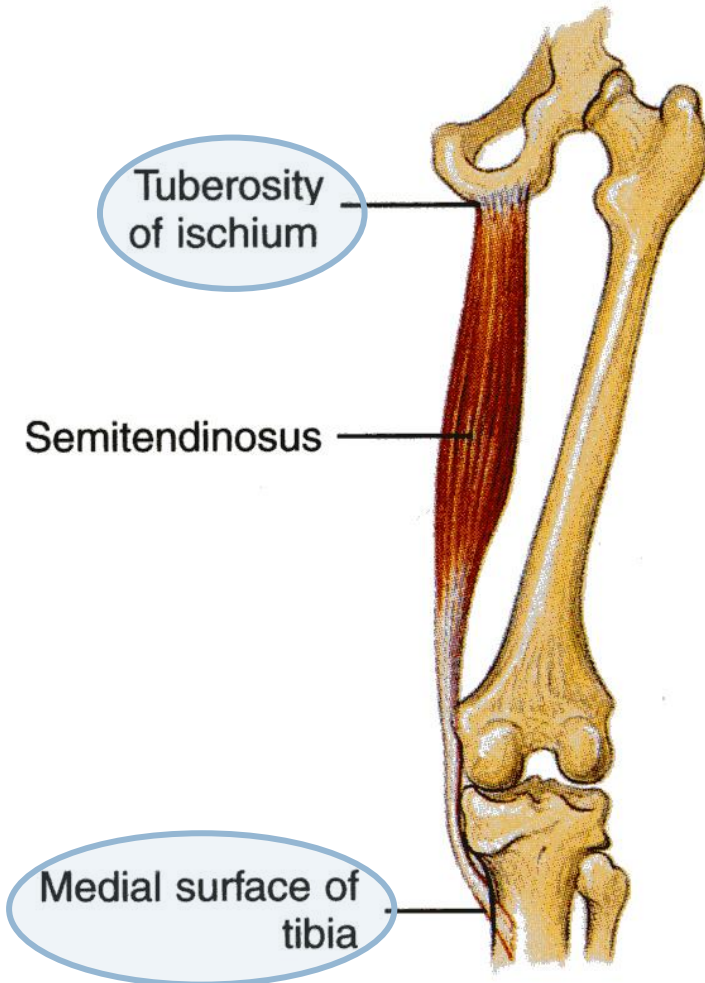


# Biceps Femoris

- **Origin:**
  - Long head from the ischial tuberosity.
  - Short head from the linea aspera
- **Insertion:**
  - Head of the fibula.
- **Nerve supply:**
  - Long head: tibial part of the sciatic;
  - Short head: common peroneal part of the sciatic.
- **Action**
  - Flexion of knee.
  - Lateral rotation of flexed leg.
  - Long head: extends the hip.



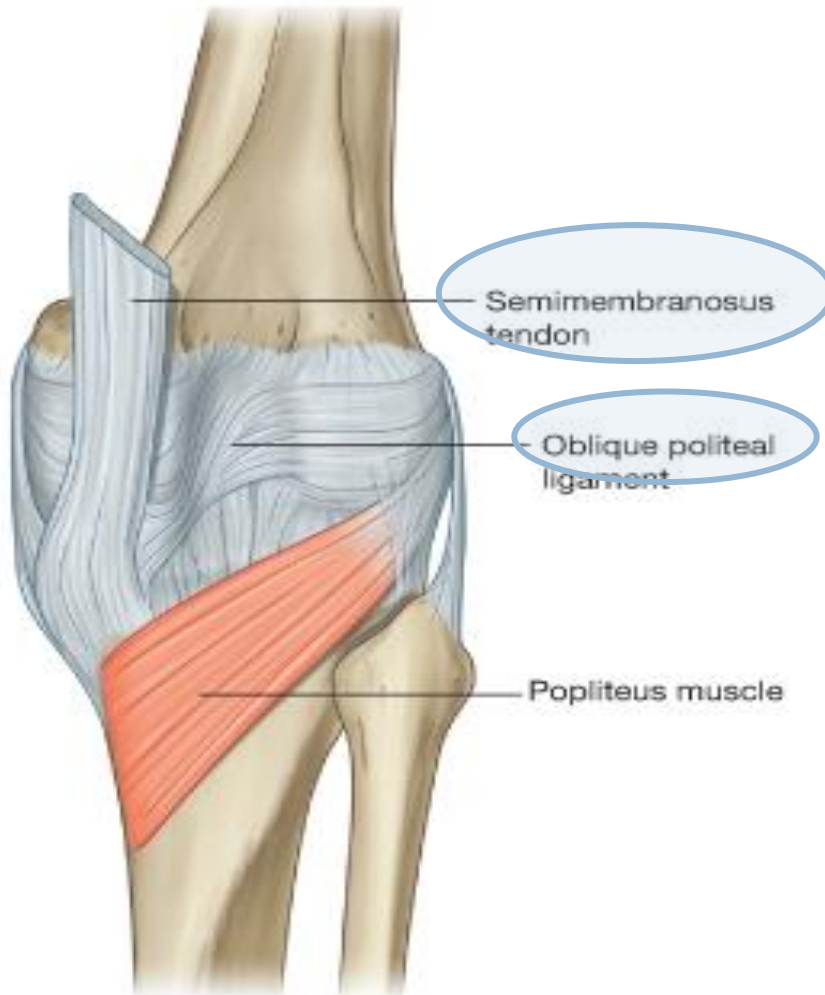
# Semitendinosus



- **Origin:**
  - ▣ Ischial tuberosity.
- **Insertion:**
  - ▣ Upper part of the medial surface of the shaft of the tibia (**SGS**).
- **Nerve supply:**
  - ▣ Tibial portion of the sciatic.
- **Action**
  - ▣ Flexes and medially rotates the leg at the knee joint.
  - ▣ Extends the thigh at the hip joint.

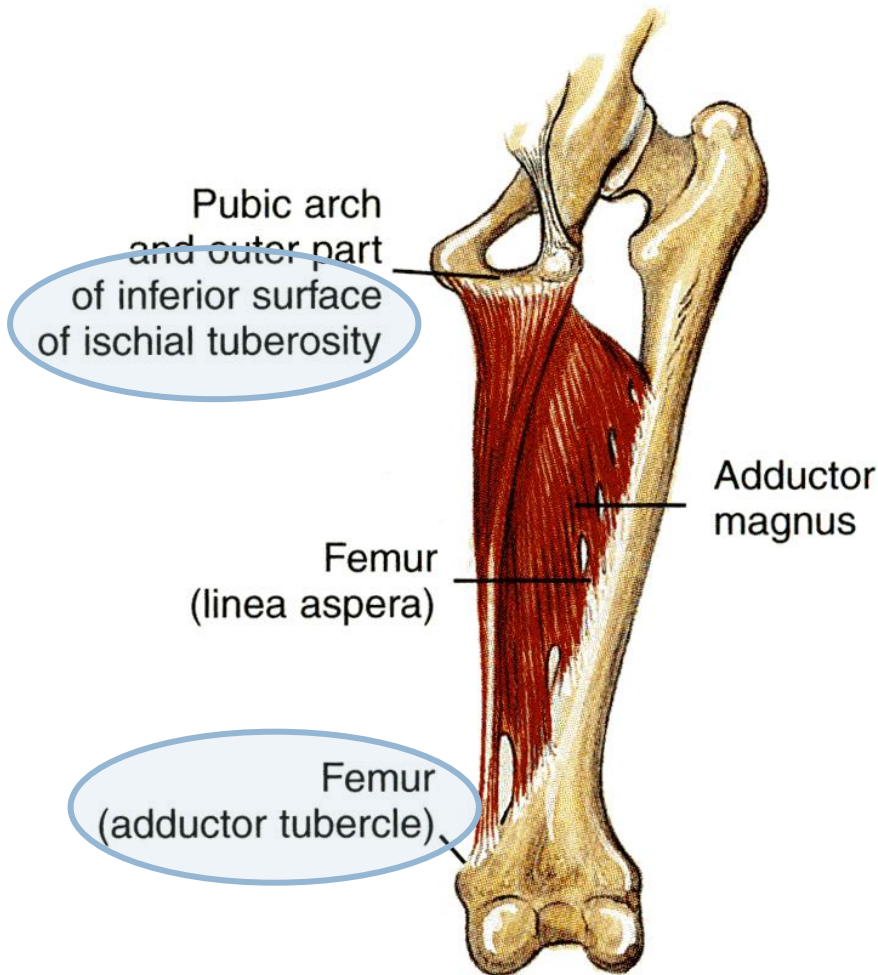


# Semimembranosus



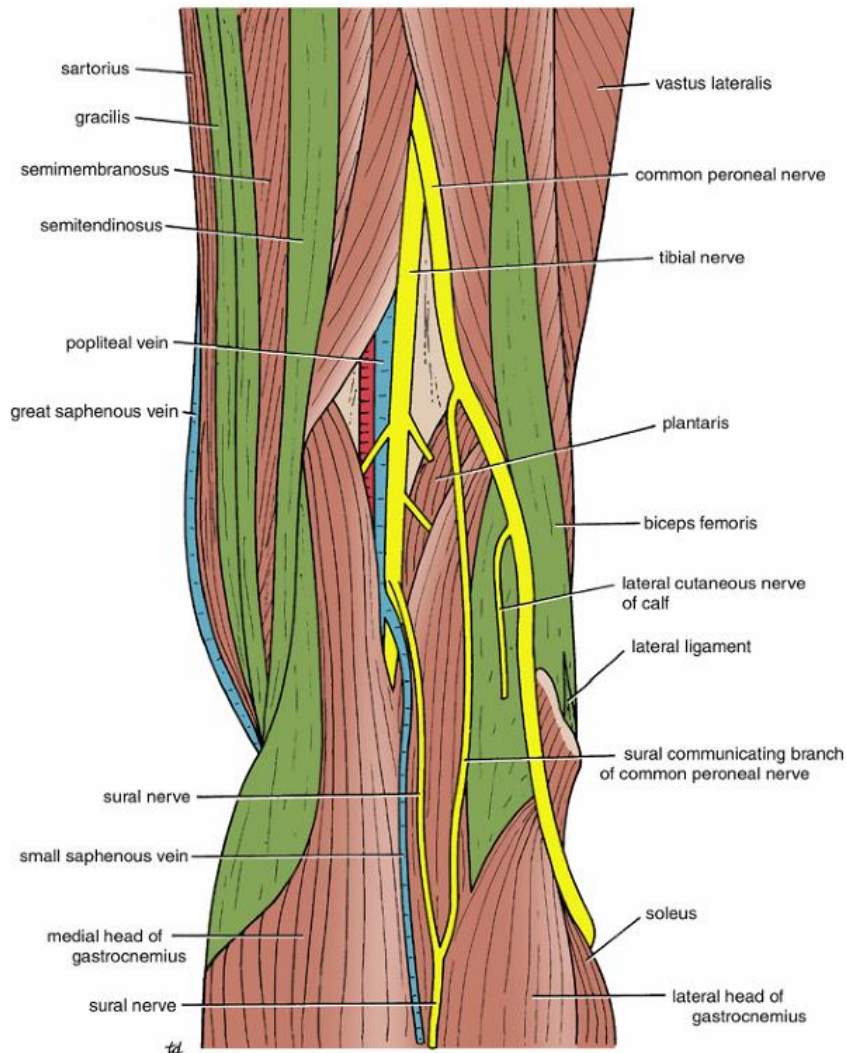
- **Origin:**
  - ▣ Ischial tuberosity.
- **Insertion:**
  - ▣ Posterior surface of the medial condyle of the tibia.
  - ▣ It forms the oblique popliteal ligament, which reinforces the capsule on the back of the knee joint.
- **Nerve supply**
  - ▣ Tibial part of the sciatic nerve.
- **Action**
  - ▣ Flexes and medially rotates the leg at the knee joint;
  - ▣ Extends the thigh at the hip.

# Adductor Magnus (Hamstring Part)



- **Origin:**
  - ▣ Ischial ramus and ischial tuberosity.
- **Insertion:**
  - ▣ Adductor tubercle of the medial condyle of the femur.
- **Nerve supply:**
  - ▣ Tibial portion of sciatic.
- **Action:**
  - ▣ Extends the thigh at the hip joint.

# Popliteal Fossa And Leg



□ Is a diamond-shaped intermuscular space at the back of knee

□ Laterally:

- above: biceps femoris.
- Below: lateral head of gastrocnemius & plantaris

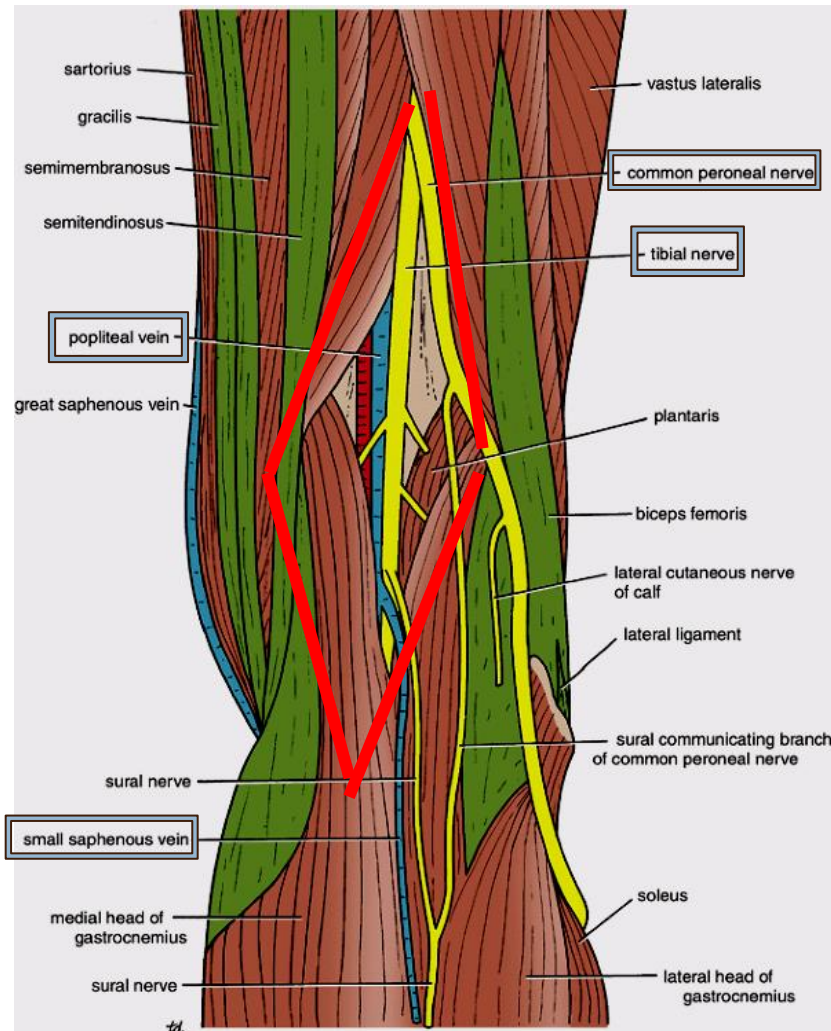
□ Medially:

- above: semimembranosus & semitendinosus.
- Below: medial head of gastrocnemius

□ Roof: Skin, superficial fascia and deep fascia of the thigh.

□ Floor: popliteal surface of femur, posterior ligament of knee joint and popliteus muscle.

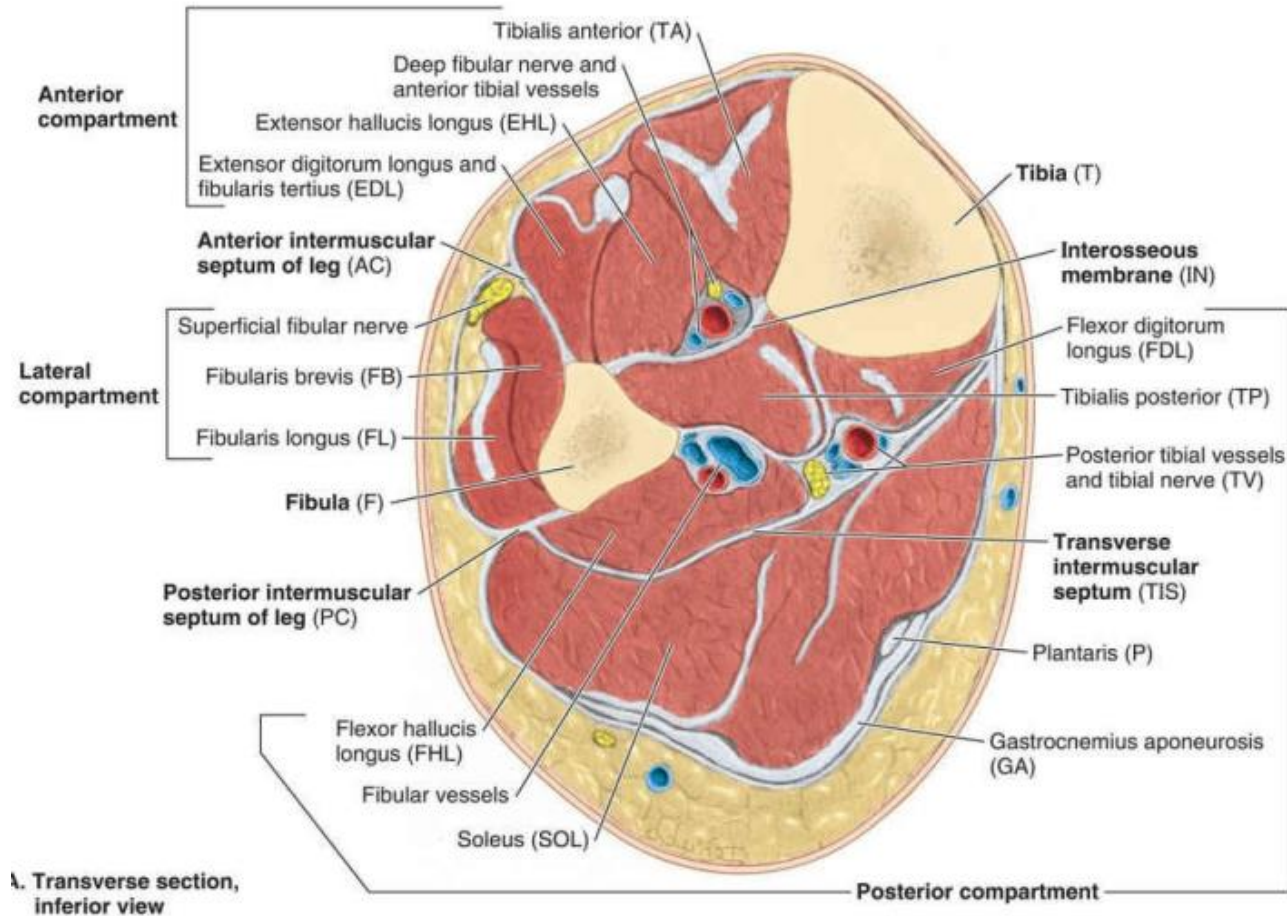
# Contents



- **From medial to lateral**
  - 1. Popliteal vessels
  - 2. Small saphenous vein
  - 3. Tibial nerve.
  - 4. Common peroneal nerve.
  - 5. Posterior cut. nerve of thigh.
  - 6. Connective tissue & popliteal lymph nodes.
- **The deepest structure is popliteal artery.**



# ORGANIZATION OF LEG



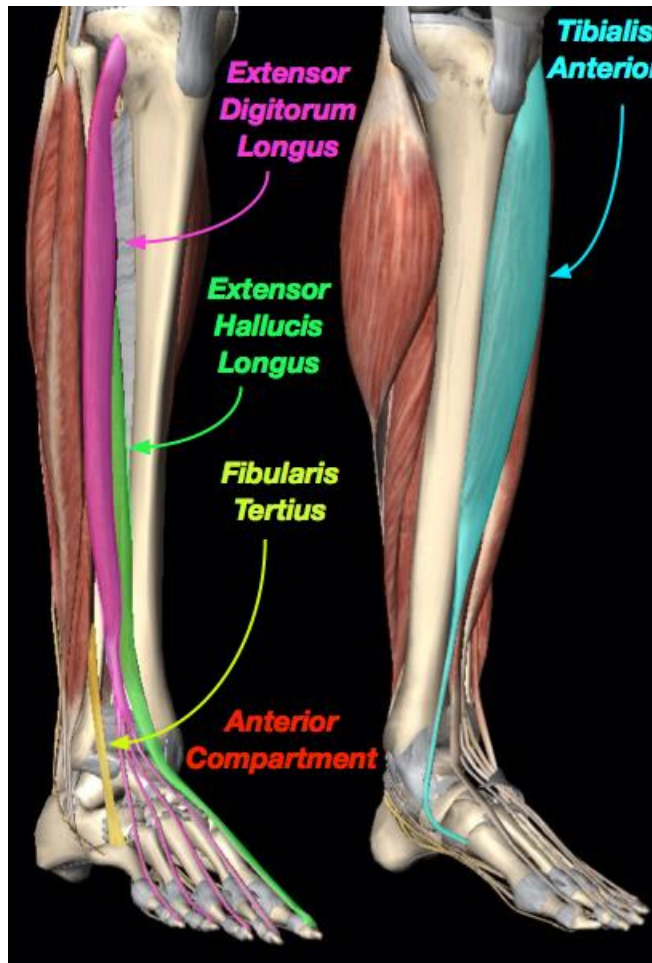
The septa together with the interosseous membrane divide the leg into:

## Three Compartments:

1. Anterior: Extensors.
2. Lateral: Evertors.
3. Posterior: Flexors.

Each compartment has its own **Muscles**, **blood** vessels and **nerve**.

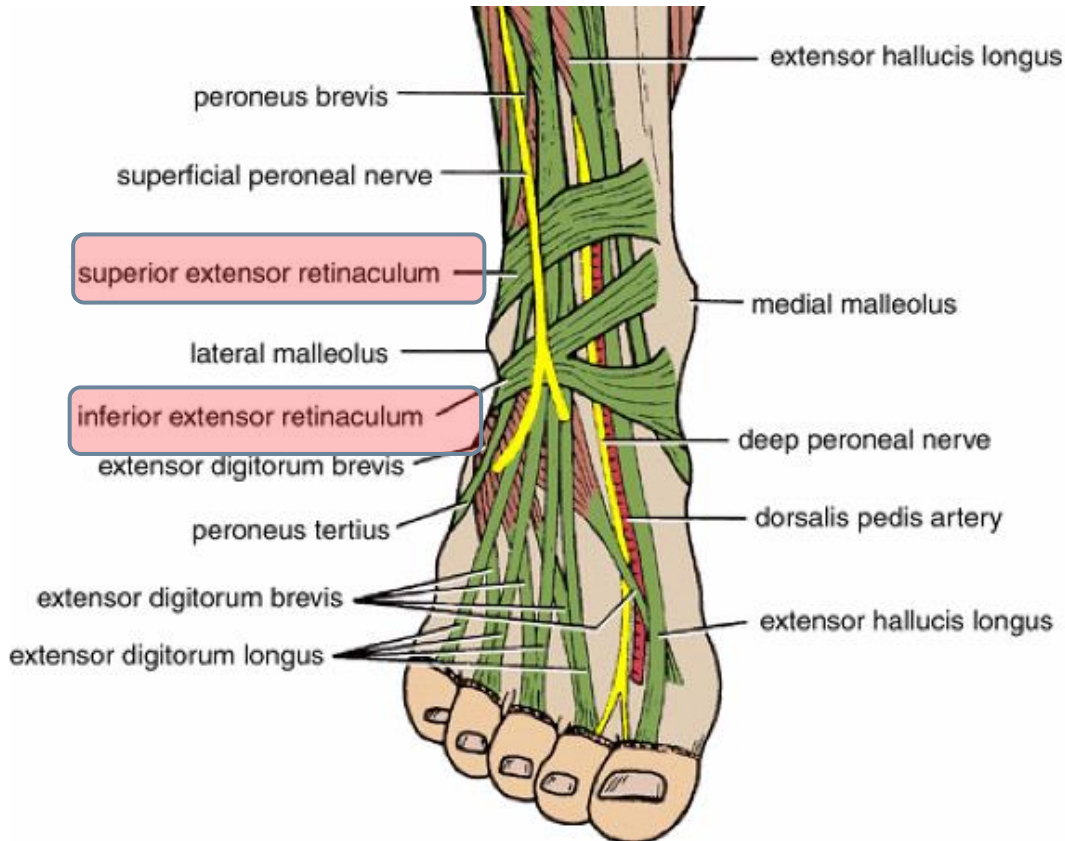
# Anterior Compartment



- Relatively small and most susceptible to compartment syndromes
- **Muscles**
  - *Tibialis anterior, extensor digitorum longus, extensor hallucis longus, and fibularis tertius*
- Are dorsiflexors of the ankle joint and Extensors (elevators) of the toes
- **Anterior tibial artery.**
- **Anterior tibial or (deep Peroneal) nerve.**

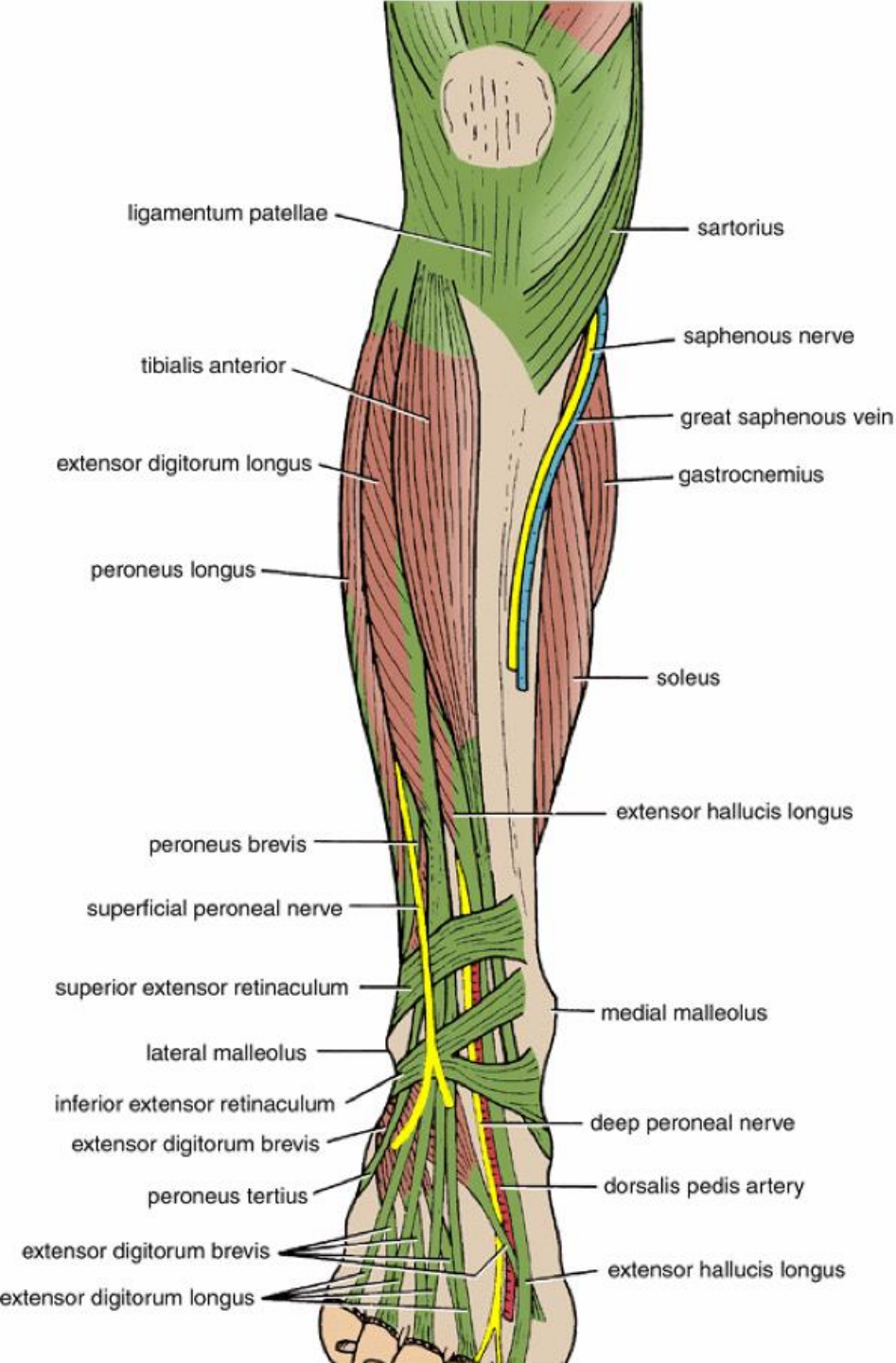


# Extensor Retinacula



- **A thickening band of deep fascia that keeps the long tendons around ankle joint in position.**
- **Superior Extensor retinaculum:**
  - **Attached to lower part of anterior borders of tibia & fibula above ankle.**
- **Inferior Extensor retinaculum:**
  - **Y-shaped band located anterior to the ankle.**

# Structures Passing Deep to Extensor Retinacula



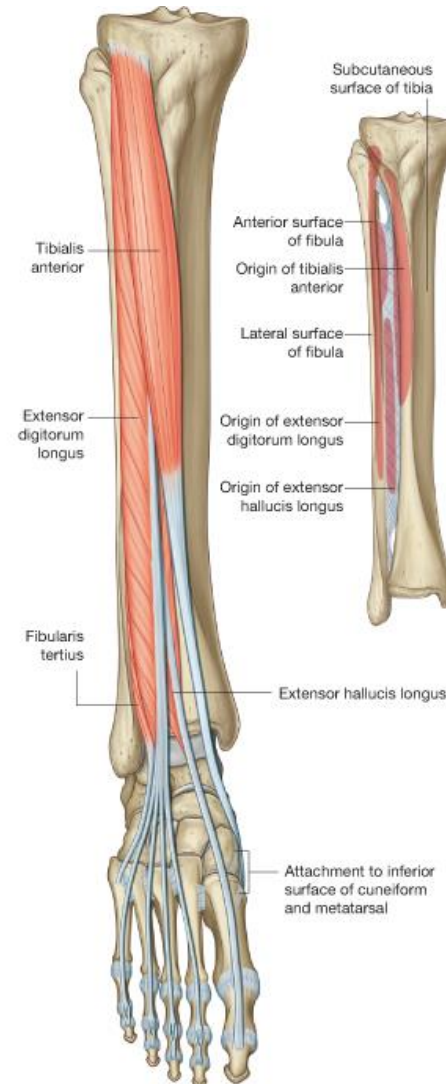
## □ From medial to lateral:

- Tibialis Anterior.
- Extensor hallucis longus.
- Anterior tibial artery, (ATA)
- **Venae comitans of (ATA).**
- (Deep peroneal nerve).
- Extensor digitorum longus.
- Peroneus tertius.

# Muscles of the Anterior Compartment

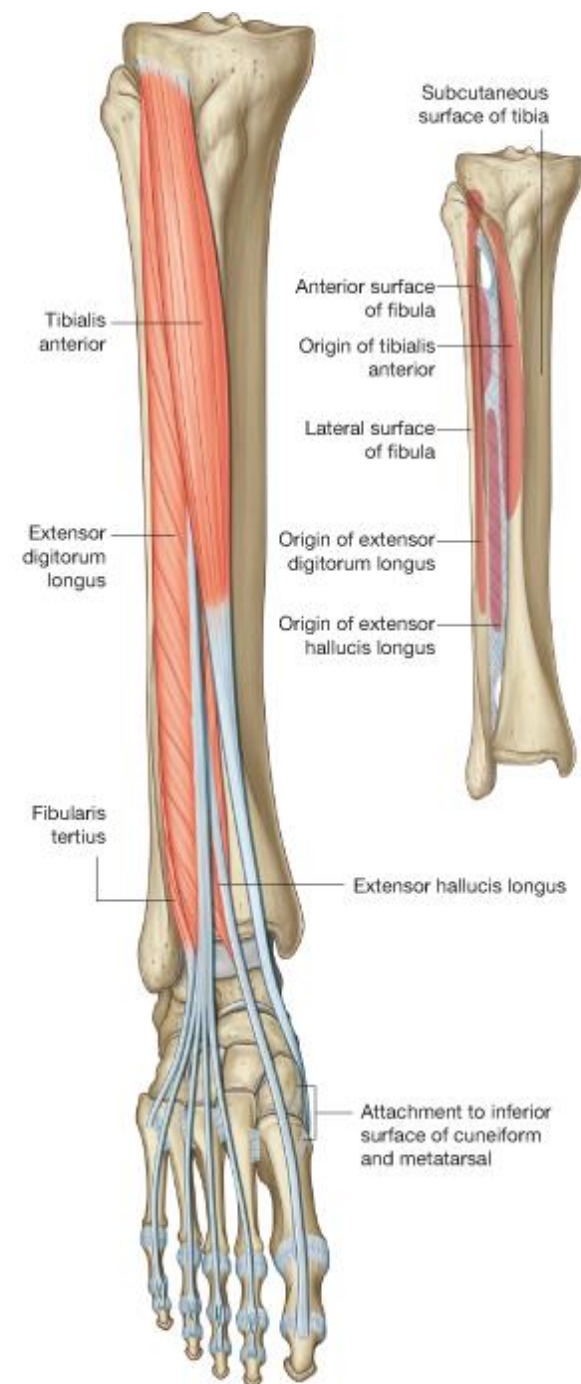
## □ Origin:

- All arise from the anterior surface of the shaft of the fibula and interosseous membrane, EXCEPT, tibialis anterior which arises from the lateral surface of the shaft of the tibia and the interosseous membrane.



# Cont.

- **Insertion and action**
  - **Tibialis anterior:**
    - Medial cuneiform and
    - Base of 1<sup>st</sup> metatarsal bone.
  - **Action:**
    - **Extends (dorsiflexion) of ankle.**
    - **Inverts the foot at subtalar joint.**
    - Supports the medial longitudinal arch of the foot.
  - **Extensor hallucis longus:**
    - Base of distal phalanx of big toe.
  - **Action:**
    - **Extends big toe,**
    - **Extends foot** at ankle joint;
    - **Inverts foot** at subtalar joints.



# Cont.

## □ Extensor digitorum

### longus:

- Extensor expansion of lateral 4 toes.

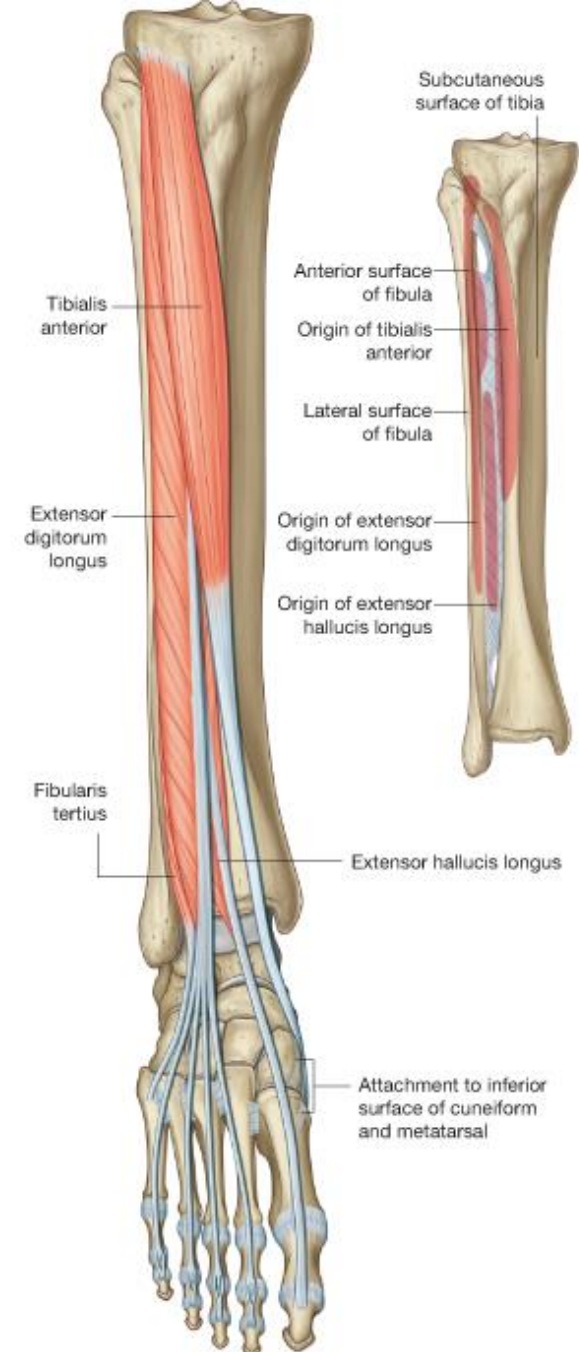
## □ Action:

- **Extends foot** at ankle joint.
- Extends the lateral 4 toes.

## □ Peroneus tertius:

## □ Action:

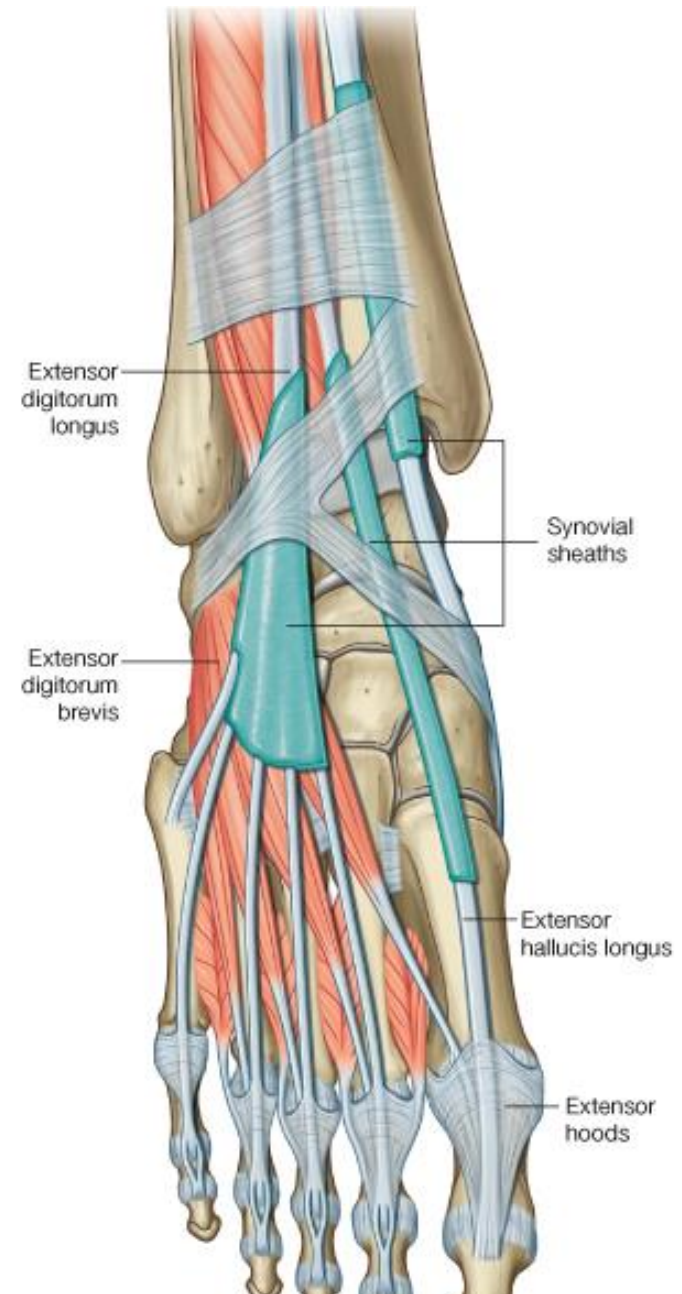
- **Extends** foot at ankle joint.
- Everts the foot at subtalar joint.





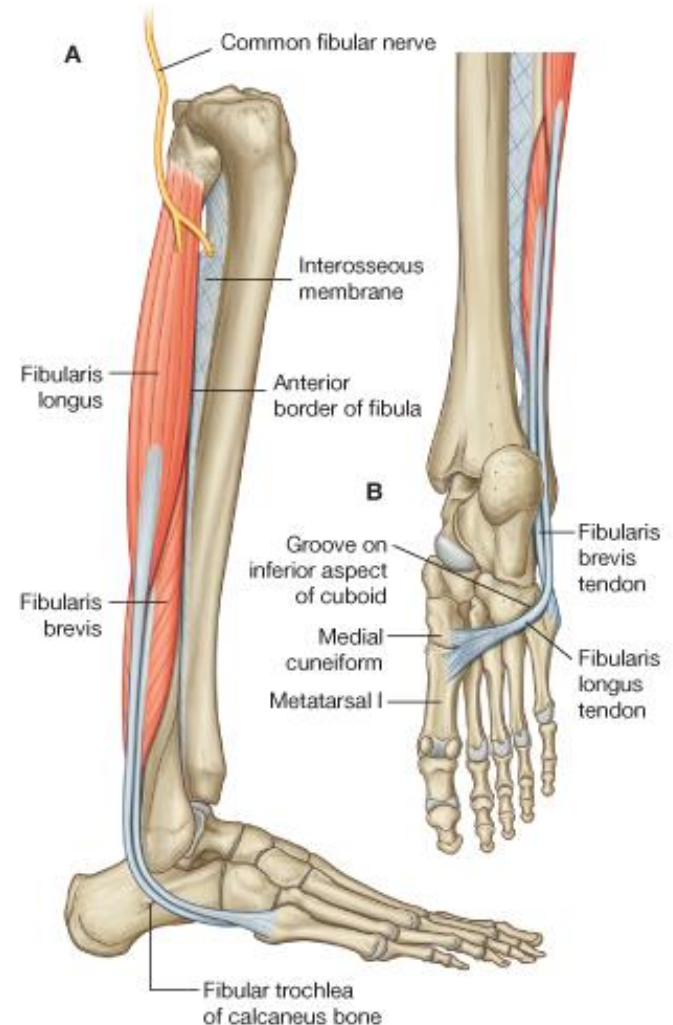
# Synovial Sheaths of Extensor Tendons on the Dorsum of Foot

- **Tibialis anterior and Extensor hallucis longus** (Both have their own synovial sheath).
- **Extensor digitorum longus & peroneus tertius**: have a common sheath, it extends to the level of **Base of 5<sup>th</sup> Metatarsal bone**.



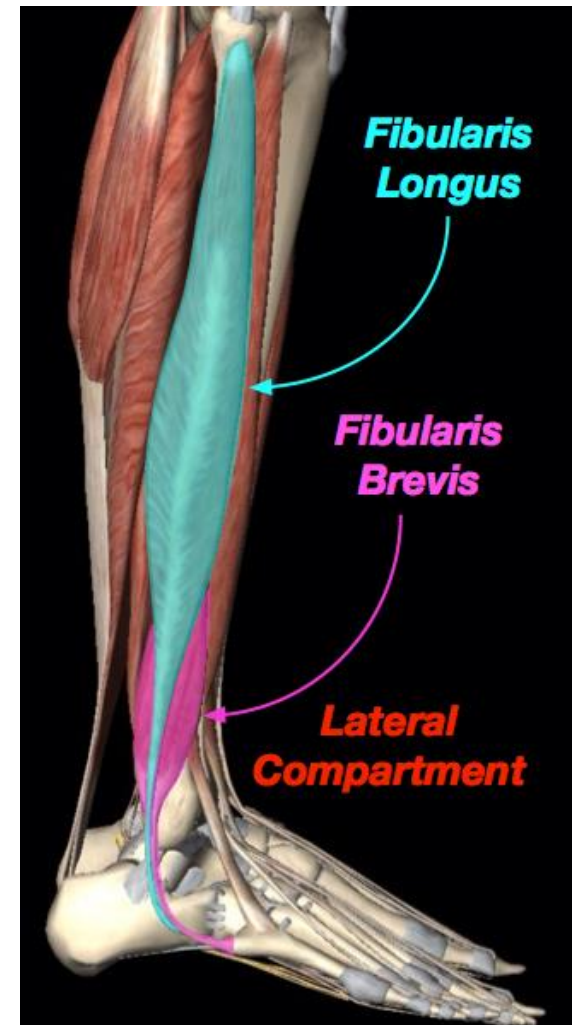
# Lateral Compartment

- **It contains 2 muscles:**
  - Peroneus longus (PL).
  - Peroneus brevis (Pb).
- **Origin:**
  - Both arise from the lateral surface of the shaft of the fibula.
- **Insertion:**
  - PL. Base of first metatarsal & medial cuneiform, (as **tibialis anterior**).
  - Pb. Base of fifth metatarsal bone.
- **Nerve supply:**
  - Both are supplied by superficial peroneal nerve.
- **Arterial supply**
  - The lateral compartment does not have an artery coursing through it



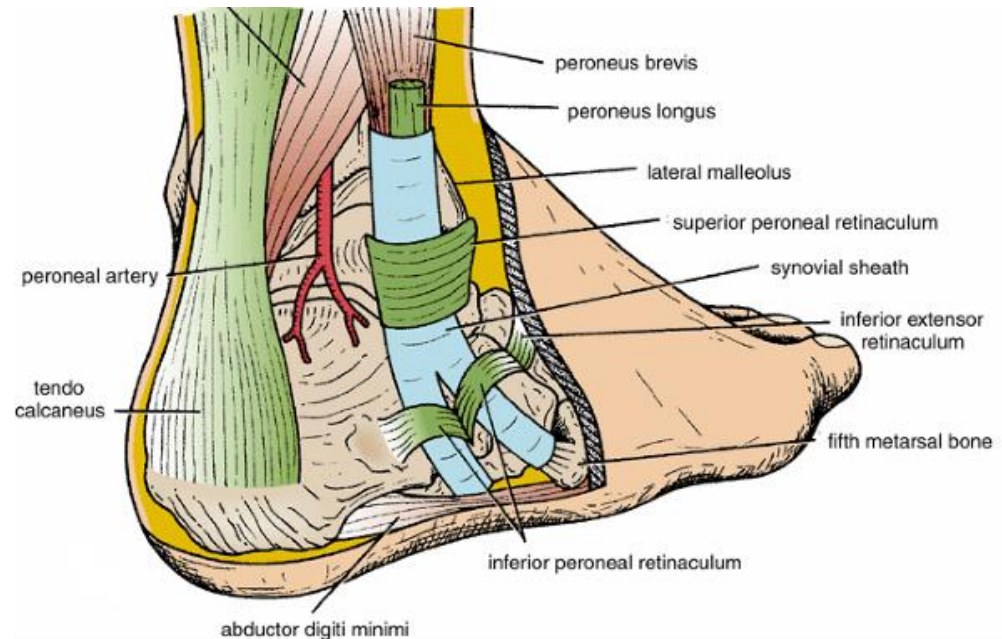
# Cont.

- **Action:**
- **Peroneus longus:**
  - Plantar flexes foot at ankle joint;
  - Everts foot at subtalar joints.
  - Supports the lateral longitudinal & Transverse arches.
- **Peroneus brevis:**
  - Plantar flexes foot at ankle joint.
  - Everts foot at subtalar joint.
  - Supports the lateral longitudinal arch of foot.

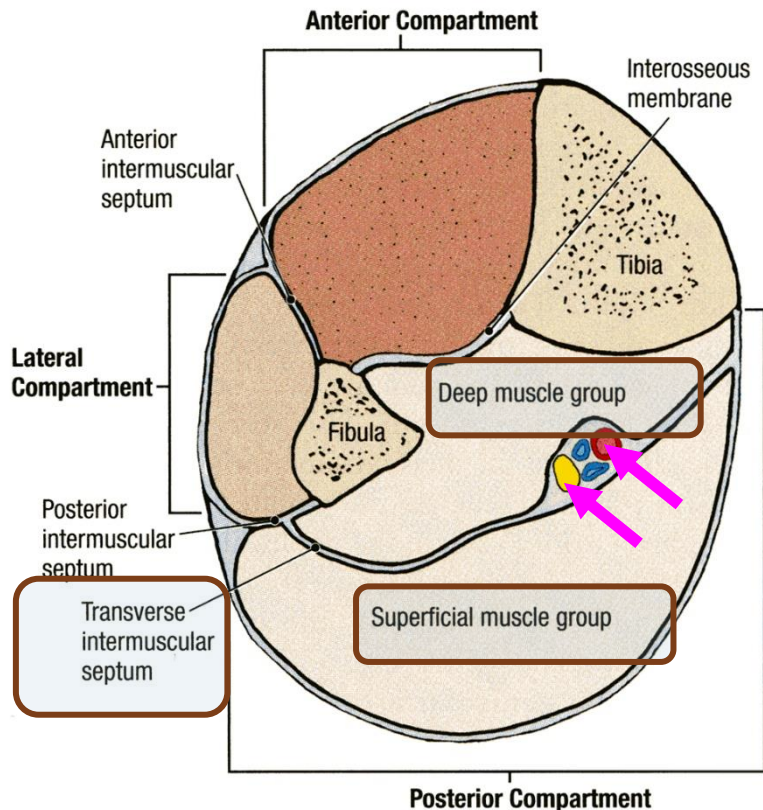


# Peroneal Retinacula

- **Superior peroneal retinaculum:**
- **Connects the lateral malleolus to calcaneum & holds the tendons of peroneus longus & brevis.**
- **Inferior peroneal retinaculum.**
- **Synovial Sheaths of Peroneal Longus & Brevis**
- **Tendons of the 2 peronei are surrounded by a single common tubular synovial sheath deep to superior peroneal retinaculum.**
- **But deep to inferior peroneal retinaculum, each have its separate sheaths.**



# Contents of the posterior fascial compartment of the leg

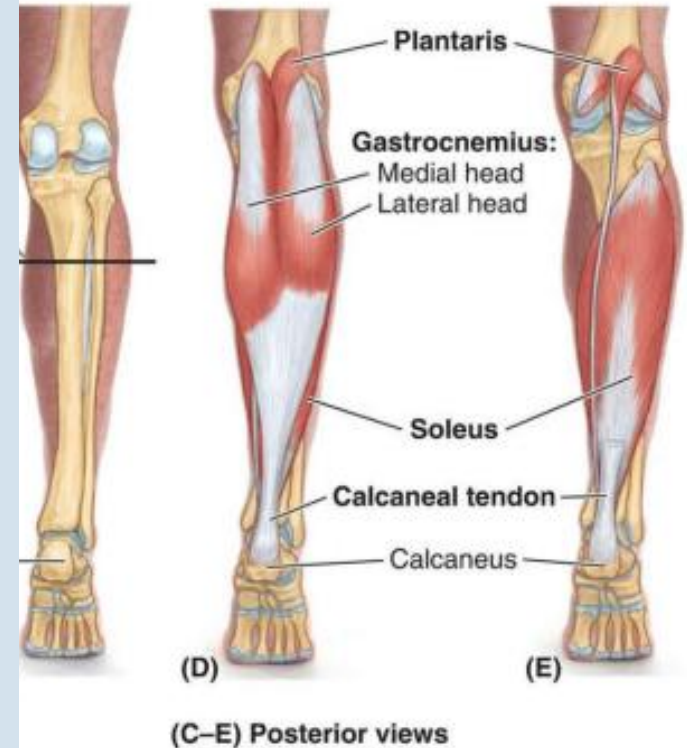


- The transverse intermuscular septum of the leg is a septum divides the muscles of the posterior compartment into superficial and **tightly confined deep groups**.
- The tibial nerve and posterior tibial and fibular vessels supply both parts of the posterior compartment **but run in the deep sub compartment deep (anterior) to the transverse intermuscular septum**.
- **Muscles of the posterior compartment produce plantarflexion at the ankle, inversion at the subtalar and transverse tarsal joints, and flexion of the toes.**
- **Plantarflexion is a powerful movement (four times stronger than dorsiflexion)**
- **Contents:**
  - **Superficial group** of muscles;
  - **Deep group** of muscles
  - **Posterior tibial artery**
  - **Tibial nerve**

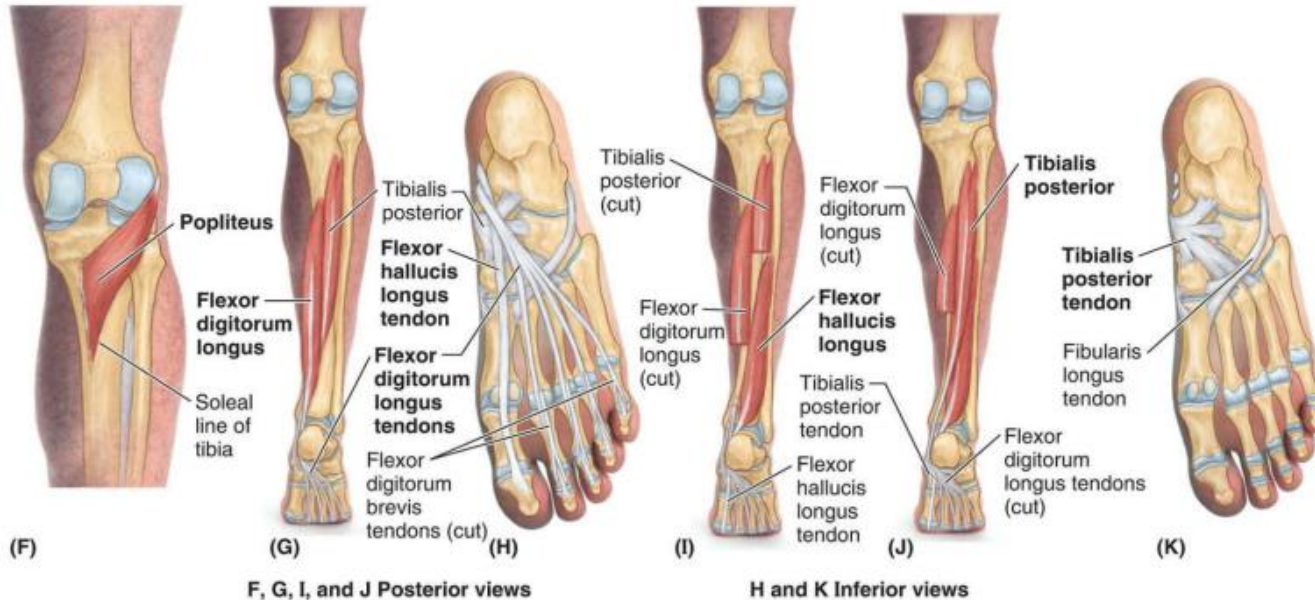


# Superficial (calf) muscles of posterior compartment of leg

- Forming prominence of “calf” of posterior leg) includes the **gastrocnemius, soleus, and plantaris.**
- The gastrocnemius and soleus share a common tendon, the **calcaneal tendon (15 cm)**, which attaches to the calcaneus.
- Collectively, these two muscles make up the three-headed **triceps surae.**
- **“You stroll with the soleus but win the long jump with the gastrocnemius.”??**
- This powerful muscular mass tugs on the lever provided by the calcaneal tuberosity, elevating the heel and thus depressing the forefoot, **generating as much as 93% of the plantarflexion force.**
- an antigravity muscle and “workhorse” of plantarflexion ????



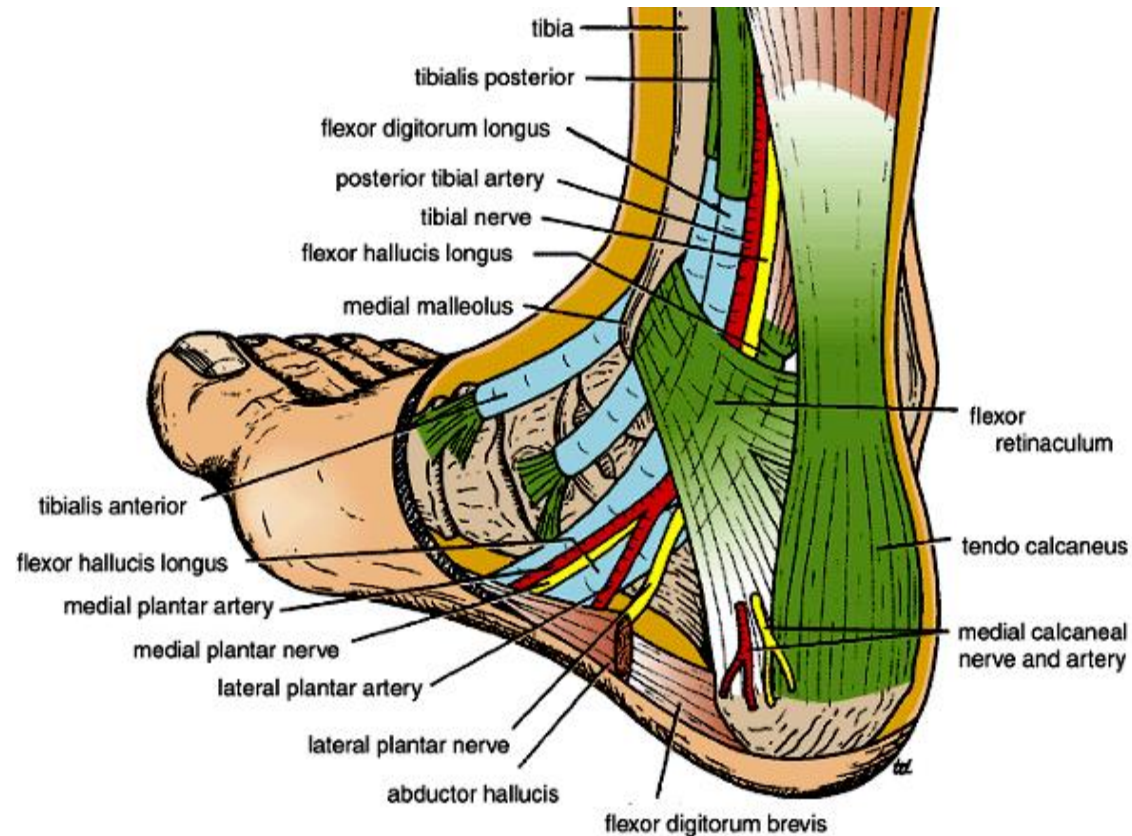
# Deep group



- There are four muscles in the deep posterior compartment of leg *popliteus, flexor hallucis longus, flexor digitorum longus, and tibialis posterior*.
- The popliteus muscle acts on the knee whereas the other three muscles act mainly on the foot.
- the “nontriceps” plantar flexors collectively produce only about 7% of the total force of plantarflexion, and in this, *the fibularis longus and brevis are most significant*.

# Flexor Retinaculum

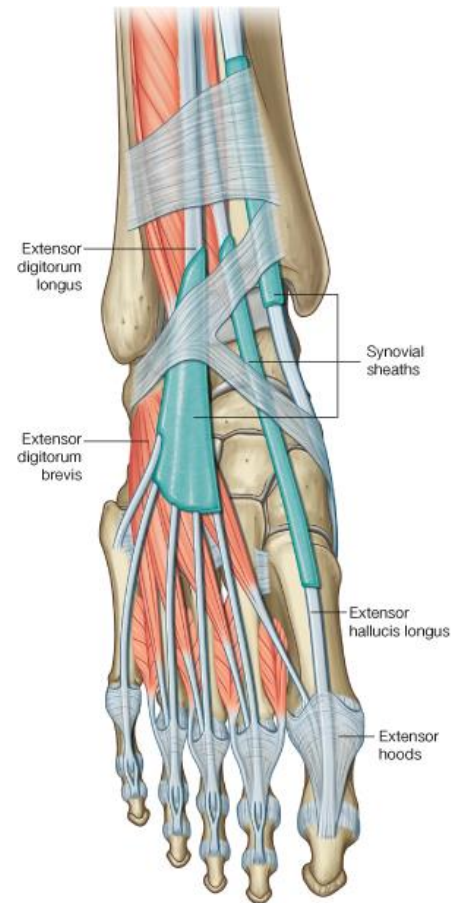
- Extends from back of medial malleolus of tibia to medial side of calcaneum.
- Structures that pass under????



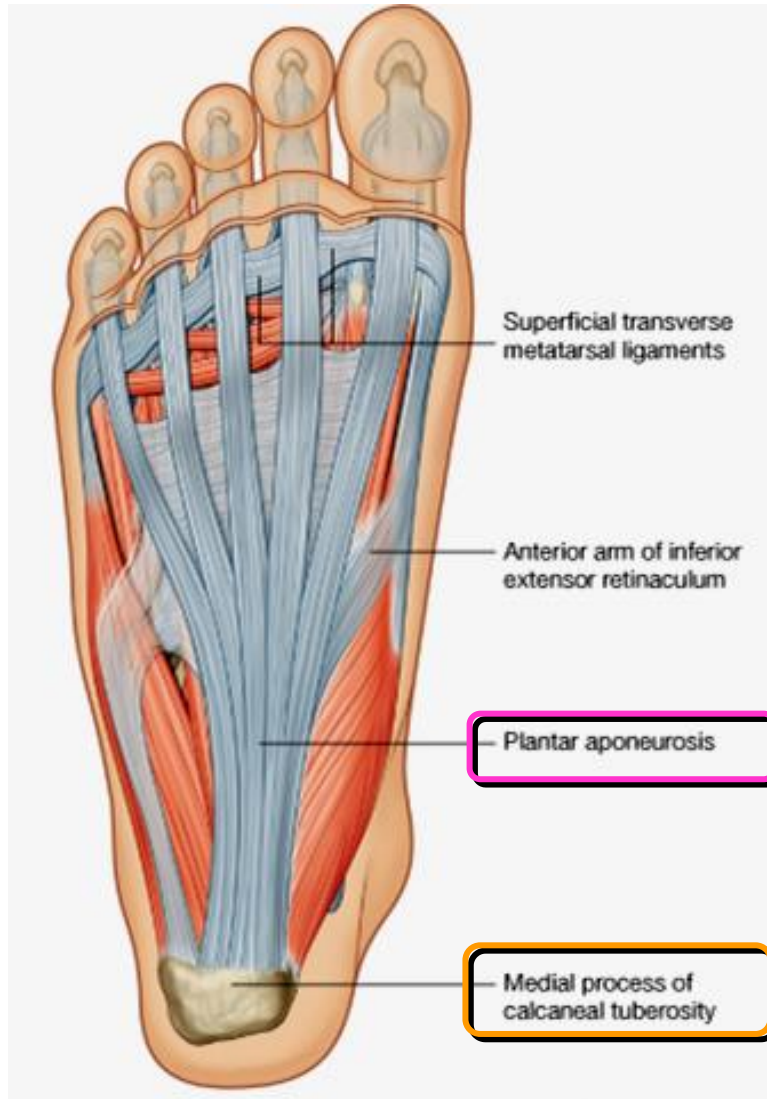
# Intrinsic Muscles of the Foot

## Intrinsic Muscles of Dorsum of the Foot:

- ***Extensor digitorum brevis***
- ***Extensor hallucis brevis***



# Deep Fascia

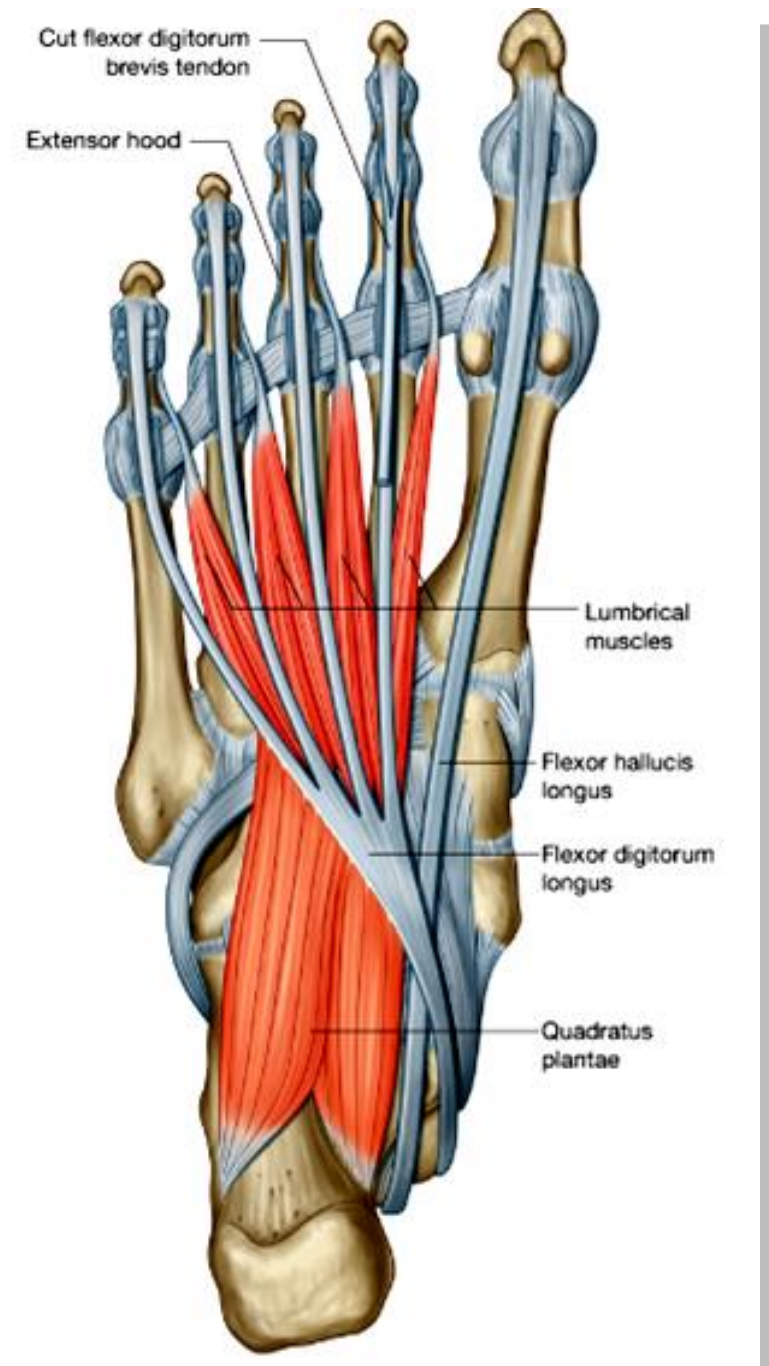
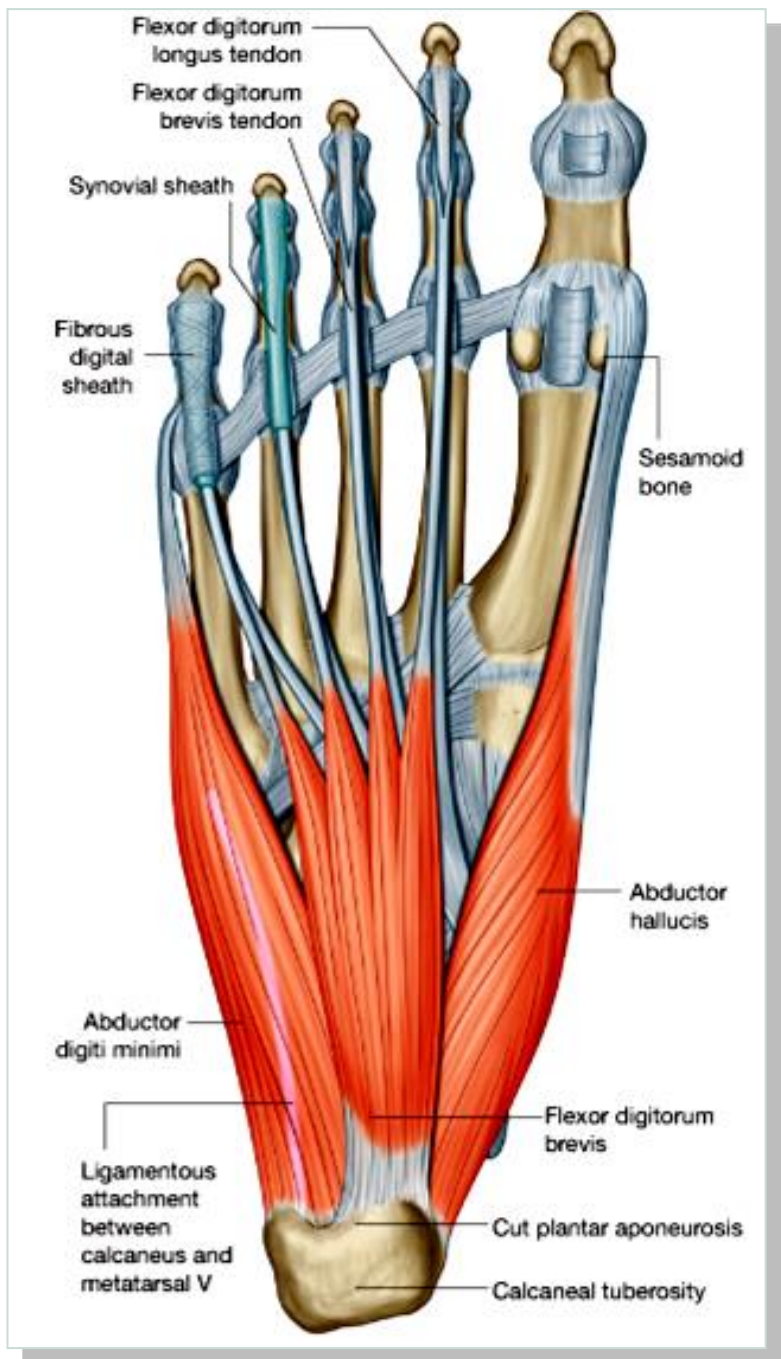


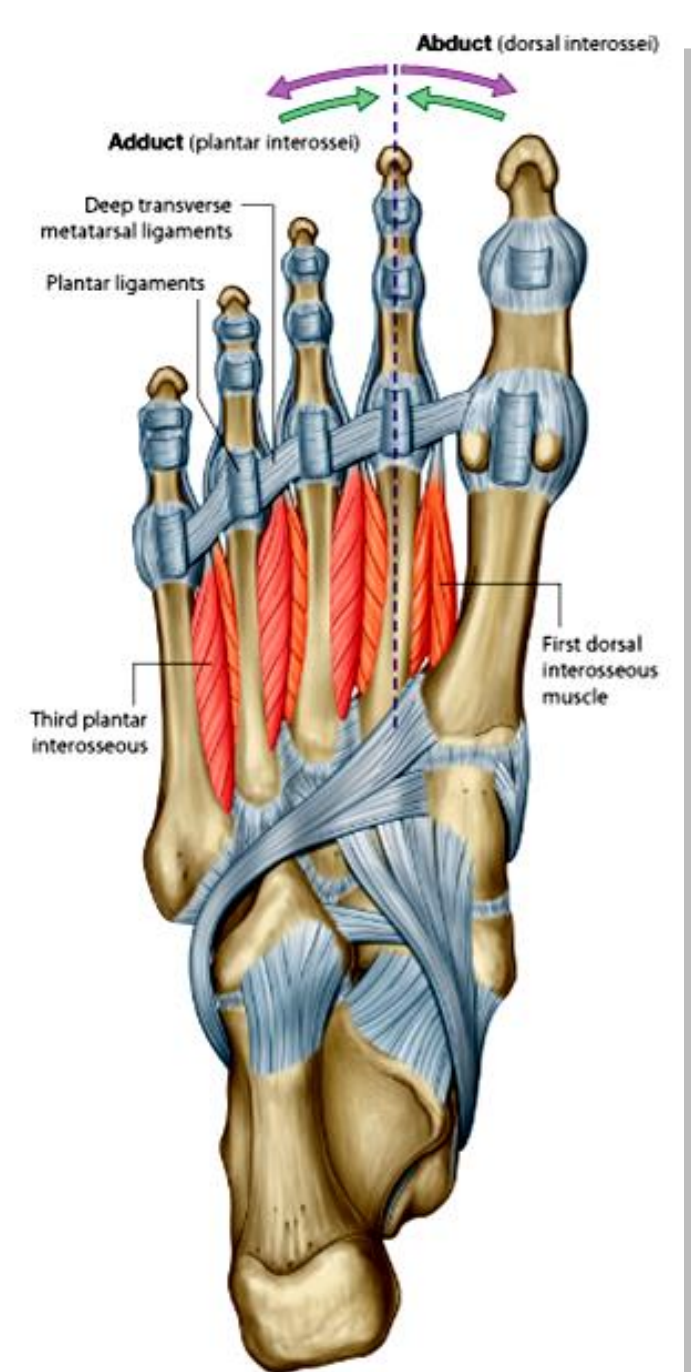
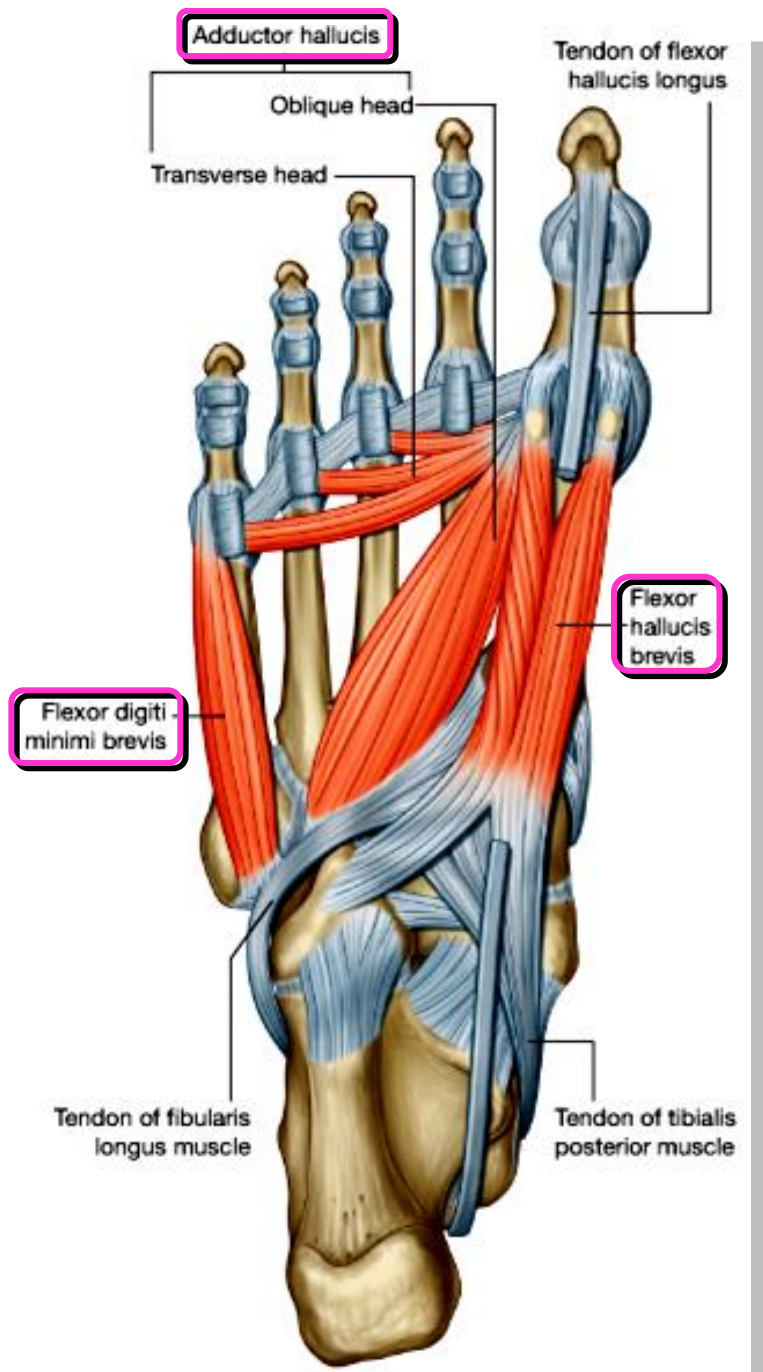
- The **plantar aponeurosis** is a triangular thickening of the deep fascia that protects the underlying nerves, blood vessels, and muscles.
- Its **apex** is attached to the **medial and lateral tubercles** of the **calcaneum**.
- The **base** of the aponeurosis divides into **five slips** that pass into the **toes**.



# Muscles of the Sole of the Foot

- The muscles of the sole are conveniently described in **four layers** from superficial to deep.
- Unlike the small muscles of the hand, the **sole muscles have few delicate functions** and are chiefly concerned with **supporting the arches of the foot**.
- Although their names would suggest control of individual toes, this function is rarely used in most people







I thank u